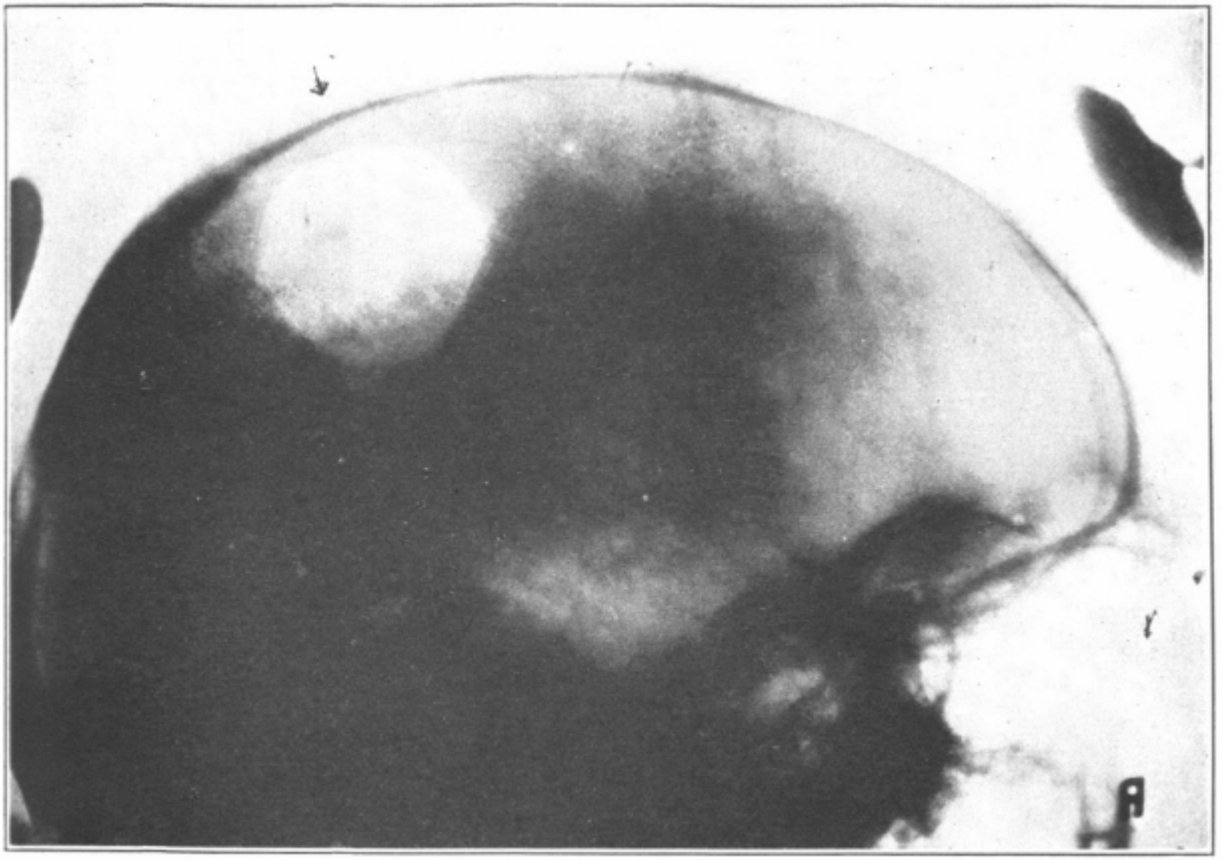

FIG. 37.—Large parietal defect. Roentgenogram before cranioplasty