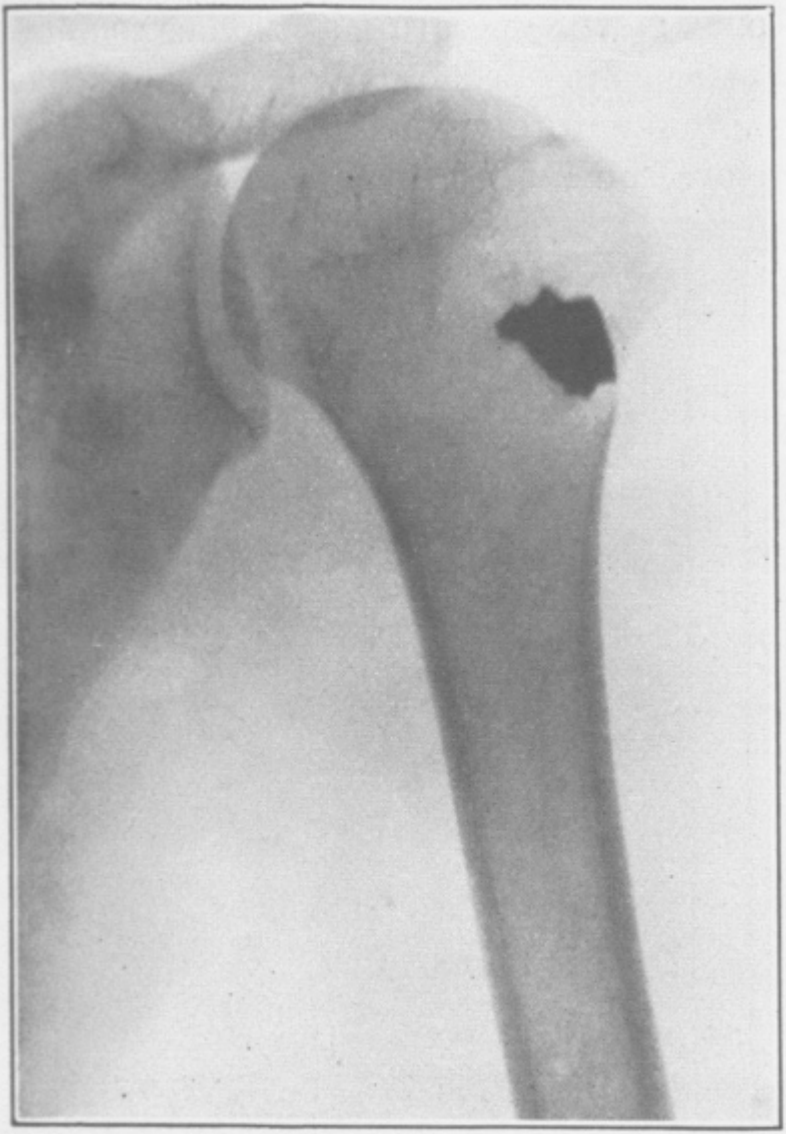

FIG. 44.—Fissure fracture of the greater tuberosity of the humerus by shell fragment, which is shown lodged