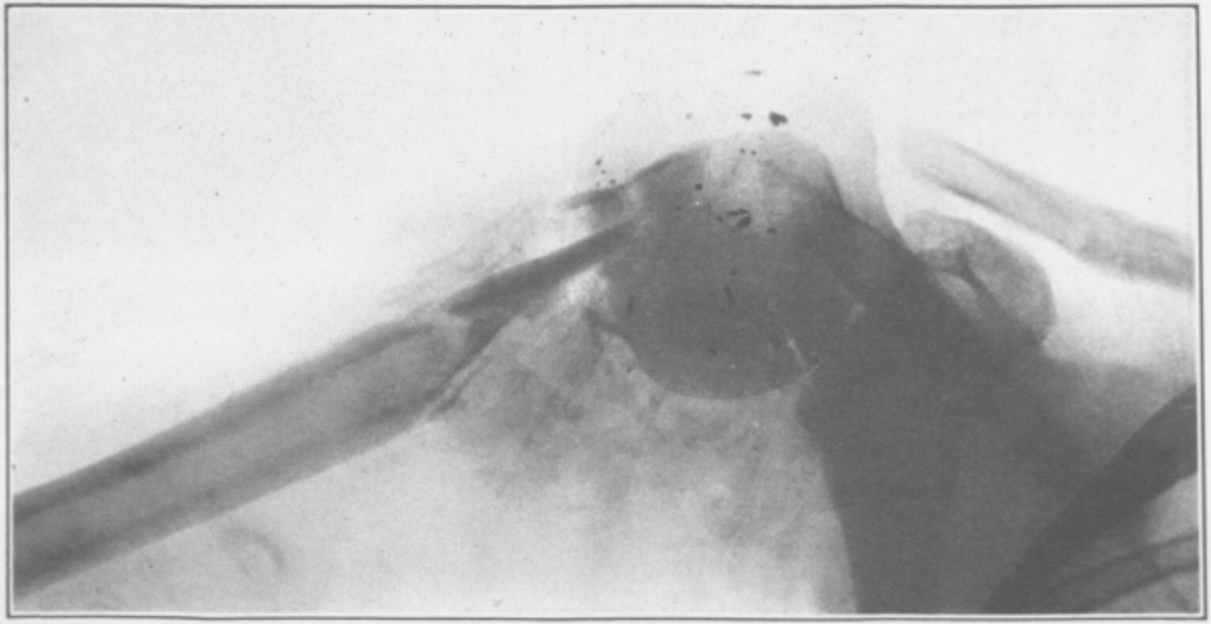

FIG. 46.—Fracture of upper end of diaphysis of humerus by rifle missile, with much loss of bone. Fragments of the missile are shown dispersed in the tissue about the head of the humerus