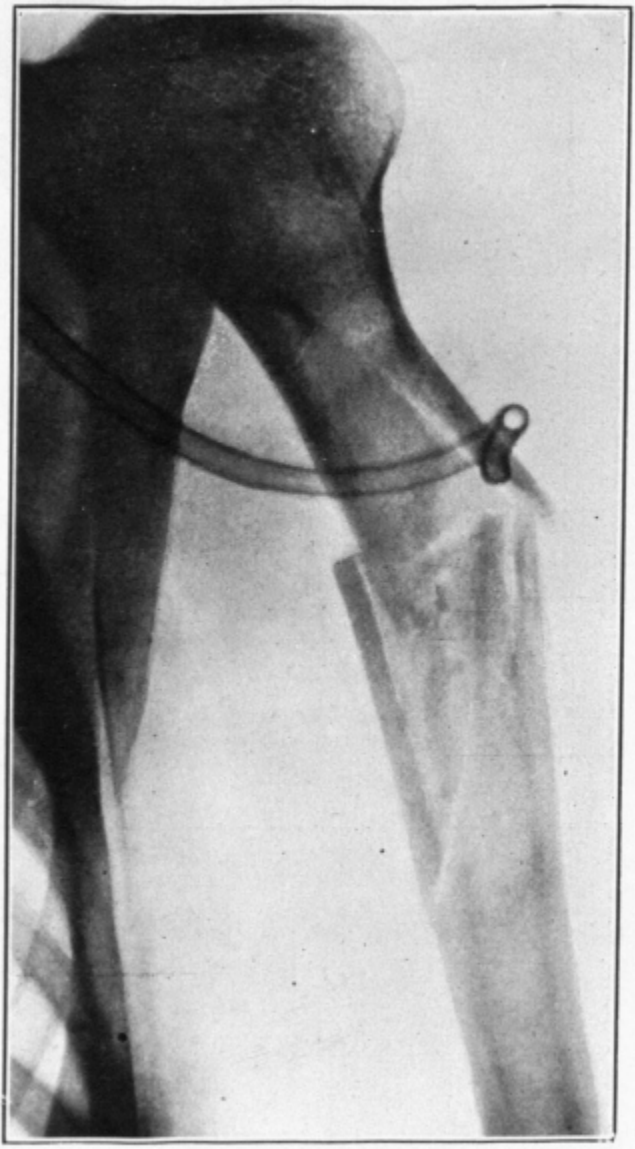

FIG. 47.—Wound of the upper portion of the shaft of the humerus. The fragments of bone are large and but little separated, though there is considerable displacement