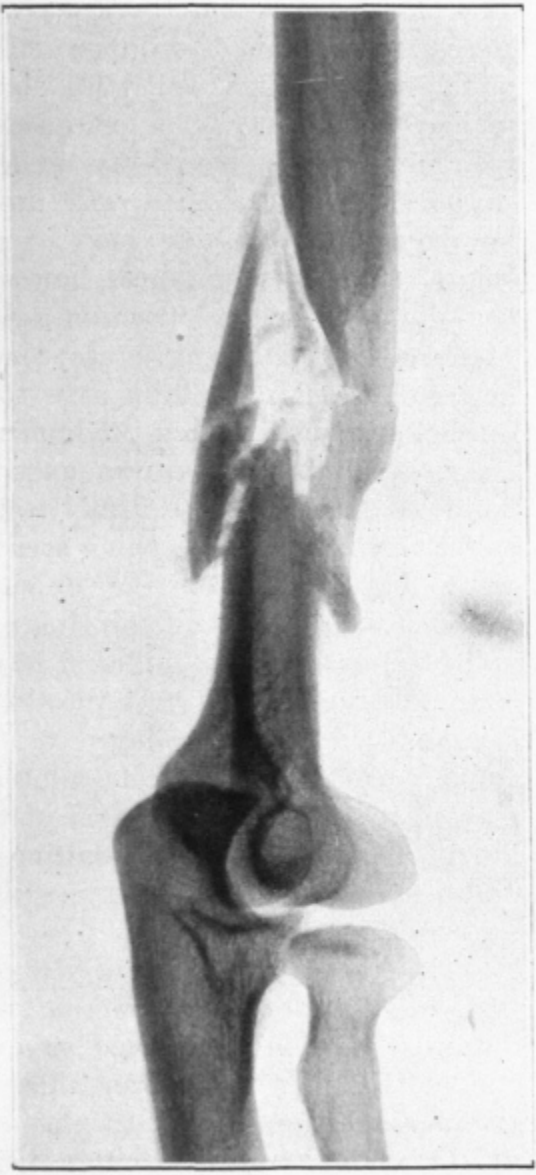

FIG. 49.—Wound of diaphysis of humerus by rifle missile, with wide separation of bone fragments