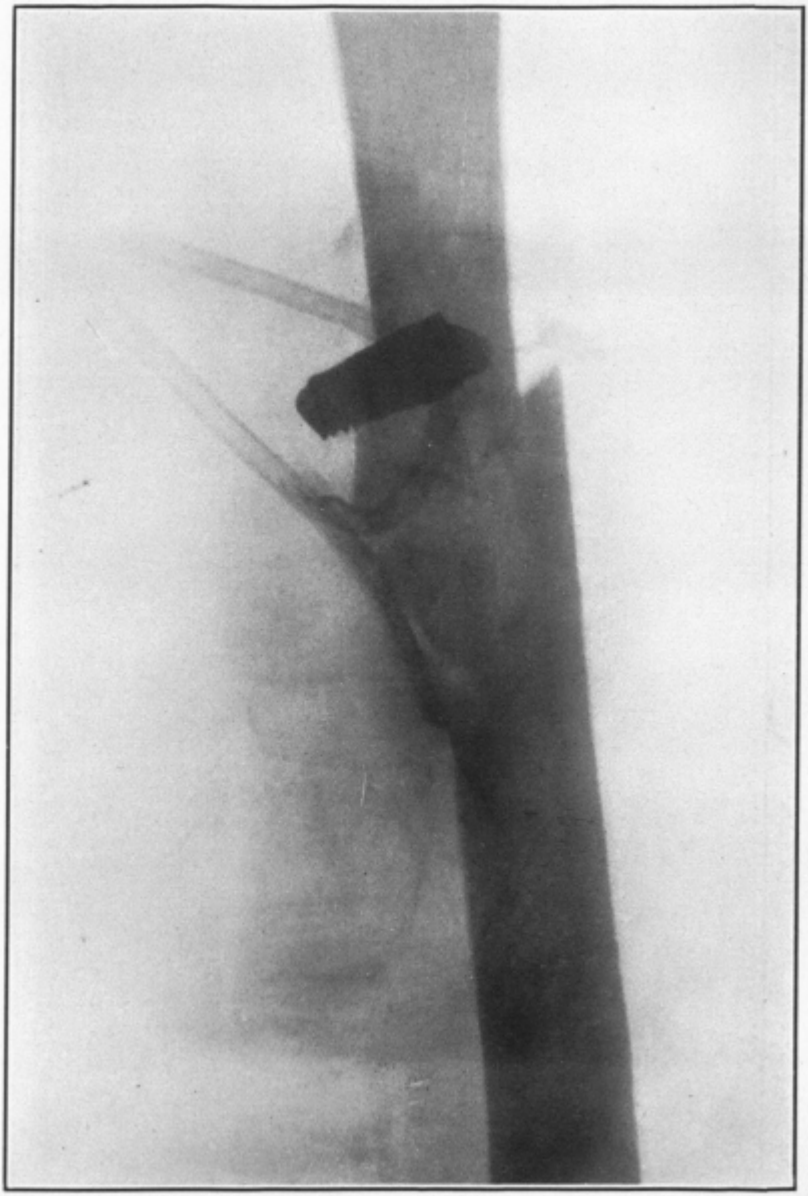

Fig. 55.—Fracture of shaft of femur by shell fragment, shown lodged. There is some displacement but little or no comminution