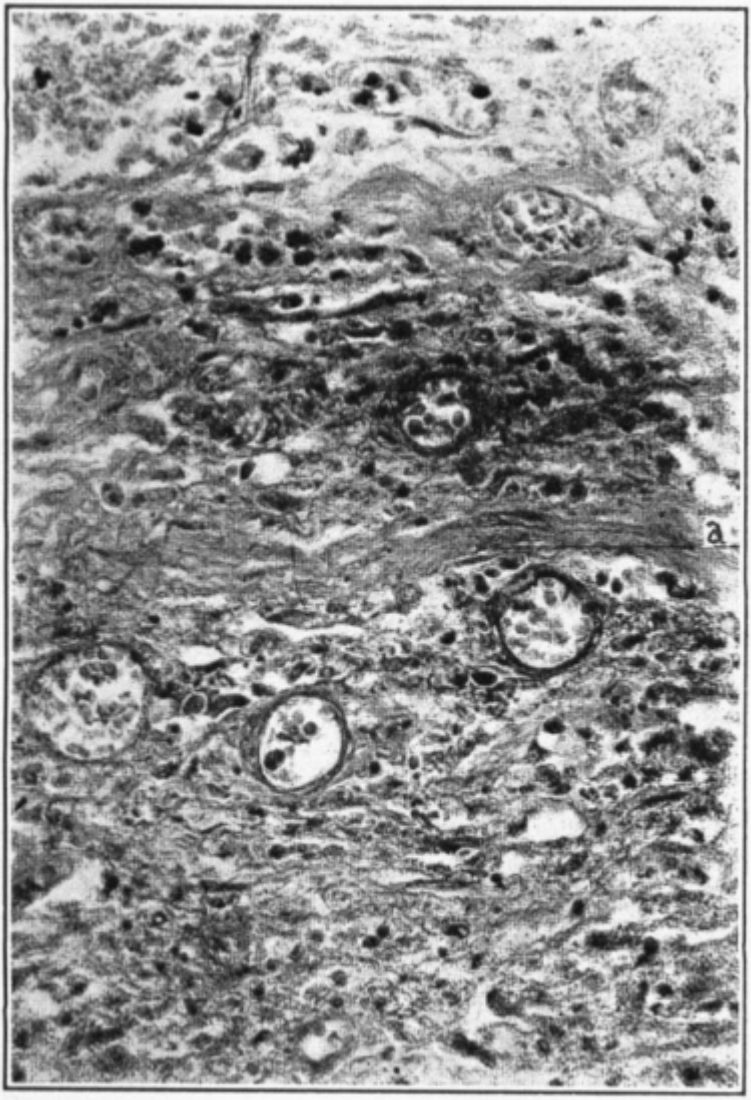

FIG. 58.—Section from an abscess wall similar in type to that shown in Figure 56 but of longer duration. *a*, Small band of adult fibrous tissue. ×325