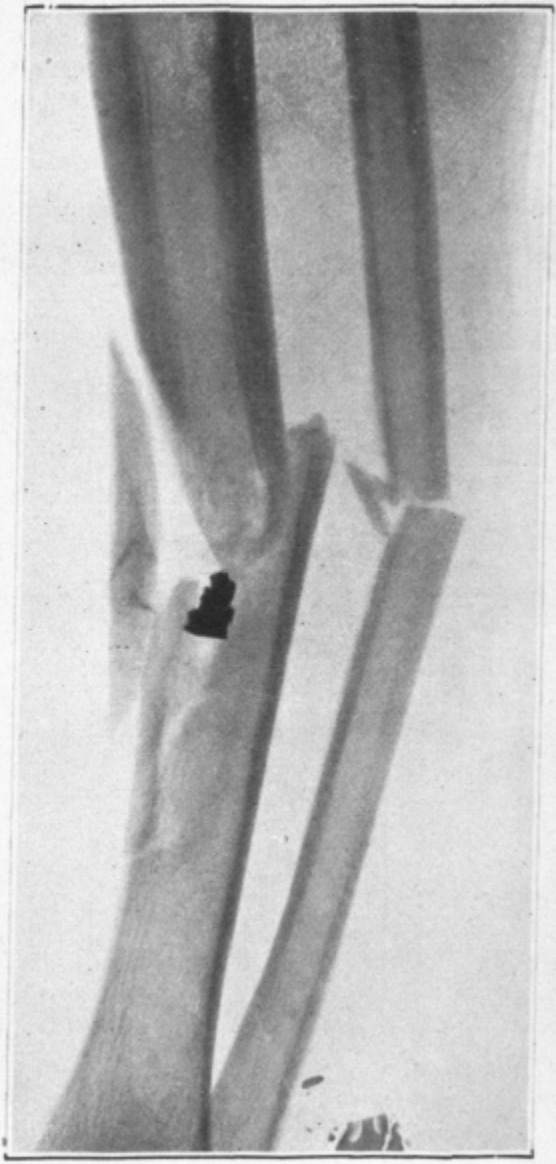

FIG. 66.—Fracture of middle of diaphysis of tibia, caused by shell fragment. Indirect fracture of fibula. Shell fragment shown lodged