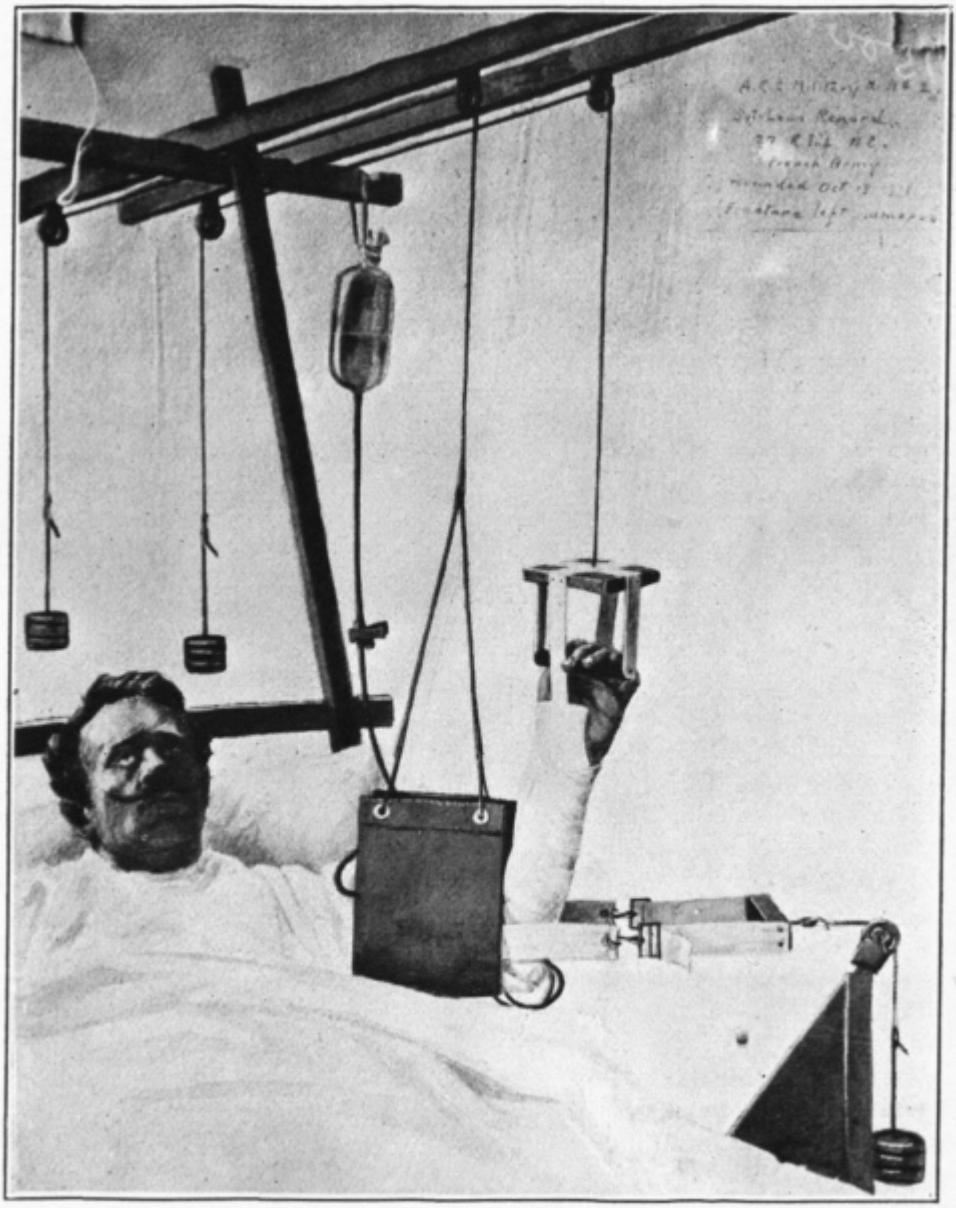

FIG. 71.—Treatment of fractured humerus