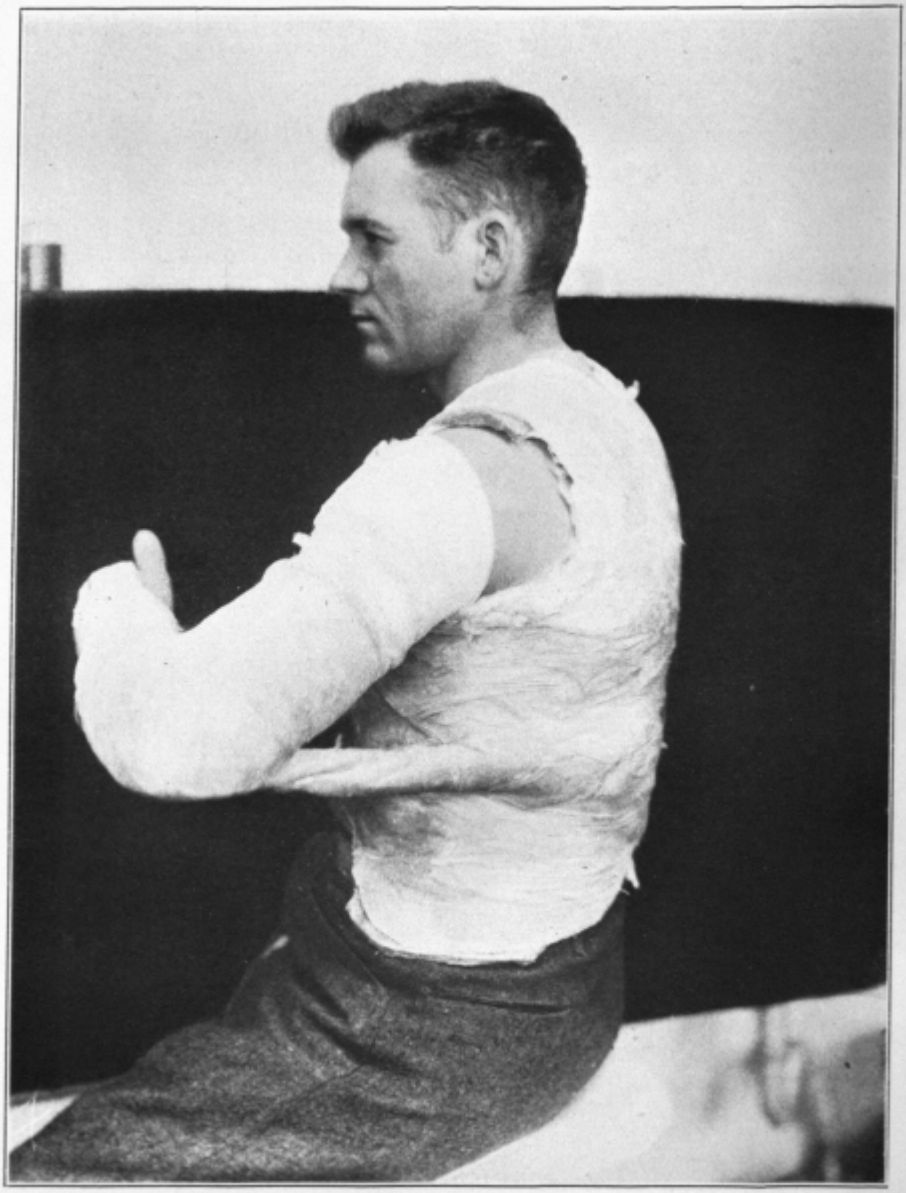

Fig. 73.—Compound, comminuted fracture involving shoulder joint. Cast in position of abduction; hand semi-supinated. Note windows cut for dressing and pelvic support