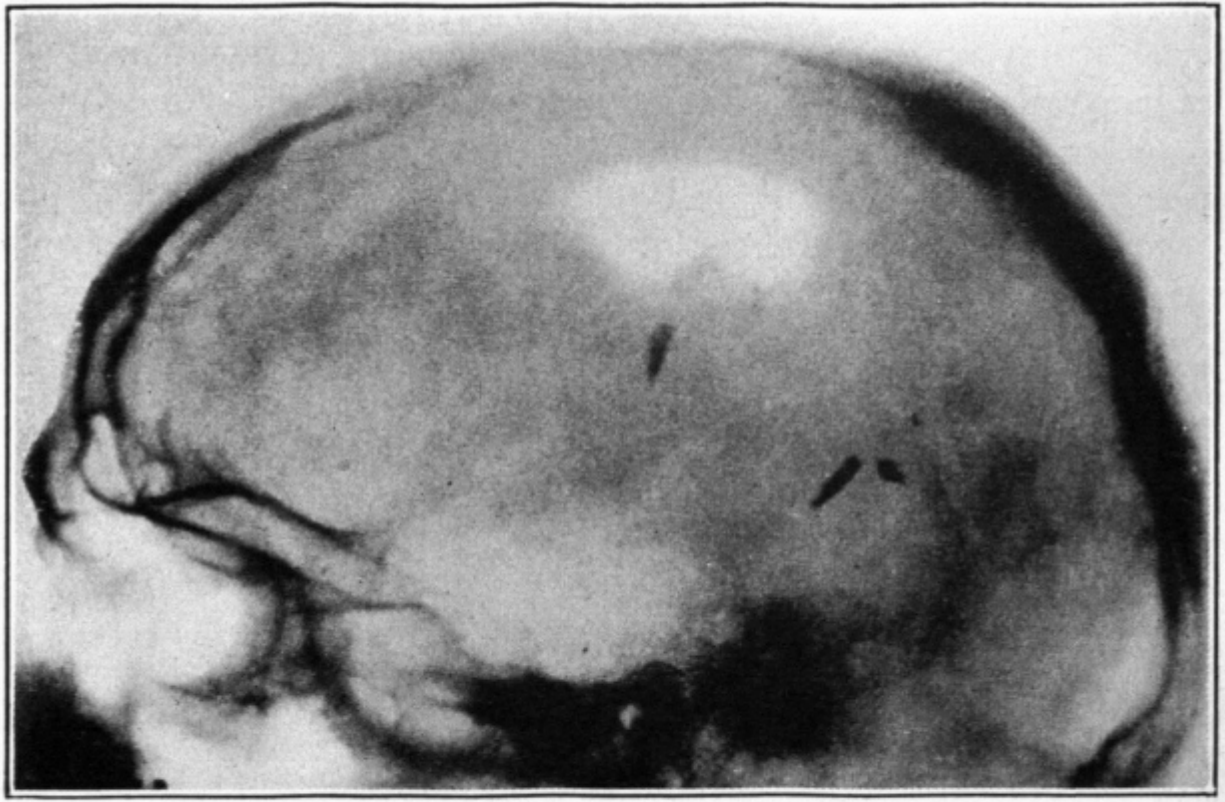

FIG. 78.—Three metallic fragments at a distance from the defect; two bone fragments within the margin of the defect