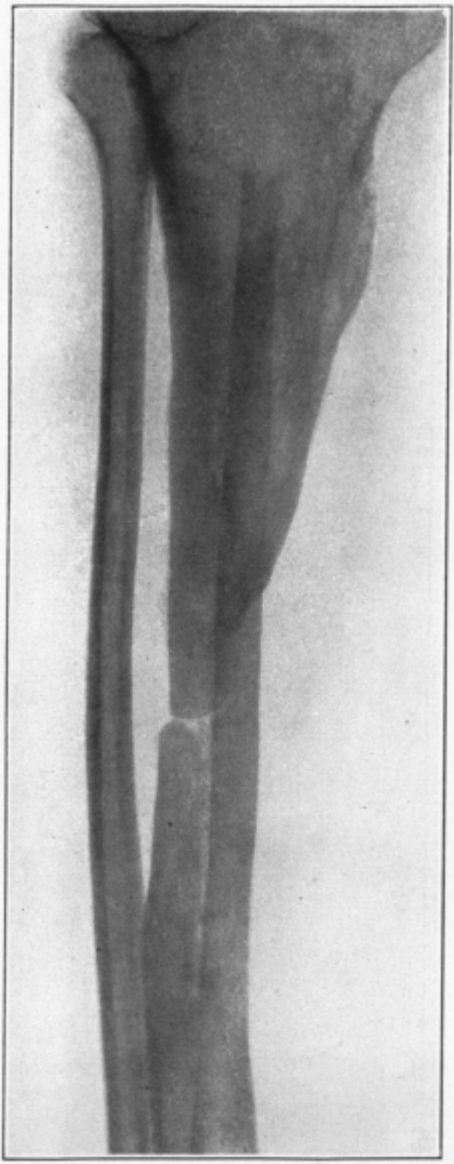

FIG. 92.—Case 3. Roentgenogram, December 10, 1921, showing bone being thrown across between graft and old eburnated bone