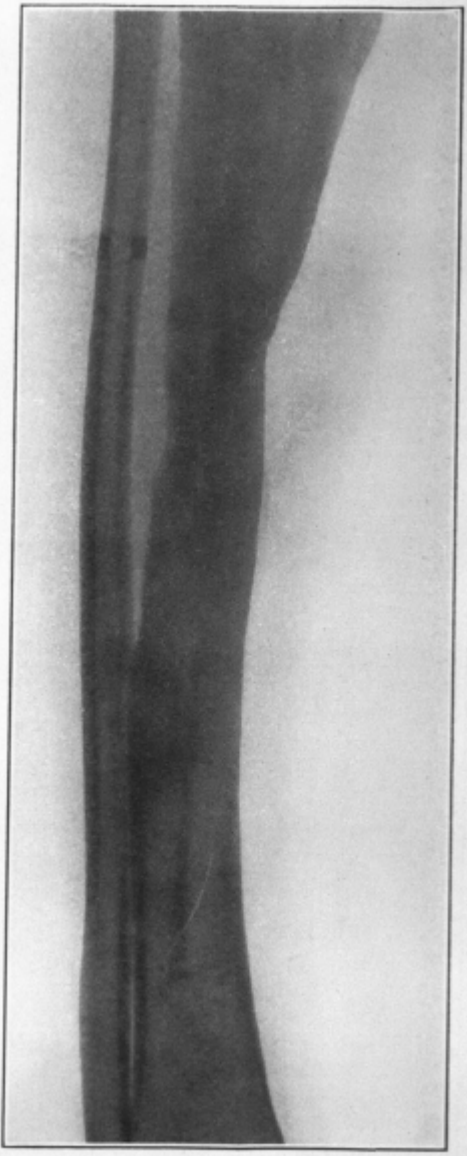

FIG. 93.—Case 3. Roentgenogram, July 28, 1922, 14 months after operation. There is excellent bony union