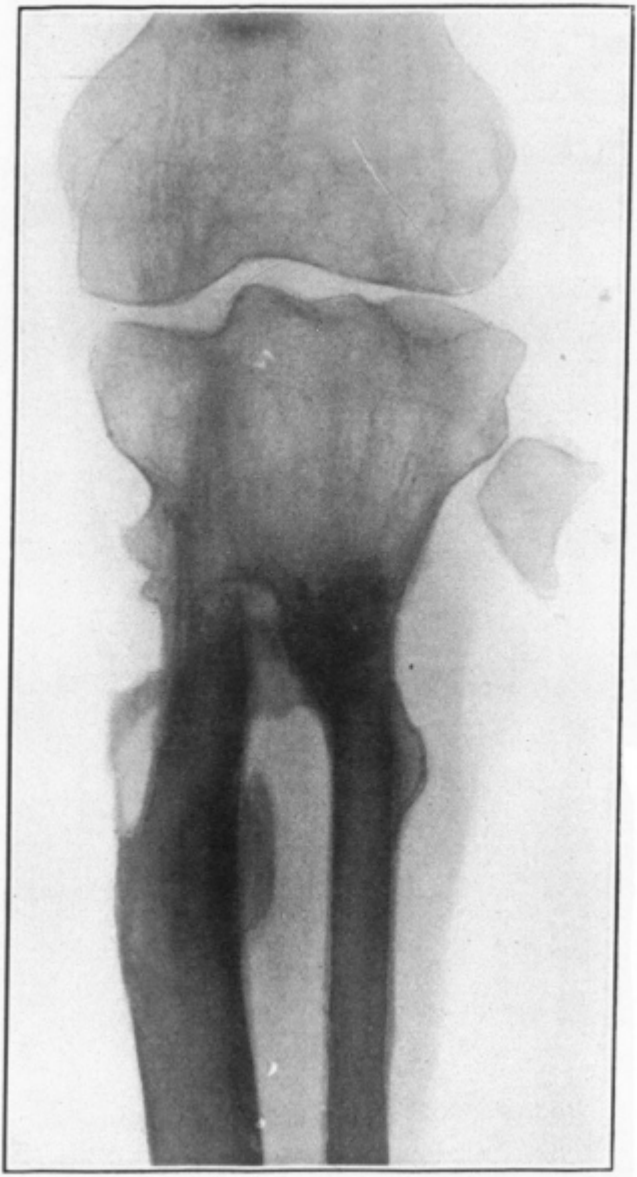

FIG. 95.—Case 4. Solid bony union January 17, 1922, five months after graft