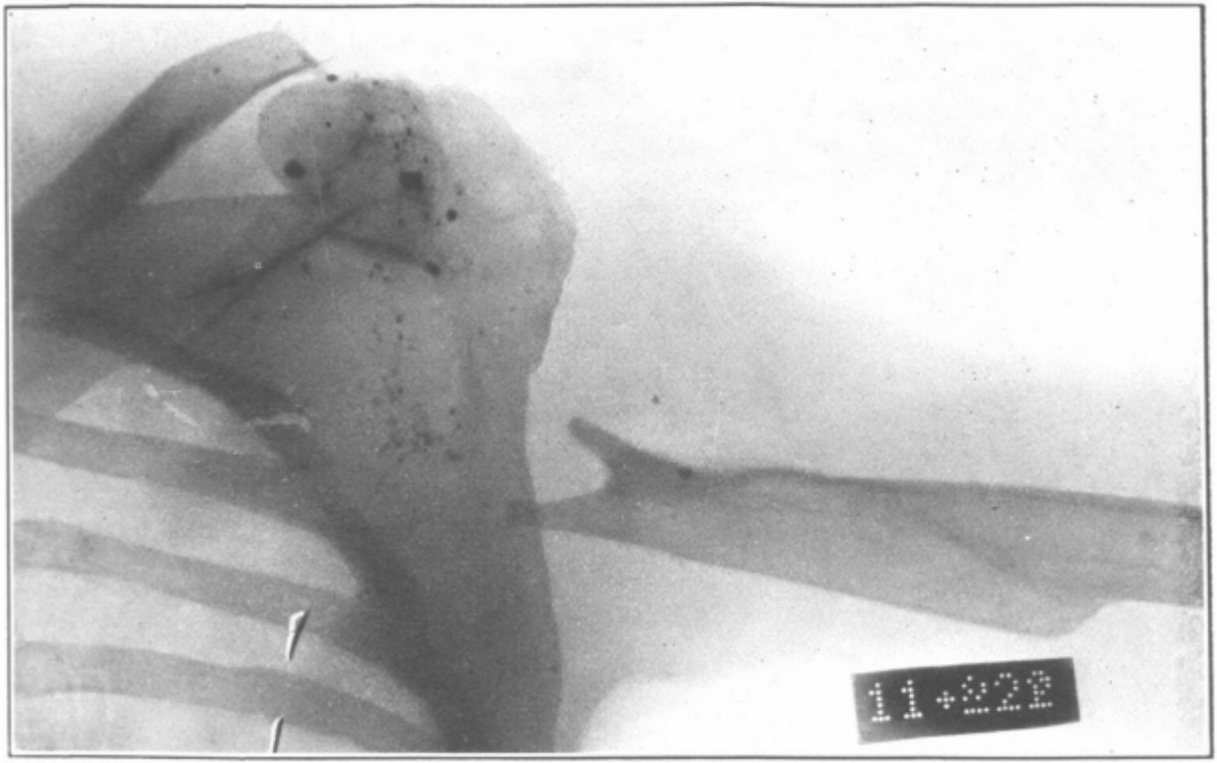

FIG. 102.—Case 7. Roentgenogram before operation, showing loss of substance