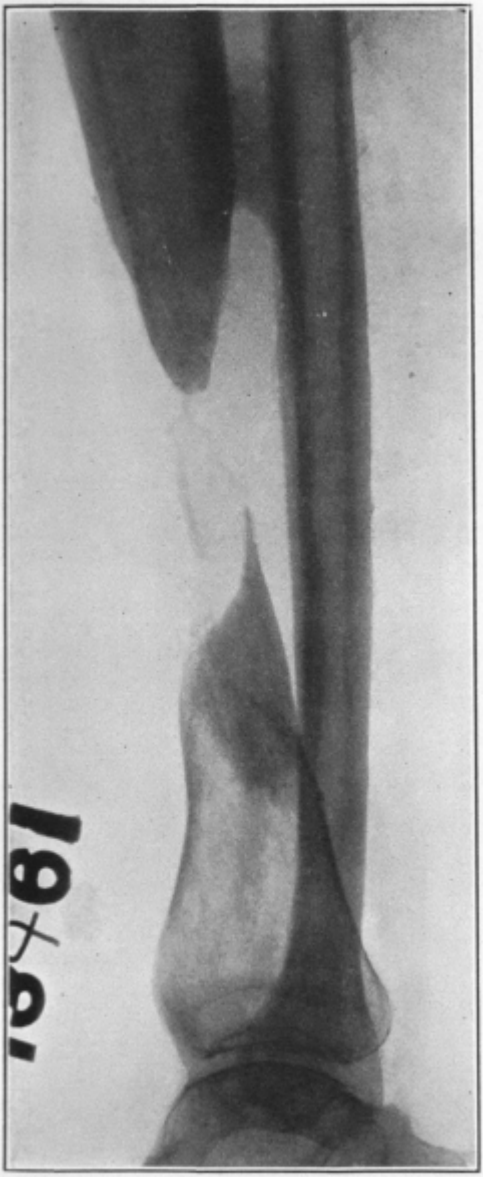

Fig. 115.—Case 11. Roentgenogram showing loss of substance