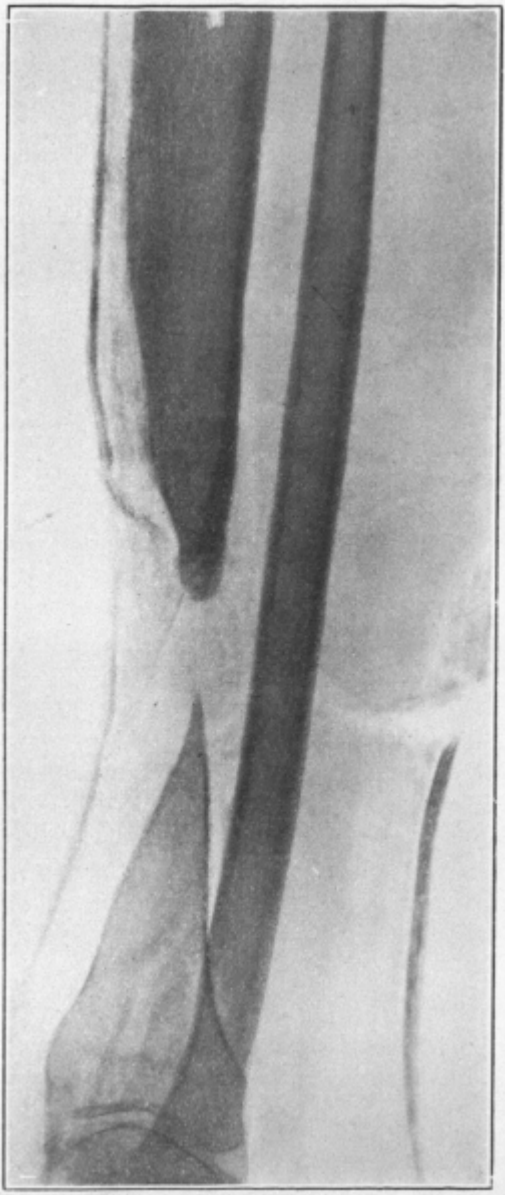

Fig. 117.—Case 12. Roentgenogram showing loss of substance