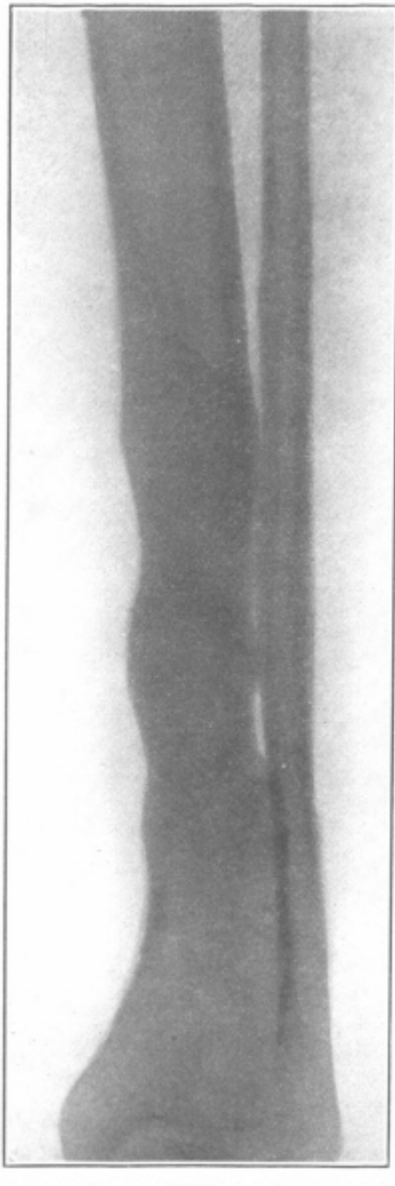

FIG. 121.—Case 12. Solid bony union 19 months after fracture