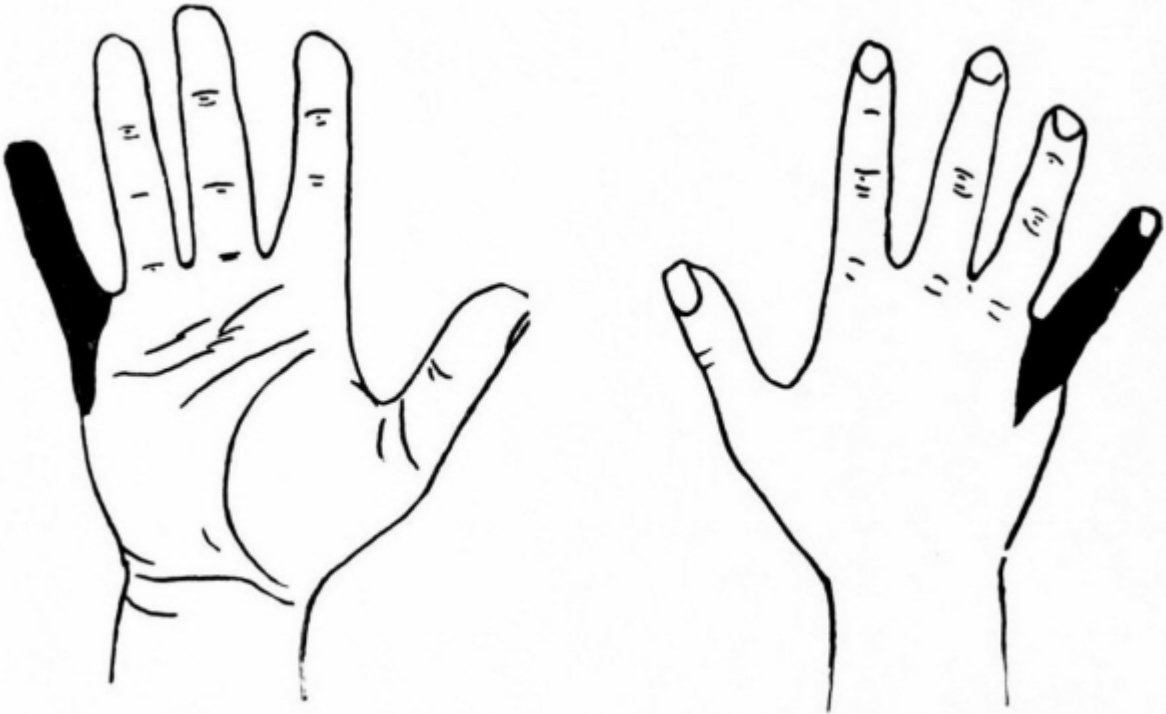

FIG. 128.—Smallest composite area of analgesia in ulnar nerve lesions