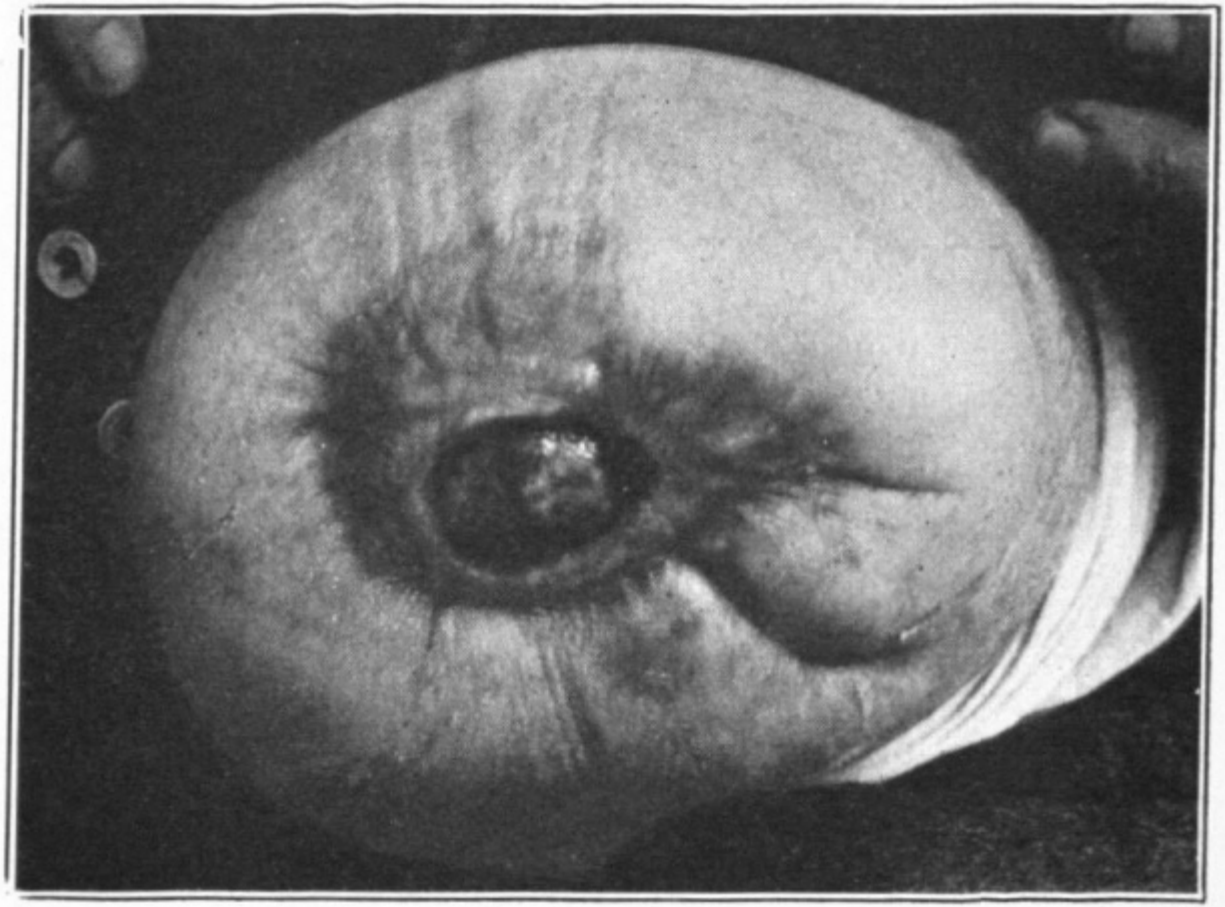

FIG. 132.—Second stage. The scar is contracting, but a fairly large open area with indolent skin margin remains