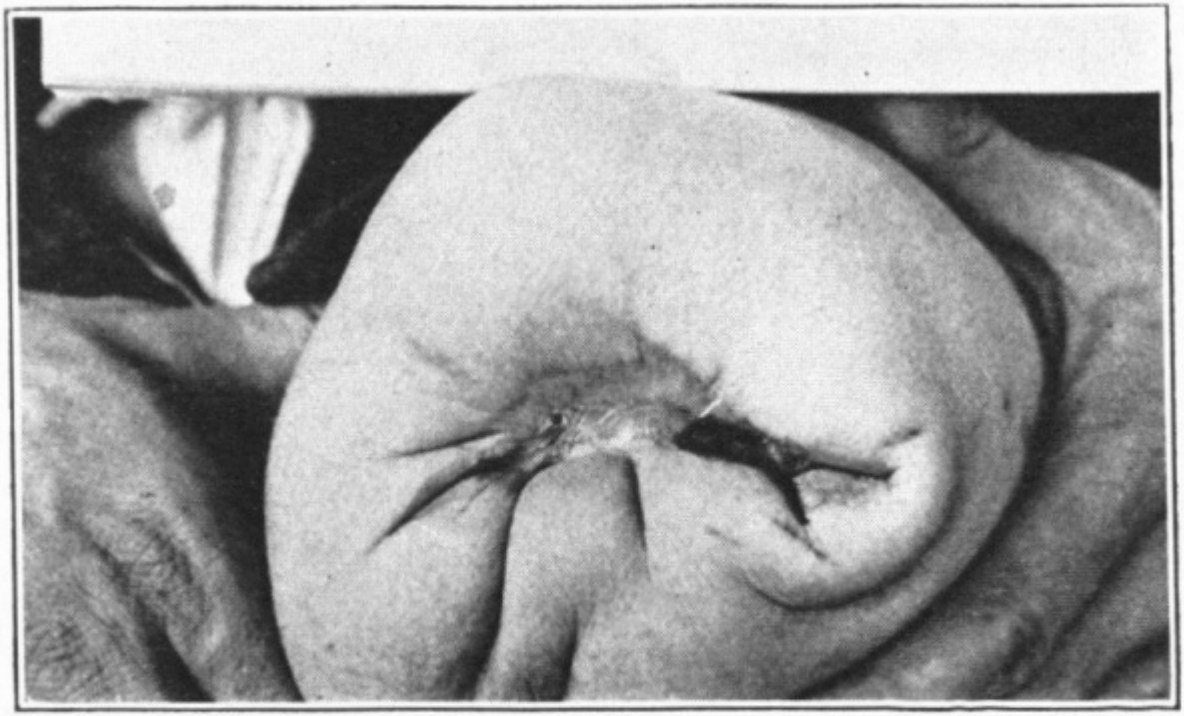

FIG. 133.—The end result which may be expected in the absence of bone infection. The scar has shut down, pulling the skin with it, and there now remains a thin, adherent puckered scar