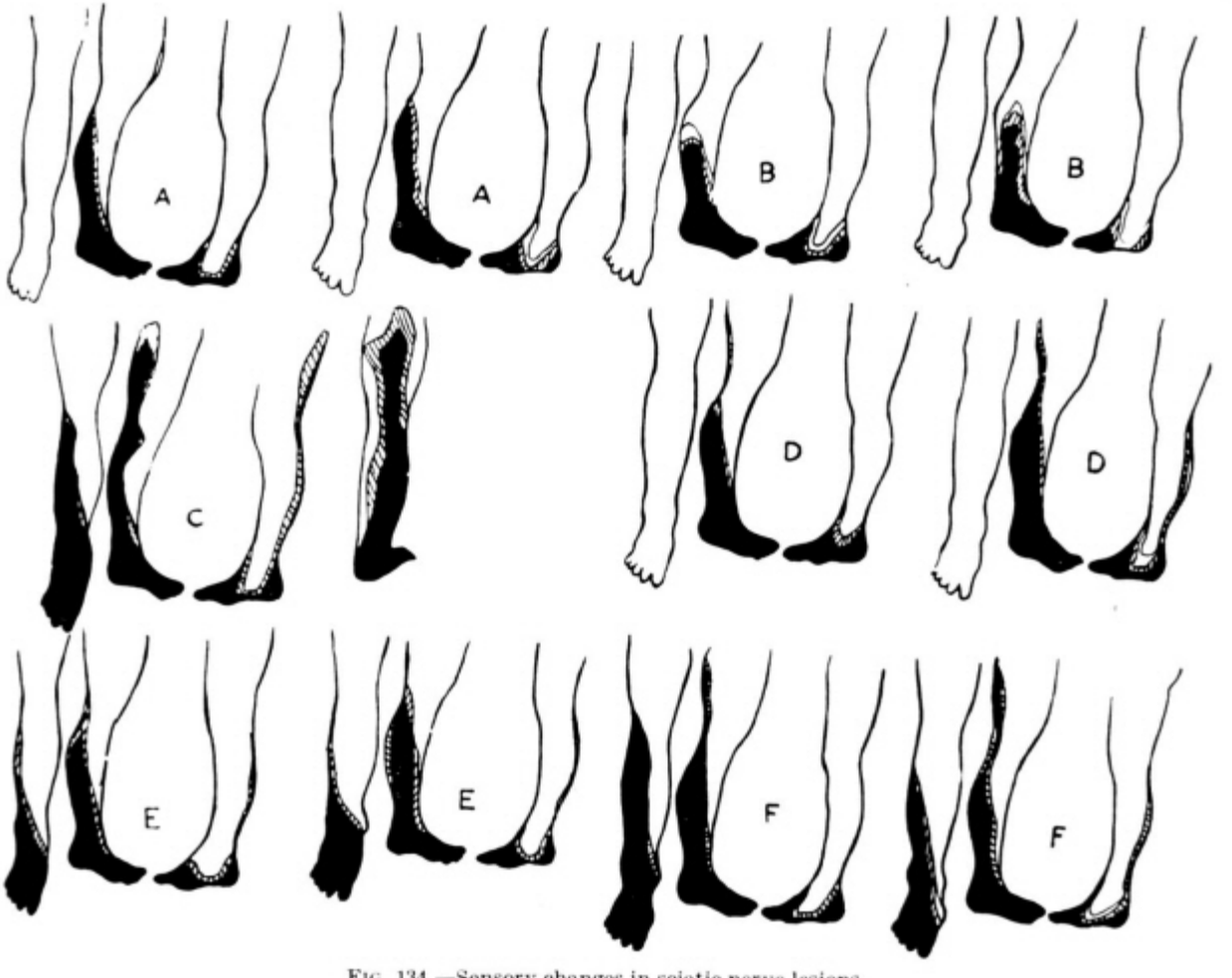

FIG. 134.—Sensory changes in sciatic nerve lesions