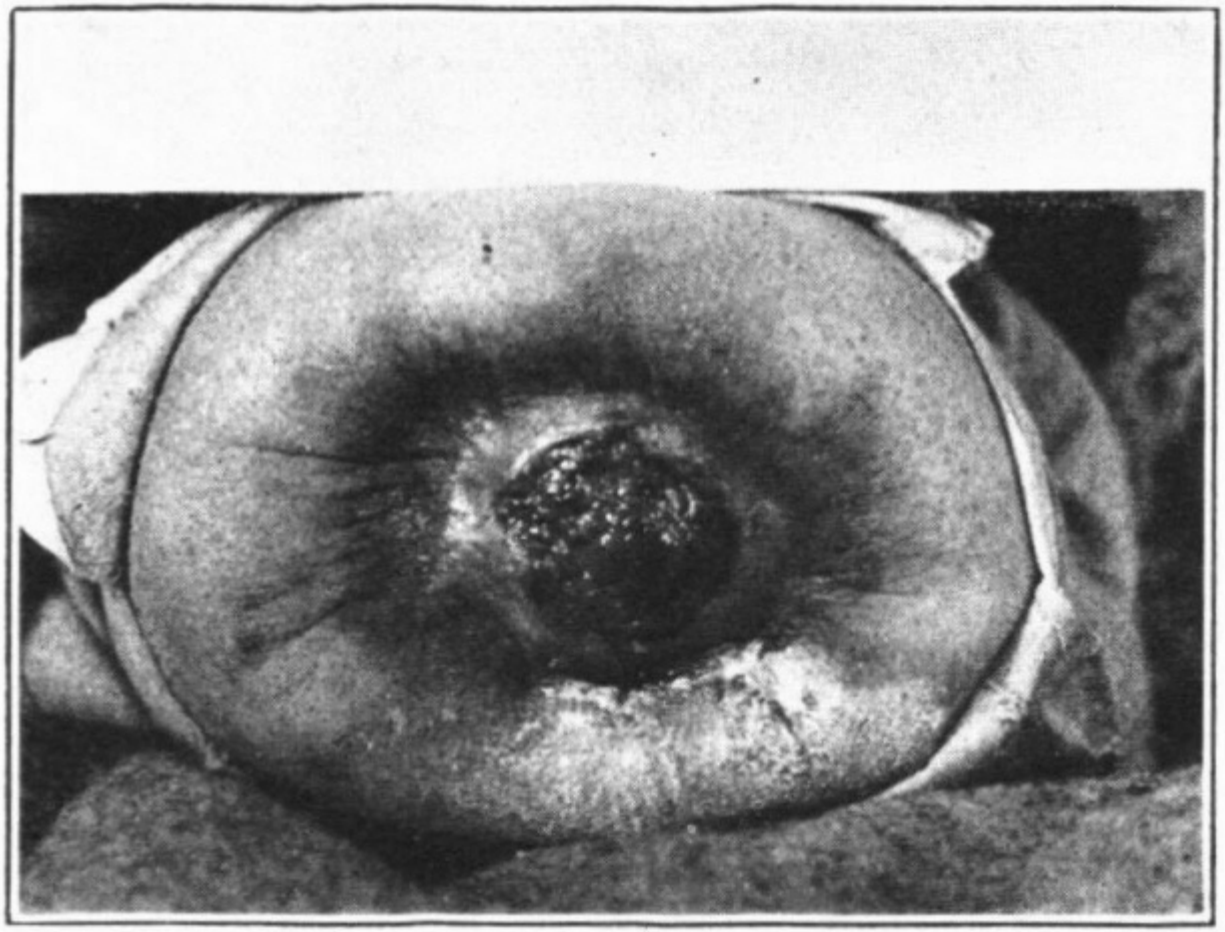

FIG. 135.—Short amputation of the thigh. There has been considerable retraction of soft parts, but the stump has been treated by extension, with considerable gain