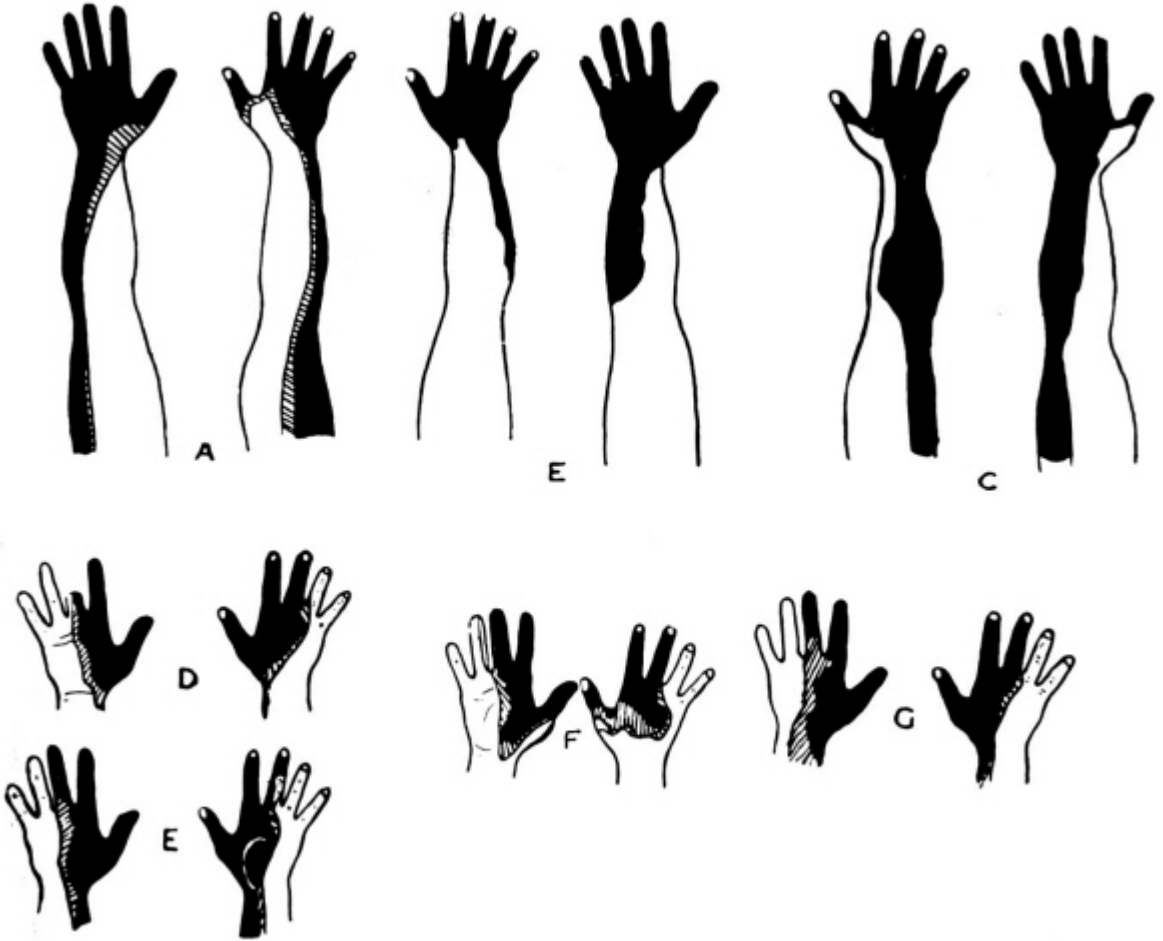

FIG. 137.—Sensory changes in combined lesions of the ulnar, radial, and median nerves, A, B, C, and of the median and radial, D, E, F, G