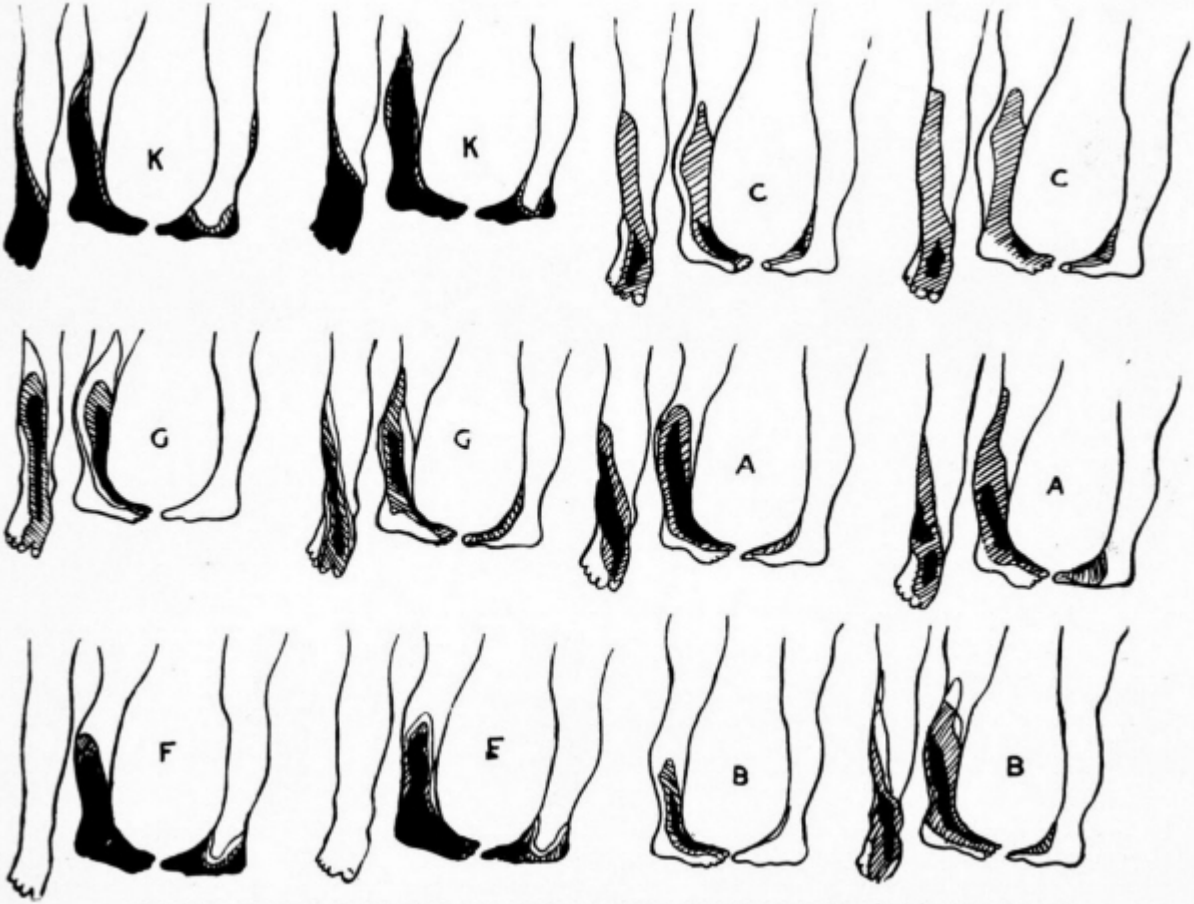

FIG. 140.—Sensory changes before and after resection of external popliteal and sciatic nerves