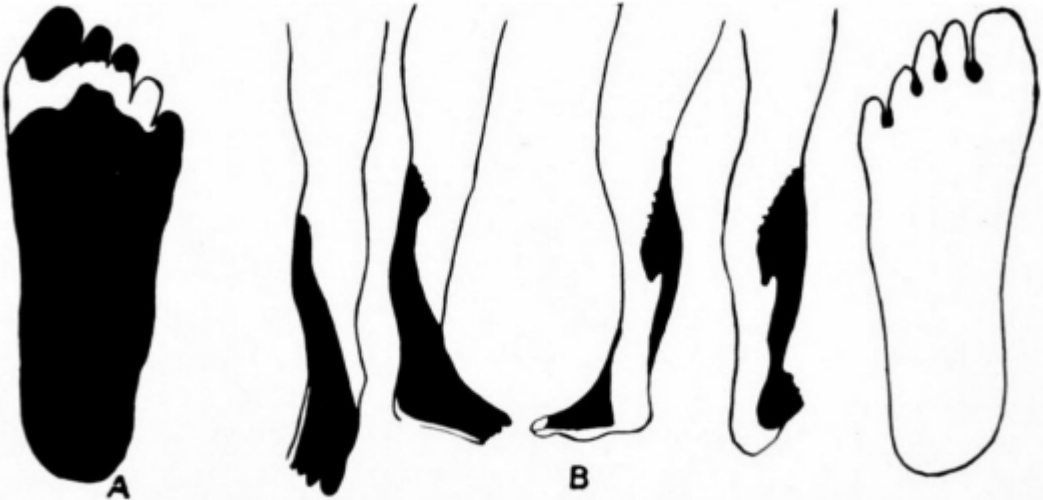

FIG. 147.—Residual sensibility to prick pain of external popliteal nerve, B; sensory changes in an uncertified case of complete interruption of the internal popliteal, A