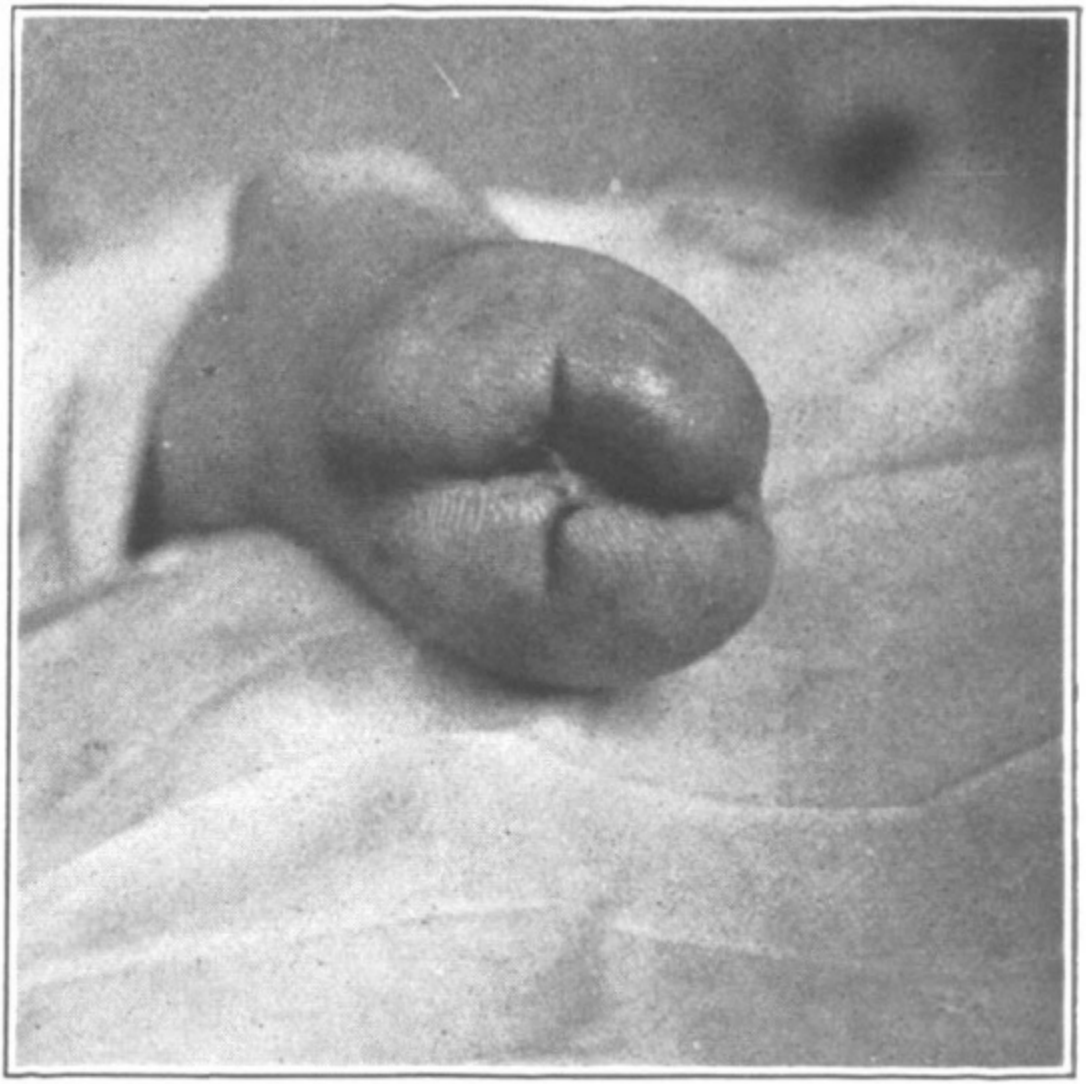

FIG. 159.—Stump showing terminal edema and other evidences of latent infection