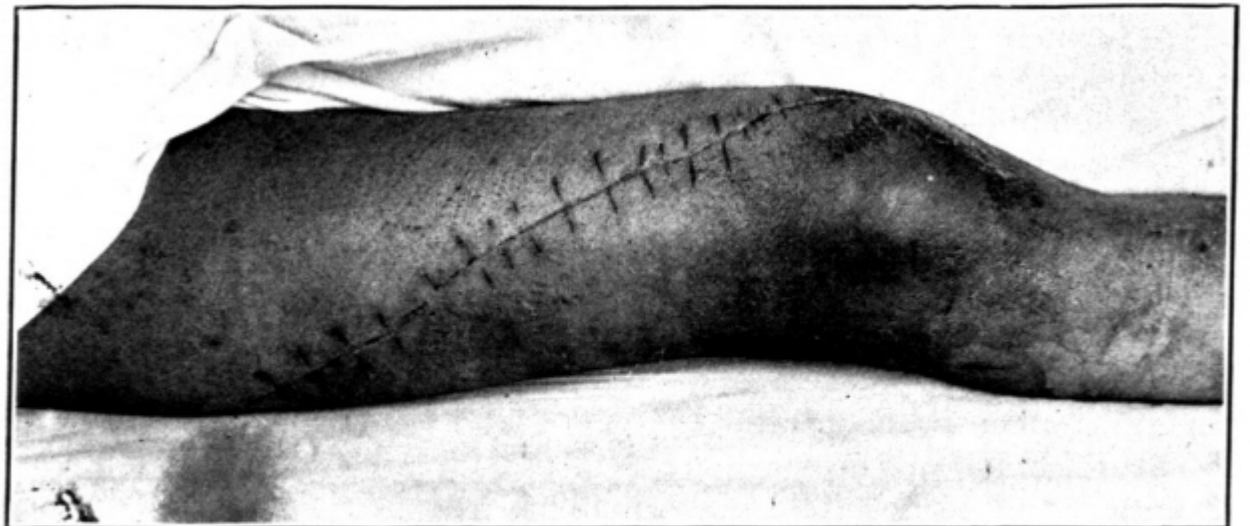

FIG. 166.—Long perforating wound of thigh, with opening of knee joint, closed by primary suture. (Heuer)