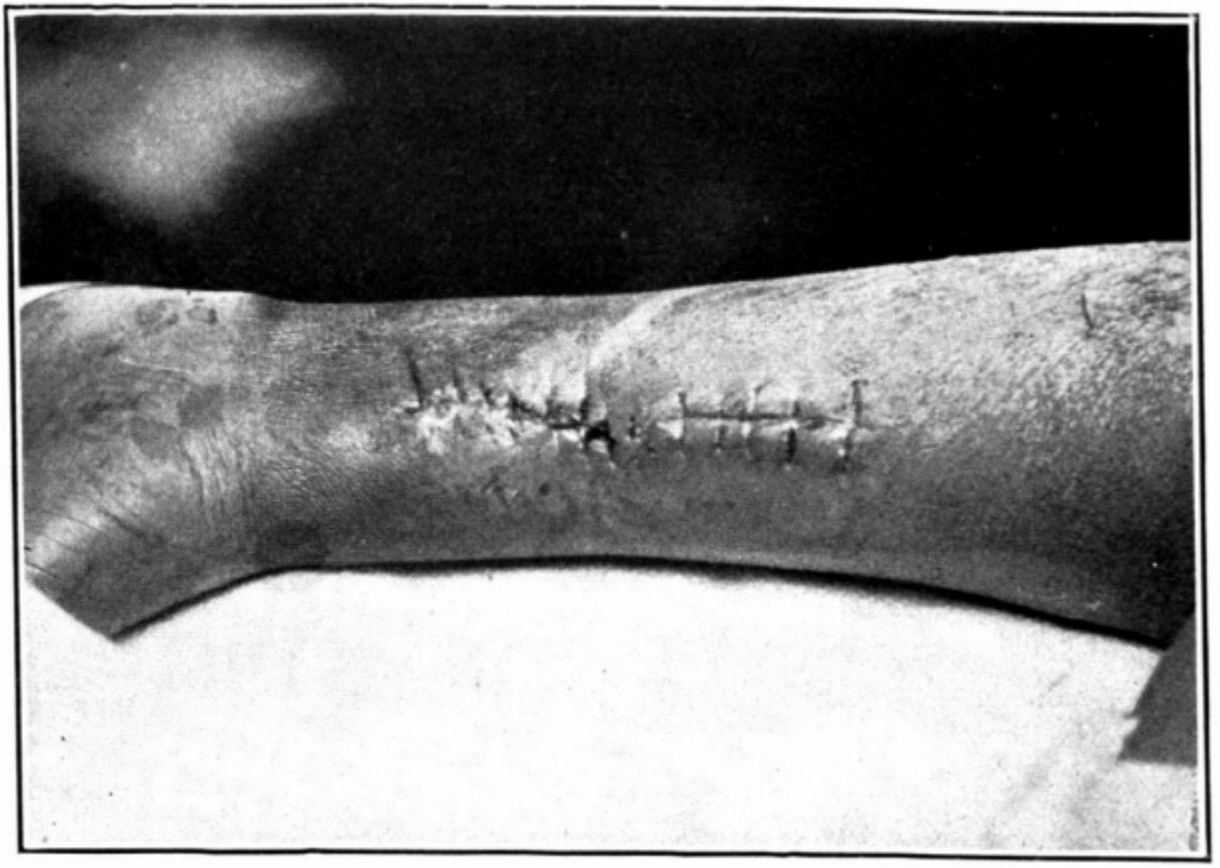

FIG. 167.—This and Figure 168 show perforating wounds of forearm with fracture (see fig. 169), two weeks after débridement and primary suture