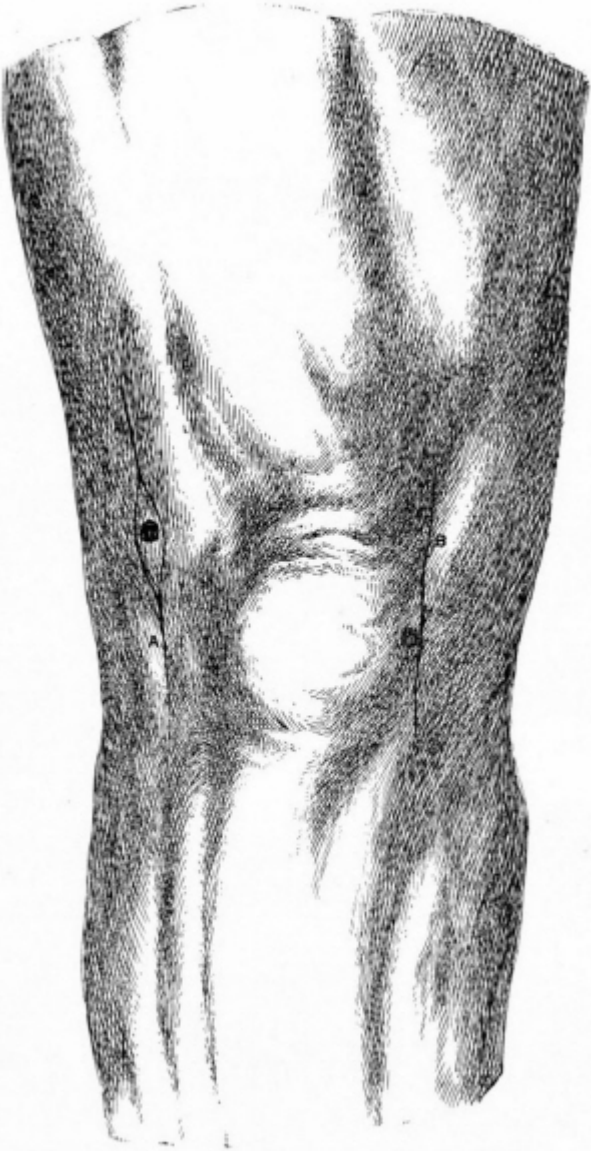

FIG. 174.—Gunshot wound of knee. A, Incision for débridement of wound of entrance; B, incision to expose retained foreign body. (See fig. 175.) (Keen's Surgery)