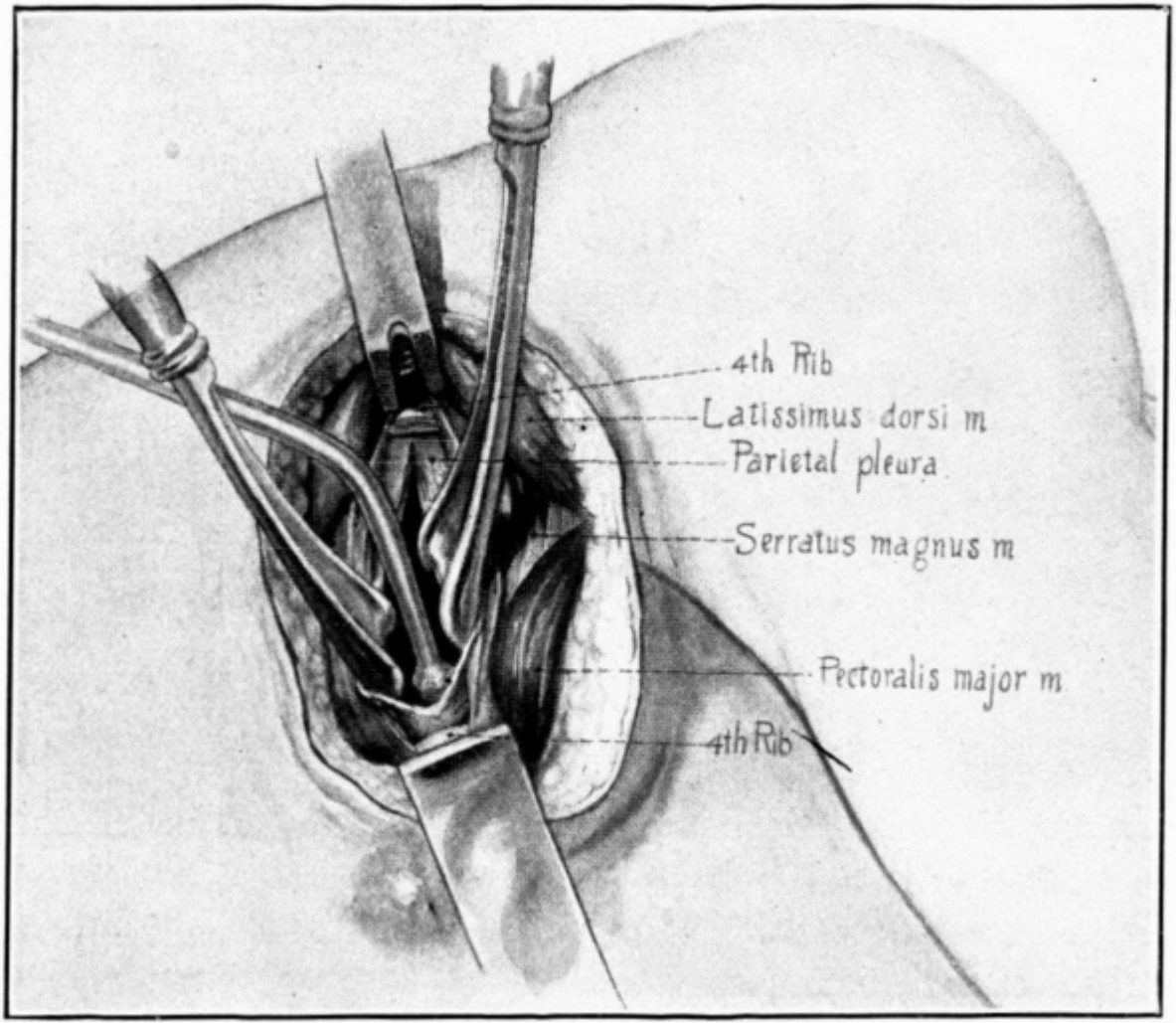


FIG. 187.—Thoracotomy of election. A rib has been resected; the tip of an aspirating nozzle is being introduced into the pleural cavity