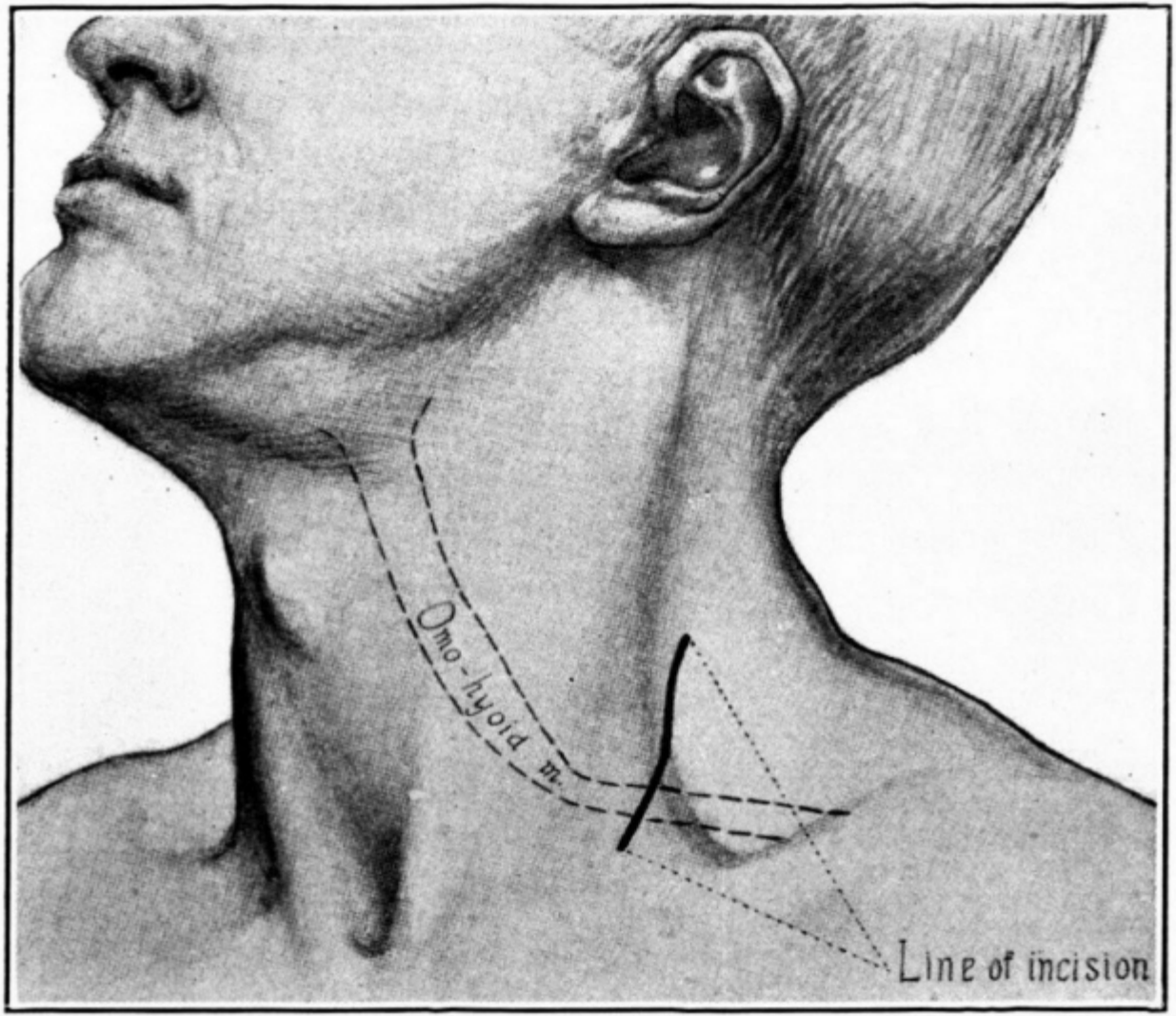

FIG. 189.—Incision for exposure of the phrenic nerve