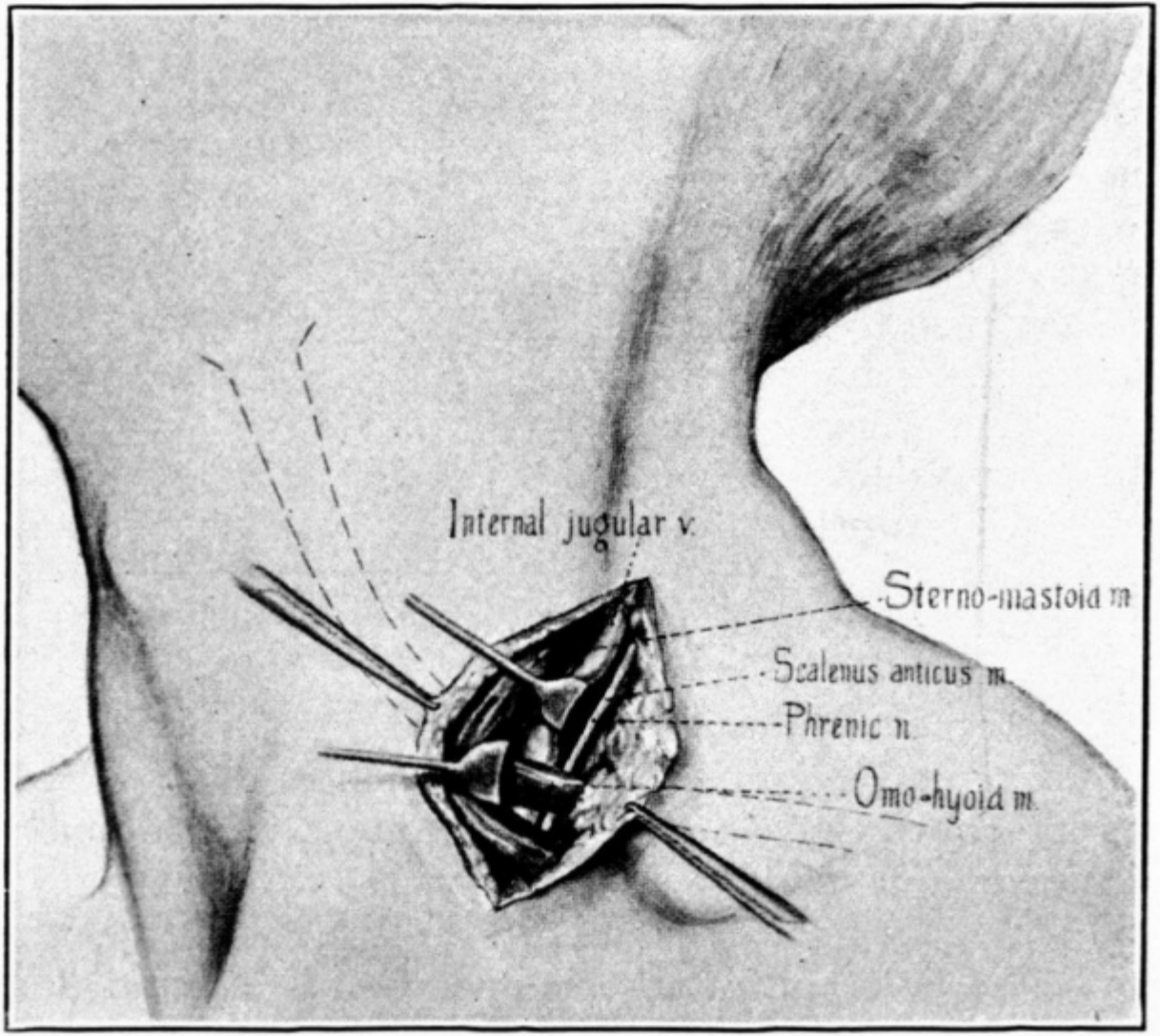

FIG. 190.—Exposure of the phrenic nerve