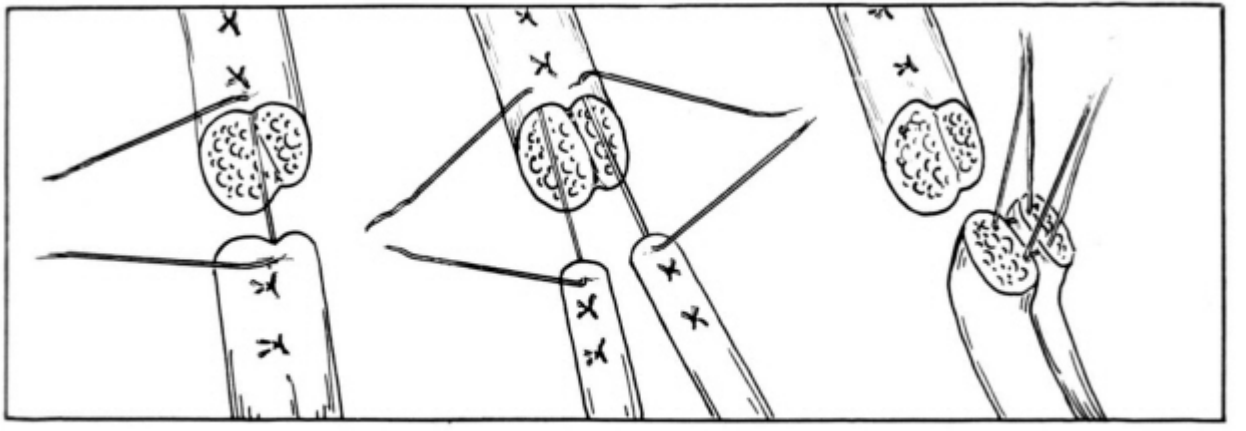

FIG. 195.—Method of alignment in physiologic approximation of the sciatic trunk, the intraneural septum between the peroneal and tibial portions of the trunk serving as a guide to alignment