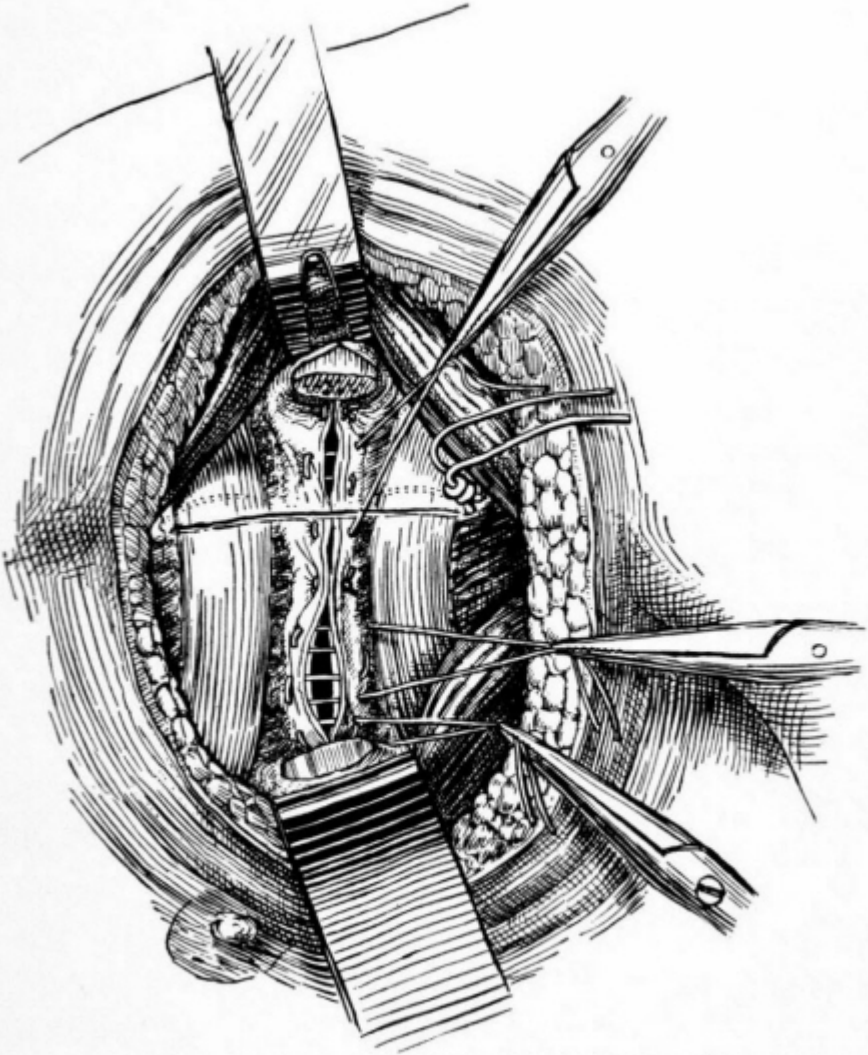

FIG. 197.—Closure of the chest wall after thoracotomy. The rib stay is drawn taut and fixed so that it can easily be removed