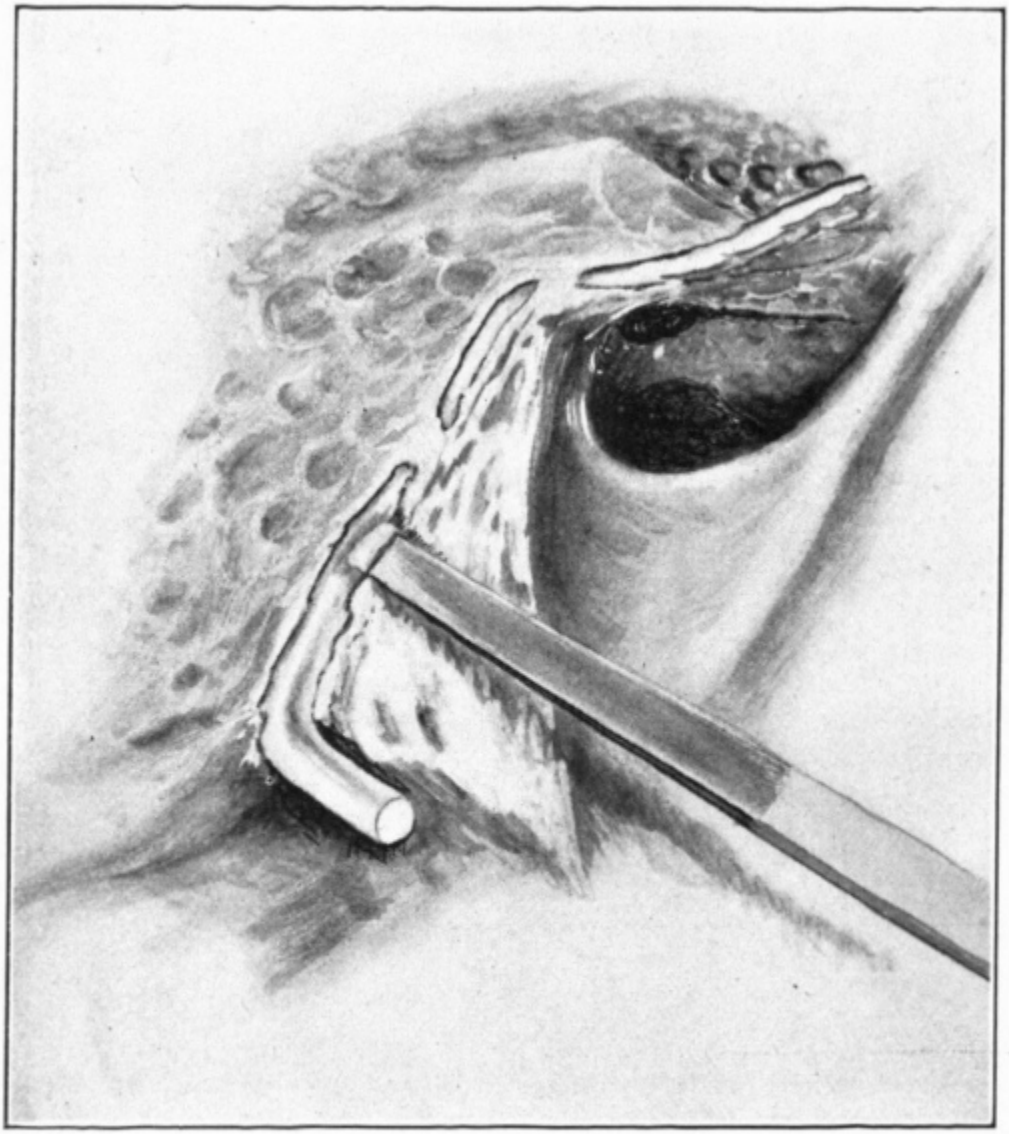

FIG. 204.—Facial nerve uncovered through a portion of its vertical and tympanic course, showing method of breaking down the wall with a fine, sharp chisel. (Ney. *The Laryngoscope*, 1922)