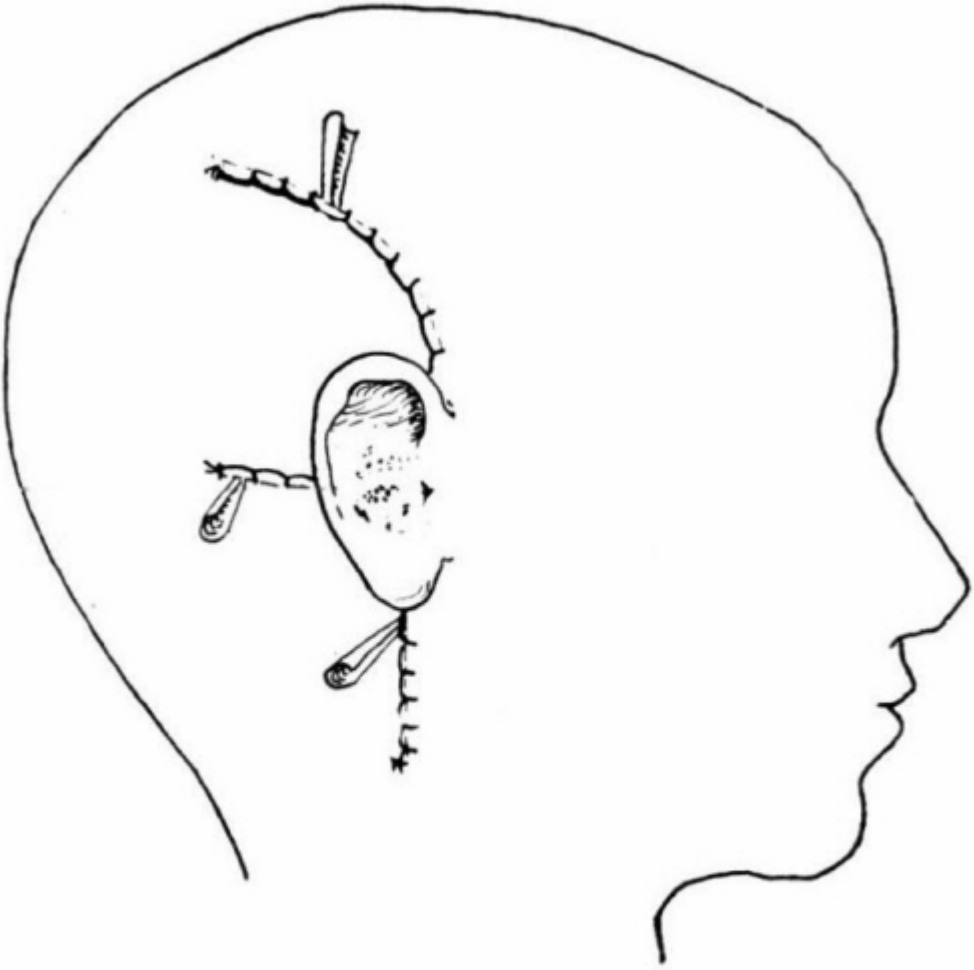

FIG. 210.—Incision closed; points of drainage indicated. External auditory meatus lightly packed with iodoform gauze. (Ney. *The Laryngoscope*, 1922)