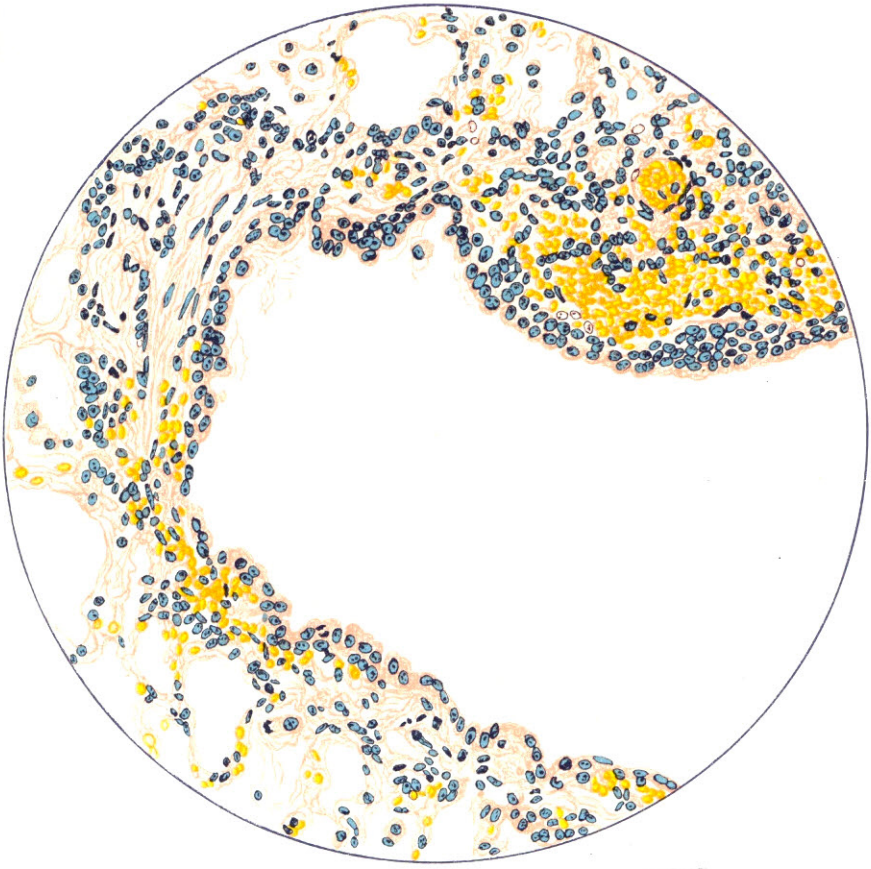

HIGHER MAGNIFICATION OF BRONCHUS SHOWN IN PLATE XIII.

Note particularly the flattened character of the regenerating bronchial epithelium. A mitotic figure is seen on the left.