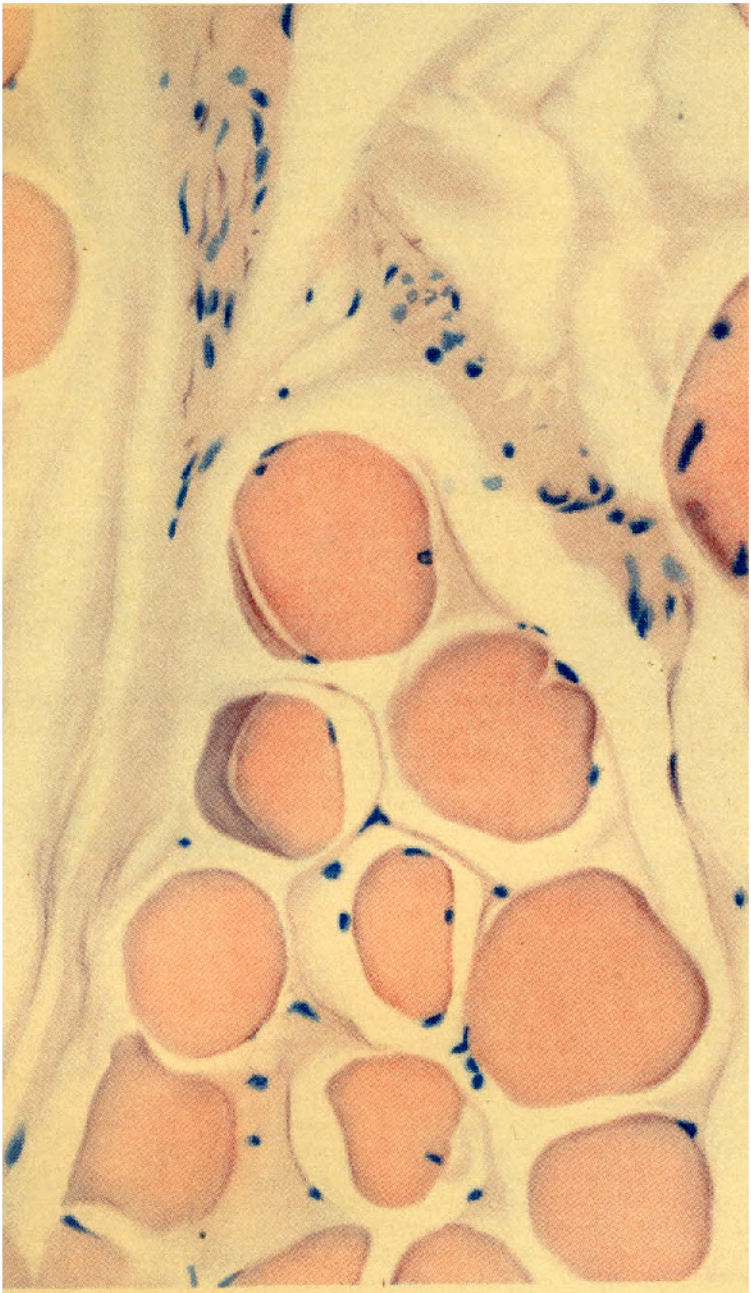

NECROTIC MUSCLE FIBERS.

Variation in staining due to chemical changes. (See Fig. 262).

Accession 2891, Army Medical Museum. H. & E. stain. Autochrome.