

DAMAGE CONTROL SURGERY

Chapter 5

Contributing Authors

Brian J. Eastridge, MD, COL, MC, US Army
Lorne H. Blackbourne, MD, COL, MC, US Army
Todd Rasmussen, MD, LTC, US Air Force
Henry Cryer, MD
Alan Murdock, MD, LTC, US Air Force

All figures and tables included in this chapter have been used with permission from Pelagique, LLC, the UCLA Center for International Medicine, and/or the authors, unless otherwise noted.

Use of imagery from the Defense Imagery Management Operations Center (DIMOC) does not imply or constitute Department of Defense (DOD) endorsement of this company, its products, or services.

Disclaimer

The opinions and views expressed herein belong solely to those of the authors. They are not nor should they be implied as being endorsed by the United States Uniformed Services University of the Health Sciences, Department of the Army, Department of the Navy, Department of the Air Force, Department of Defense, or any other branch of the federal government.

Table of Contents

Introduction to Damage Control	169
General Principles of Damage Control	169
Thoracic Injury Damage Control	173
<i>Emergency Thoracotomy</i>	<i>173</i>
<i>Intrathoracic Vascular Injury</i>	<i>175</i>
<i>Pulmonary and Tracheobronchial Injuries.....</i>	<i>178</i>
<i>Esophageal Injury.....</i>	<i>180</i>
Neck Injury Damage Control.....	181
Abdominal Injury Damage Control	184
<i>Damage Control Laparotomy</i>	<i>184</i>
Retrohepatic Hematoma.....	186
Perihepatic Vascular Injury.....	186
Hepatic Parenchymal Injury	186
Pancreatic and Duodenal Injuries.....	187
Renal Injury	188
Ureteral Injury	190
Splenic Injury.....	190
Large Soft-Tissue and Retroperitoneal Wounds.....	192
<i>Intestinal (Enteric) Injuries</i>	<i>192</i>
<i>Rectal Injury</i>	<i>193</i>
<i>Abdominal Wall Closure</i>	<i>194</i>
Peripheral Vascular Injury Damage Control.....	195
<i>Arterial Injury and Temporary Vascular Shunts</i>	<i>195</i>
Role of Temporary Vascular Shunts in Afghanistan and Iraq	196
Complications	198
Conclusions	199
<i>Venous Injury.....</i>	<i>200</i>
<i>Proximity to Great Vessel Injury</i>	<i>200</i>
<i>Extremity Tourniquets.....</i>	<i>200</i>
<i>Upper Extremity Arterial Injury</i>	<i>201</i>
<i>Femoral Vasculature Injury</i>	<i>201</i>
<i>Popliteal and Tibial Vasculature Injuries.....</i>	<i>201</i>
Pelvic Injury Damage Control	202
<i>Background.....</i>	<i>202</i>
<i>Physical Examination</i>	<i>203</i>
<i>Radiographic Evaluation.....</i>	<i>203</i>
Plain Radiography	204
Computed Tomography Imaging.....	204

Angiography.....	205
<i>Acute Management</i>	205
<i>Open Pelvic Fractures</i>	207
<i>Bladder and Urethral Injuries</i>	208
Management of Bladder Injuries	209
Management of Urethral Injuries	209
<i>Genitalia Injuries</i>	210
 Damage Control Summary	 211
 References	 212

Introduction to Damage Control

Damage control surgery techniques have evolved within the continuum of military and civilian trauma care since the Napoleonic Wars. Though civilian trauma surgeons now uniformly embrace the relatively contemporary label “damage control,” the techniques have firm foundation within the history of military medicine.¹ In the later part of the 18th century during the Napoleonic campaign, the French surgeon Larrey succinctly alluded to the rationale for expedited battlefield procedures: “When a limb is so much injured by a gunshot wound that it cannot be saved, it should be amputated immediately. The first 24 hours is the only period during which the system remains tranquil, and we should hasten during this time, as in all dangerous diseases, to adopt the necessary remedy.”² Military historical references to the techniques of damage control surgery in the United States (US) appear around the time of the Civil War (Fig. 1).³ In World War II, the Second Auxiliary Surgery Group treated over 22,000 combat wounded soldiers, including 8,800 “severely wounded,” during a two-year interval from 1943 to 1945.⁴ The ensuing 912-page report and scientific publications that were consequent to the operation yielded insight into the surgical treatment of thoracic injury; the reactive lung injury associated with severe trauma denoted “the wet lung of trauma,” which we now know as acute respiratory distress syndrome (ARDS); and the utility of techniques aimed at the “correction of profound physiologic disturbances which immediately endanger life” is now described by the moniker, damage control. In the Vietnam War, it was recognized in several case series that temporizing surgical procedures often demonstrated a survival advantage when compared to definitive surgical therapy.⁵ Though apparently temporarily forgotten after the Vietnam War, the technique reappeared in the hallmark publication by Stone in 1983, which advocated abbreviated celiotomy in patients with abdominal injury with associated coagulopathy and hypothermia.⁶ Since that time, many reported successes with similar salvage techniques have been cited.^{7,8,9,10} Within the last decade, a number of authors have also described the expansion of this lifesaving surgical practice to include thoracic, vascular, orthopedic, and neurosurgical procedures.^{11,12,13,14}

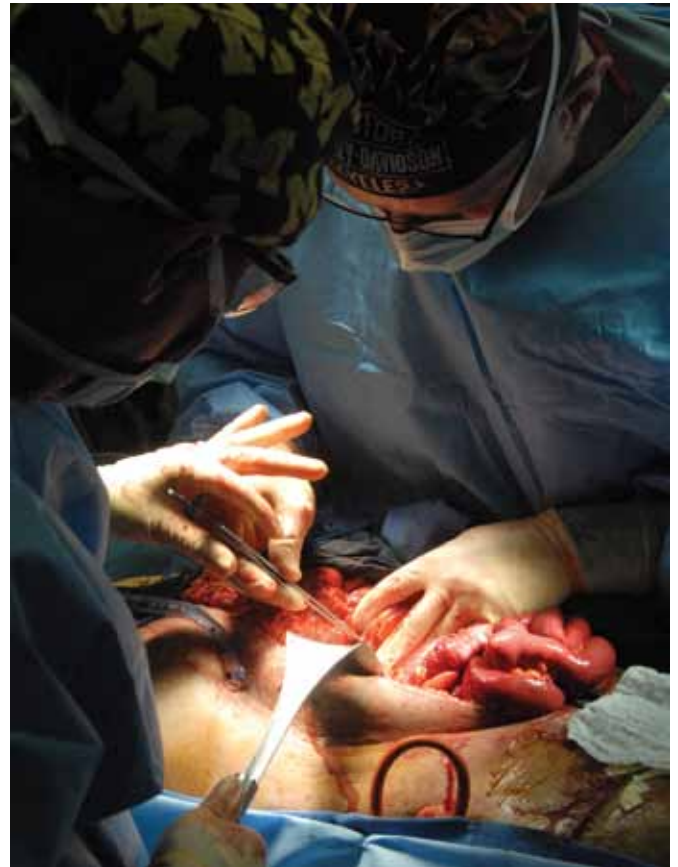

Figure 1. *Damage control surgery at a Level III facility. This lifesaving surgical paradigm now includes thoracic, vascular, orthopedic, and neurosurgical procedures.*

General Principles of Damage Control

Modern day concepts of damage control have been honed in the civilian sector resulting in survival rates of 50 percent in severely injured patients in hemorrhagic shock.^{15,16,17,18,19,20,21,22} Damage control as it is

currently practiced is simply defined as the rapid initial control of hemorrhage and contamination with packing and a temporary closure, followed by physiologic resuscitation in the intensive care unit (ICU), and subsequent reexploration and definitive repair once normal physiology has been restored (Fig. 2). From a military perspective, damage control concepts apply to all body regions, with an emphasis on abbreviated and focused surgery on patients expected to survive, thus conserving resources and allowing definitive care at the next level of care.



Figure 2. Damage control procedures are defined by an abbreviated surgery, followed by resuscitation in the ICU, with subsequent reexploration and definitive repair once normal physiology has been restored. This approach has led to improved patient survival.

Rapidly achieving these objectives in severely injured trauma patients is crucial to mitigating the trauma “lethal triad” of hypothermia, acidosis, and coagulopathy.²³ The acidosis results from hypovolemic shock and inadequate tissue perfusion. Hypothermia results from exsanguination and loss of intrinsic thermoregulation. Coagulopathy results from hypothermia, acidemia, platelet and clotting factors consumption, and blood loss. Coagulopathy, in turn, causes more hemorrhage and thus causes more acidosis and hypothermia; so the “bloody vicious cycle” continues. Once established, this vicious cycle is almost uniformly fatal and must be prevented using damage control principles rather than attempting to treat it once it has occurred.

Damage control surgery is defined as the rapid initial control of hemorrhage and contamination with packing and temporary closure, followed by resuscitation in the ICU, and subsequent reexploration and definitive repair once normal physiology has been restored.

While the current principles of damage control in well-equipped trauma centers have led to improved survival, the combat environment offers challenges and adds complexity to the practice of damage control. Nonetheless, descriptions of military applications of damage control procedures have recently emerged in the trauma literature. Although these publications comprise a small series of patients, they suggest that damage control in the combat environment is as effective as it is in civilian trauma care.^{24,25,26,27}

As currently configured, the military process involves the simultaneous and coordinated operation, resuscitation, and serial evacuation of the casualty, via both rotary-wing and fixed-wing aircraft, through several levels of military medical care across continents (Fig. 3). The feasibility of damage control in combat casualty care (CCC) settings is dependent upon: (1) the availability of resources to prevent and treat hypothermia, coagulopathy, and acidosis; and (2) the ability to provide supportive care pending staged reoperation or evacuation from theater with subsequent staged operation in Germany, future Level IV facilities, or the US. Central to CCC that takes place in the relatively resource-constrained environment of a theater of war is the capability of military Level II and Level III care facilities to supply blood components, including packed red blood cells, plasma, and platelets commensurate with demand

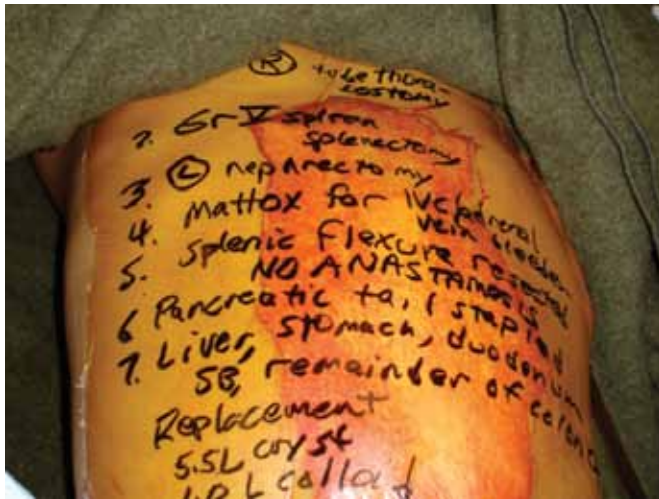
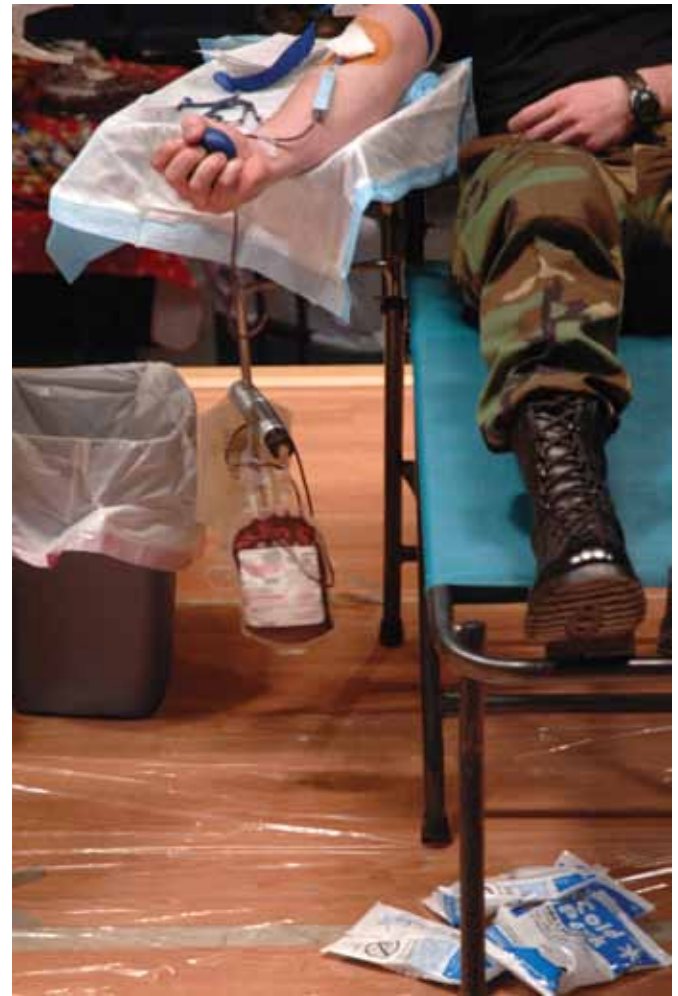


Figure 3. (Above) *Improvised patient information communication written directly onto a dressing following damage control surgery. The current military process involves simultaneous and coordinated operation, resuscitation, and serial evacuation of casualties through several levels of combat casualty care across continents, making accurate communication exceedingly important.*

Figure 4. (Right) *The walking blood bank can rapidly collect fresh whole blood when other blood products are in short supply. Image courtesy of Defense Imagery Management Operations Center (DIMOC).*



The military CCC process involves the simultaneous and coordinated operation, resuscitation, and serial evacuation of the casualty, via both rotary-wing and fixed-wing aircraft, through several levels of military medical care across continents.

Recent advances in the concept of damage control resuscitation (DCR) have resulted in the transfusion of one unit of plasma for each unit of packed red blood cells in the massive transfusion setting.²⁸ This novel paradigm of resuscitation is thought to be largely responsible for the substantially decreased mortality from coagulopathy in the most severely injured casualties.²⁹ Another novel concept developed by the military has been the use of the walking blood bank using fresh whole blood donated by soldiers on site, when large stores of fresh frozen plasma and packed red blood cells are in short supply (Fig. 4).³⁰

Damage control resuscitation is a strategy that seeks to prevent or mitigate hypothermia, acidosis, and coagulopathy through combined treatment paradigms. Damage control resuscitation comprises early hemorrhage control, hypotensive resuscitation (permissive hypotension), hemostatic resuscitation (minimization of crystalloid fluids and fixed ratio blood product transfusion), prevention or alleviation of hypothermia (through warming measures), and amelioration of acidosis through judicious use of blood products and hemodynamic resuscitation endpoints.

Figure 5. (Top Right) *Intensive care units at Level III facilities are robustly resourced such that care received on the battlefield is akin to care at any Level I trauma center in the US.*

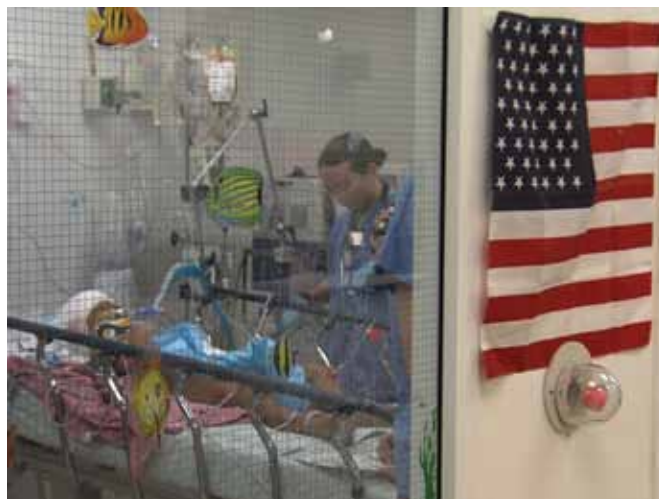
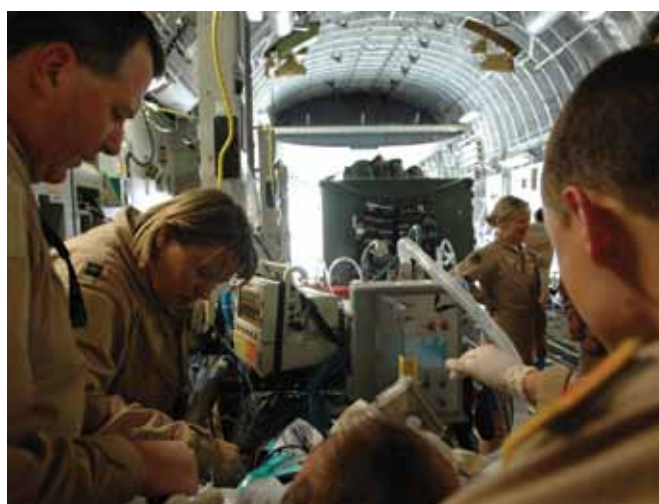
Figure 6. (Bottom Left) *All US and coalition casualties with critical care requirements in the current conflicts in Iraq and Afghanistan are flown out-of-theater to Germany with the assistance of a CCATT. Image courtesy of Donald C. Kowalewski, LTC, MC, USAF*

Figure 7. (Bottom Right) *The CCATT teams facilitate the rapid evacuation of severely ill patients, which translates into better patient care as well as a significantly decreased forward medical footprint. Image courtesy of Donald C. Kowalewski, LTC, MC, USAF*



Given the battlefield constraints of multiple-casualty-incidents, the need for rapid turnover of operating rooms, and the limited number of critical care beds, it is more advantageous to resource allocation and utilization to perform damage control procedures early. Intensive care units at Level III facilities are robustly staffed and resourced such that care received on the battlefield of Iraq and Afghanistan is akin to care at any Level I trauma center in the US (Fig. 5). However, operational tempo limits the combat casualty's ability to occupy an ICU bed for an extended length of time.

One of the most substantial advances in recent military medicine, the Critical Care Aeromedical Transport Team (CCATT), has been instrumental in circumventing this problem. These teams provide en-route intensive care to patients requiring evacuation. Most US and coalition casualties spend less than 48 hours in-theater and many times in high-acuity cases, less than 24 hours (Figs. 6 and 7).^{31,32,33} With such advanced surgical and critical care capacity, it is feasible to care for the high-acuity patient requiring damage control surgery within the combat theater during the acute surgical, postoperative intensive care stabilization, reoperation, and evacuation phases. As such, the philosophy of damage control continues to be appealing within the realm of CCC, since encompassed within the contingencies of the modern battlefield are a finite pool of manpower and therapeutic resources, a nonlinear battlefield with a highly mobile force, a multiplicity of casualties, and highly destructive mechanisms of injury.

Thoracic Injury Damage Control

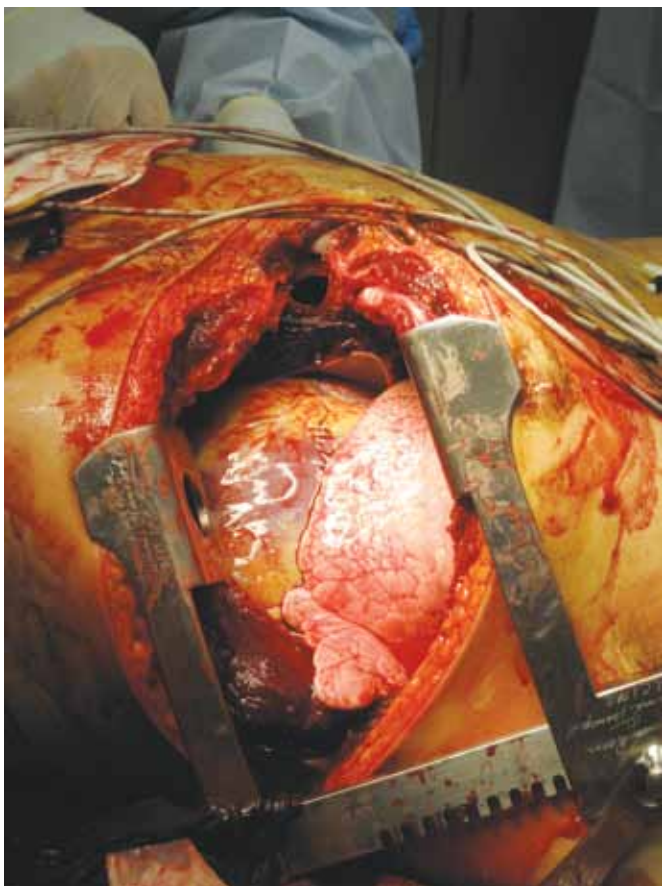
Emergency Thoracotomy

Thoracic damage control surgery can be stratified into two domains: procedures that occur in the emergency department (ED) and those that take place in the operating room. Thoracic procedures that are undertaken in the ED are reserved for those patients who present in extremis with signs and symptoms suggestive of thoracic injury. Collective reviews in the literature have demonstrated survival rates of 8.8 to 11.1 percent for penetrating injury and 1.4 to 1.6 percent for blunt injury after resuscitative thoracotomy for civilian injury.^{34,35} In a related combat-environment setting analysis, 12 of 94 patients undergoing resuscitative thoracotomy for penetrating injuries survived, while none of the seven patients with blunt injury survived. Of note, this military study expanded the indication for resuscitative thoracotomy for patients in extremis with injuries to the abdomen (30 percent) and extremities (22 percent).³⁶

The objectives of a thoracotomy are to: (1) confirm ventilatory support by observing expansion of the left lung; (2) open the pericardium to relieve pericardial tamponade; (3) apply occlusive pressure and clamp the descending aorta to restore central perfusion to the brain and heart; (4) provide direct cardiac compression to circulate blood; and (5) control visible hemorrhage.

The basic conduct of resuscitative thoracotomy includes simultaneous left-sided anterolateral thoracotomy with establishment of an airway and ventilatory support, chest tube placement in the contralateral chest cavity, large-bore intravenous access, and initiation of a massive transfusion protocol with a 1:1 ratio of fresh frozen plasma to packed red blood cells or the use of fresh whole blood. The thoracotomy is initiated with an expeditious and generous left anterolateral chest incision in the fifth intercostal space (i.e., below the nipple at the inframammary fold) carried down to the chest wall sharply (Fig. 8). At this point, one blade of a pair of heavy Mayo scissors is inserted into the pleural space on the cephalad edge of the sixth rib, and with a pushing stroke the intercostal musculature is opened both posteriorly and anteriorly to the sternal edge. Care must be taken to incise along the curvature of the ribs to avoid accidentally transecting ribs. This will minimize injury to the intercostal neurovascular bundle and avoid creating sharp bone margins capable of creating iatrogenic injury to careproviders. A rib-spreading retractor is placed within the thoracotomy incision with the handle positioned downward toward the bed and opened to expose the left thoracic cavity. Once the thoracic cavity has been exposed, the objectives of the procedure are to: (1) confirm ventilatory support by observing expansion of the left lung; (2) open the pericardium anterior to the phrenic nerve to relieve pericardial tamponade; (3) apply occlusive pressure and clamp the descending aorta to restore central perfusion to the brain and heart; (4) provide direct cardiac compression to circulate blood; and (5) control visible hemorrhage. Although most careproviders perform cardiac compressions by holding the heart between their hands (mostly fingers due to space constraints), compressions are generally more efficient with placement of the palm of one hand on the posterior heart and pressing upward towards the sternum (Fig. 9).

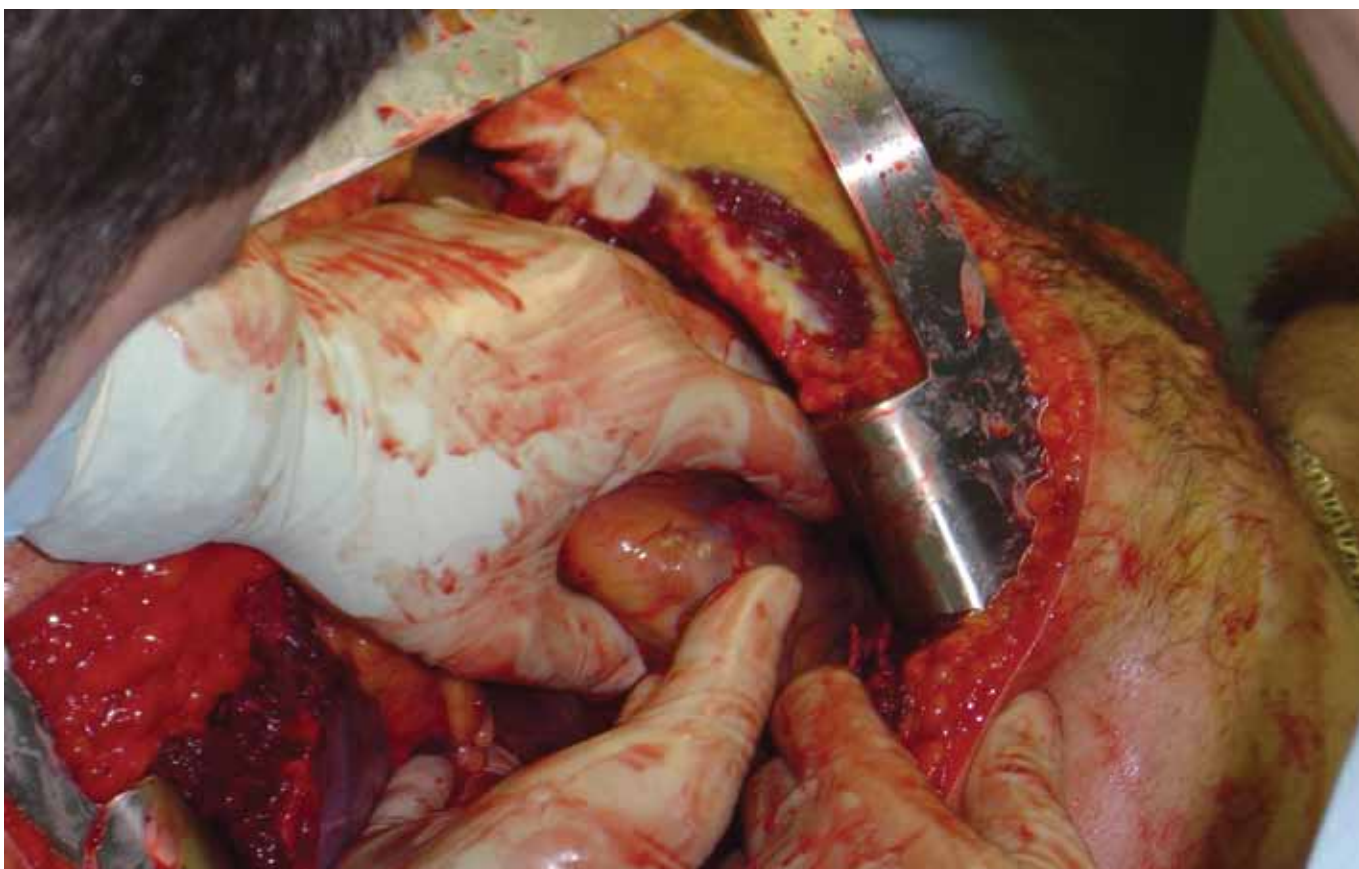The pericardium is grasped with DeBakey forceps anterior to the phrenic nerve, and the pericardial sac is opened completely with Metzenbaum scissors in a craniocaudal direction so as not to injure the phrenic nerve. Once the pericardium is incised, the tamponade is relieved and the heart can be delivered into the left chest. If obvious ongoing hemorrhage from the heart is noted, it is initially controlled with digital pressure. The descending aorta can either be compressed manually against the spine or clamped



with a vascular clamp. Lifting the lung anteriorly helps to visualize the posterior mediastinum and facilitates direct access to the aorta. Once the posterior mediastinum is visualized, the parietal pleura is incised, and the opening extended bluntly anteriorly as well as posteriorly along the spine to allow insertion of a large vascular clamp across the aorta. Direct visualization is also useful so that the clamp is not inadvertently placed on the esophagus or below the level of an aortic injury, thereby exacerbating hemorrhage. Adjunctive measures to attain visualization and vascular control include a surgical assistant compressing the lung anteriorly, temporarily disconnecting the patient from positive-

Figure 8. (Left) *Emergency thoracotomy is reserved for patients presenting in extremis with signs and symptoms suggestive of thoracic injury. Image courtesy of J. Christian Fox, MD, University of California, Irvine.*

Figure 9. (Below) *Although many careproviders perform cardiac compressions by holding the heart between their hands, compressions may be more efficient by placing the palm of one hand on the posterior heart and pressing upward towards the sternum. Image courtesy of J. Christian Fox, MD, University of California, Irvine.*



pressure ventilation, or performing a right mainstem bronchus intubation if the patient's cardiopulmonary status can tolerate single-lung ventilation. The inferior pulmonary ligament must be released from the diaphragm via sharp dissection to allow full exposure of the mediastinal structures.

Hemorrhage from penetrating cardiac wounds can often initially be controlled through digital pressure or occlusion. Atrial hemorrhage can also be temporized with a tangential vascular clamp and subsequently undergo a simple 3-0 Prolene™ running suture repair. If digital pressure is not sufficient to control ventricular bleeding, hemorrhage can be temporized with Foley catheter or Fogarty balloon tamponade, suture repair, or stapling (which is quick and effective for small lacerations).^{37,38,39,40} If a Foley catheter is used, it is important to completely flush the catheter with crystalloid solution to avoid subsequent air embolism upon introduction of the catheter into the injured heart. While controlling hemorrhage through suture repair of the ventricles, it is paramount to spare the coronary arteries (i.e., avoid accidentally ligating them). This can be performed by tying pledgeted suture bolsters on opposing sides of the coronary artery at-risk using vertical mattress sutures, while at the same time approximating the cardiac wound (Fig. 10).

If digital pressure or occlusion is not sufficient to control ventricular bleeding, hemorrhage can be temporized with Foley catheter or Fogarty balloon tamponade, suture repair, or stapling.

Control of hemorrhage from major thoracic vascular structures can be obtained by clamping or compressing affected vessels under direct visualization. In the circumstance where additional exposure to the right heart or right hemithorax is required, a left-sided anterolateral thoracotomy can be converted into a clamshell thoracotomy. This is done by extending the incision through the right fifth intercostal space after transecting the sternum with either a Gigli saw, Lebsche knife, heavy bone cutter, or electric sternal saw (Fig. 11). This incision provides the best exposure to the entire anterior and superior mediastinum and both pleural spaces by extending the incision to right chest above the nipple in a gentle S-shaped configuration. Vascular control of the internal mammary arteries following thoracotomy is important to prevent further blood loss and can be obtained by clamping or suture ligation.

Once a cardiac rhythm has been restored and bleeding temporarily controlled, the patient is expeditiously taken to the operating room. Such patients are at significant risk for the lethal triad of coagulopathy, acidosis, and hypothermia, so efforts to prevent and treat these conditions must be made during the resuscitative process. Once in the operating room, the patient is prepped and draped. Cardiac wounds can now be definitively repaired. When suturing ventricular cardiac wounds, it is important to use pledgets fashioned from Teflon® strips or pericardium to prevent suture shearing through the myocardium upon tying. Coronary vascular injuries occurring in combat typically require ligation, as coronary revascularization requires a cardiac bypass technician, bypass pump, and cardiac surgeon.

When suturing ventricular cardiac wounds, it is important to use pledgets fashioned from Teflon® strips or pericardium to prevent suture shearing through the myocardium upon tying. Additionally, it is paramount to avoid ligation of the coronary arteries when performing suture repair of the heart.

Intrathoracic Vascular Injury

Vascular injuries to the thorax (aorta and proximal arterial and venous branch vessels) are treated with basic

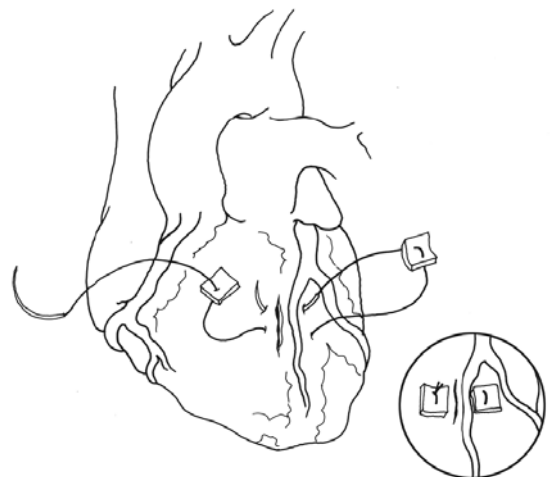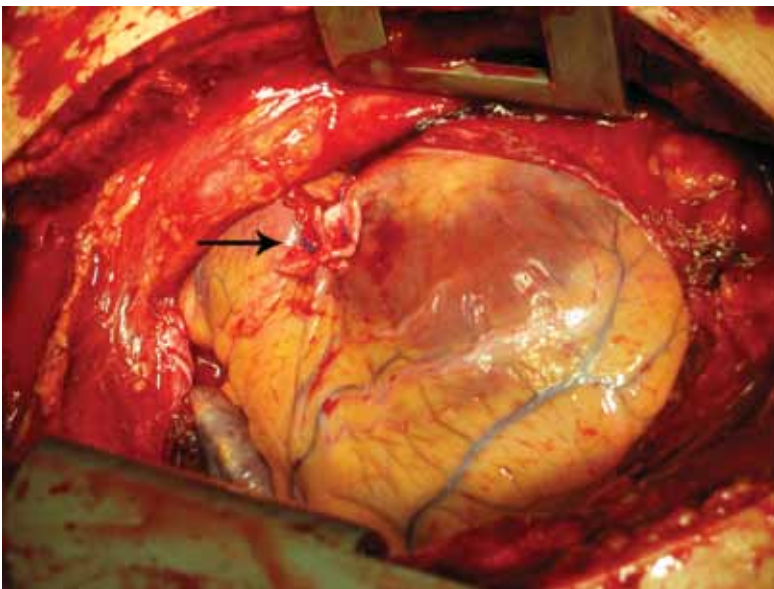
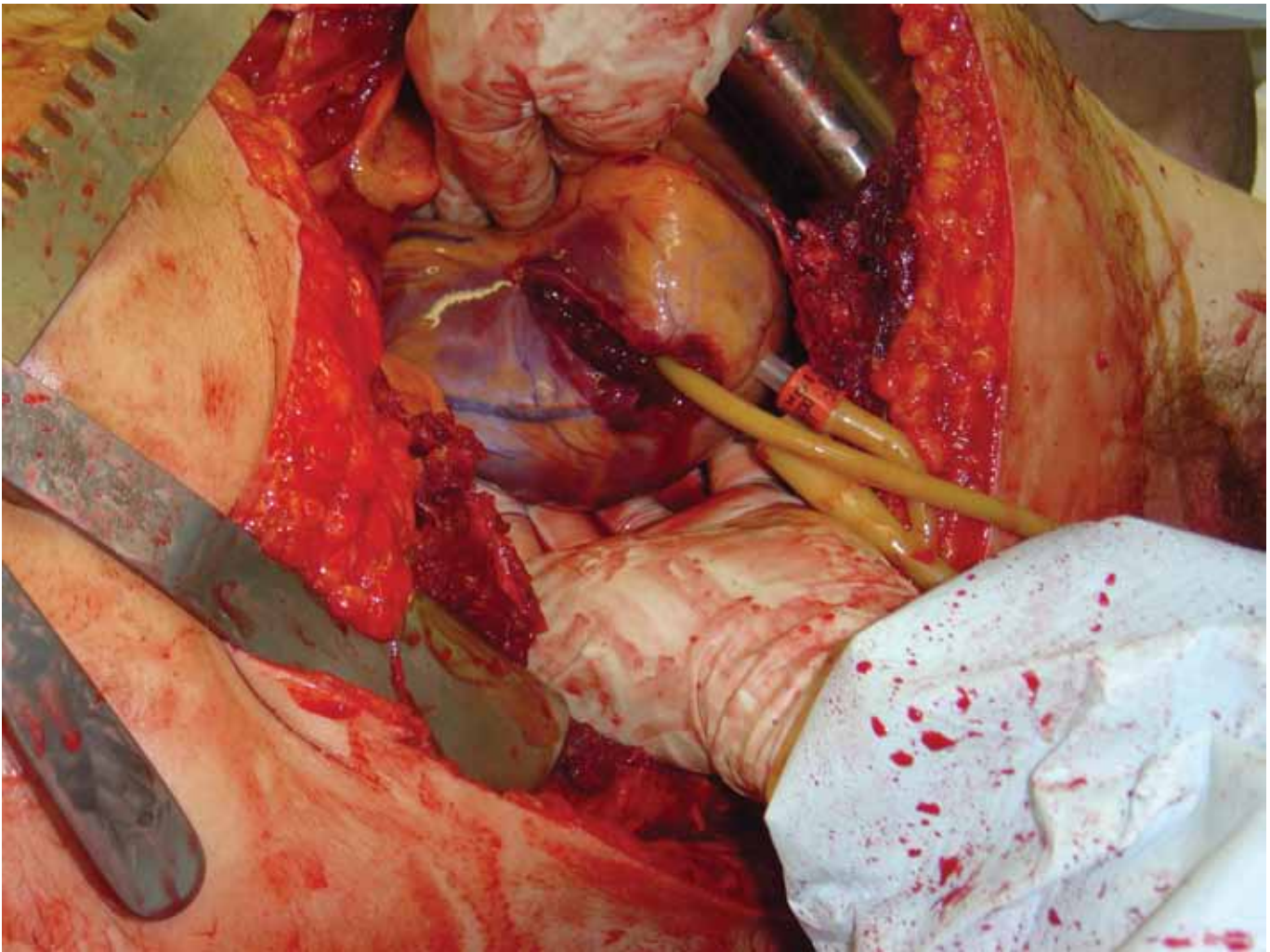


Figure 10. Bleeding from penetrating trauma to the heart may be temporized with digital pressure (occlusion), Foley catheter or Fogarty balloon tamponade, suture repair, or stapling. When suturing or stapling, it is vital to avoid occlusion of a coronary artery. Images courtesy of J. Christian Fox, MD, University of California, Irvine and the Borden Institute, Office of The Surgeon General, Washington, DC.

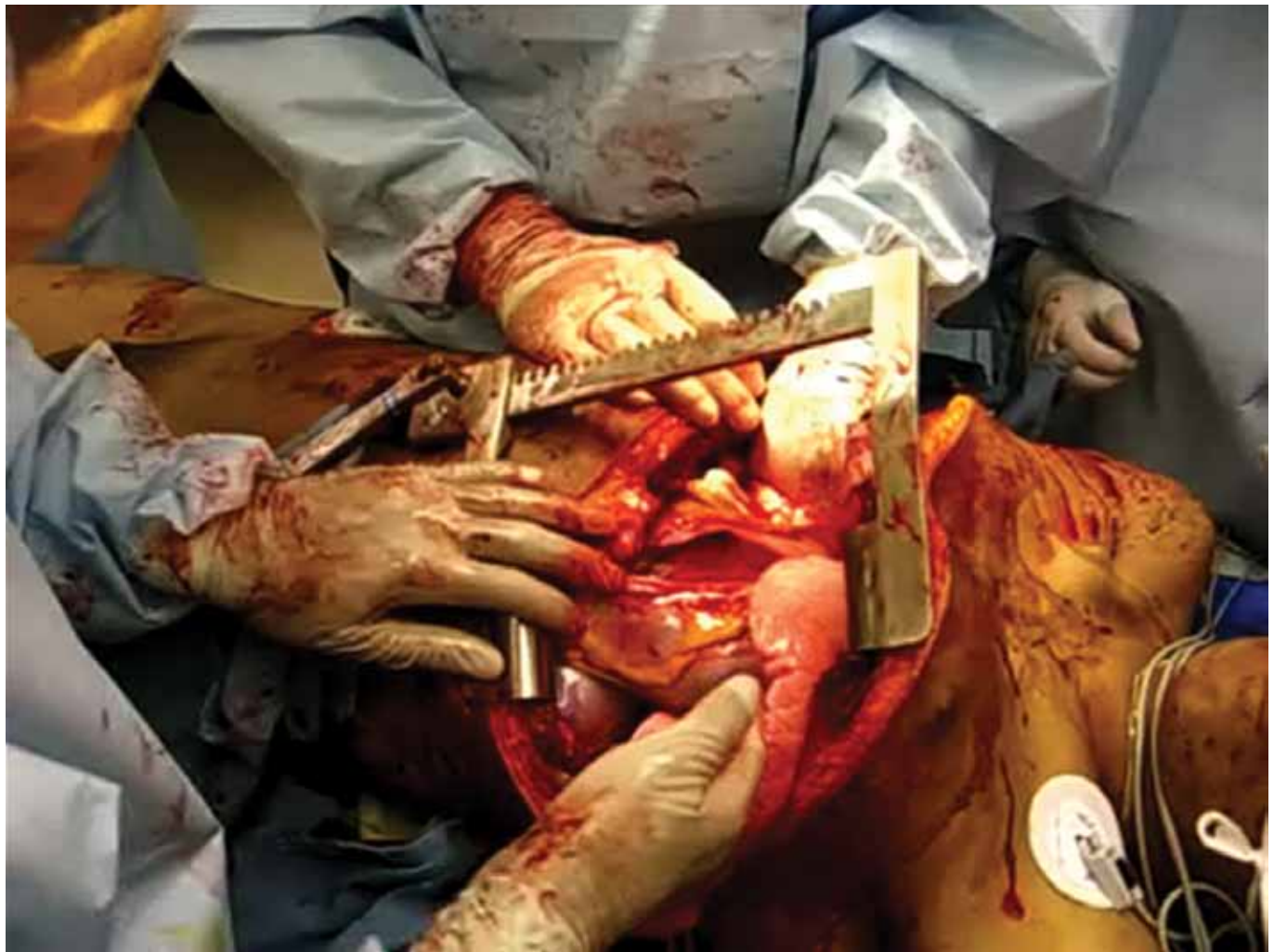

Figure 11. *If additional exposure to the right heart or right hemithorax is required, a left-sided anterolateral thoracotomy can be converted into a clamshell thoracotomy. Image courtesy of J. Christian Fox, MD, University of California, Irvine.*

proximal and distal vascular control and reconstitution of flow principles. Injuries to the aorta require repair. Lateral aortorrhaphy or primary tension-free repair are preferable, although in the authors' experience, in extreme circumstances the aorta can be transiently shunted with a large-bore chest tube tied into position above and below the injury site with large suture or umbilical tape.

Control of the descending thoracic aorta is easily obtainable through a left-sided anterolateral thoracotomy. Exposure of the proximal left subclavian and proximal left common carotid artery is limited from a true left-sided anterolateral thoracotomy and would be better obtained via a more traditional posterolateral thoracotomy. A “book” or “trapdoor” incision would provide better exposure of a long segment of the left common carotid and left subclavian artery. This surgical approach is seldom used due to lack of familiarity, as well as complications related to stretch on the brachial plexus and upper posterior costal junctions, resulting in neurologic and upper back pain syndromes.⁴¹ It should be only used when control and repair are absolutely necessary. A better approach to specifically control subclavian artery hemorrhage would be an anterolateral thoracotomy via a third intercostal space incision combined with a separate infraclavicular incision for definitive repair.⁴² Visualization of the subclavian artery and vein, particularly more distally, can be facilitated by resection of the clavicle.

Injuries to the aortic arch vessels and definitive repairs usually require a median sternotomy. As a general principle, dissection into mediastinal hematomas can be disorienting, so it is often useful to open the pericardium and trace vessels upward. The left innominate vein can be divided in order to identify the innominate artery, and the dissection can then continue cephalad. Due to relatively large vessel caliber, the best management method for injuries to thoracic outlet arteries is usually bypass using a synthetic conduit. However, in a damage control scenario, this may not be possible. In extreme circumstances, most aortic arch arteries can be singly ligated since the vigorous collateral flow of the cervical and thoracoacromial region will usually sustain acceptable perfusion. Ligation of cervical vessels carries the risk of stroke, and subclavian and innominate artery ligations carry the risk of limb ischemia. Except for the superior vena cava, injuries to the thoracic venous system can be repaired with lateral venorrhaphy or ligated. Injuries to the superior vena cava should be repaired.

In extreme circumstances, most aortic arch arteries can be singly ligated since the collateral flow of the cervical and thoracoacromial region will usually sustain acceptable perfusion.

Pulmonary and Tracheobronchial Injuries

Pulmonary and tracheobronchial damage control procedures are performed to control hemorrhage or air leak. With respect to pulmonary injury, the three main damage control procedures are: (1) nonanatomic pulmonary resection; (2) pulmonary tractotomy; and (3) pneumonectomy (Figs. 12 and 13). Nonanatomic resections using a GIA™ or TA™ stapler are generally preferred for peripheral injuries with ongoing hemorrhage or air leak. The advantage of the nonanatomic resection over anatomic resection is the reduction in time associated with not having to develop formal lobar surgical planes. However, if deeper bleeding persists after pneumorrhaphy or nonanatomic pulmonary resection, this must be addressed with further exposure and repair or ligation. When this occurs or when there is profuse hemorrhage from deeper within

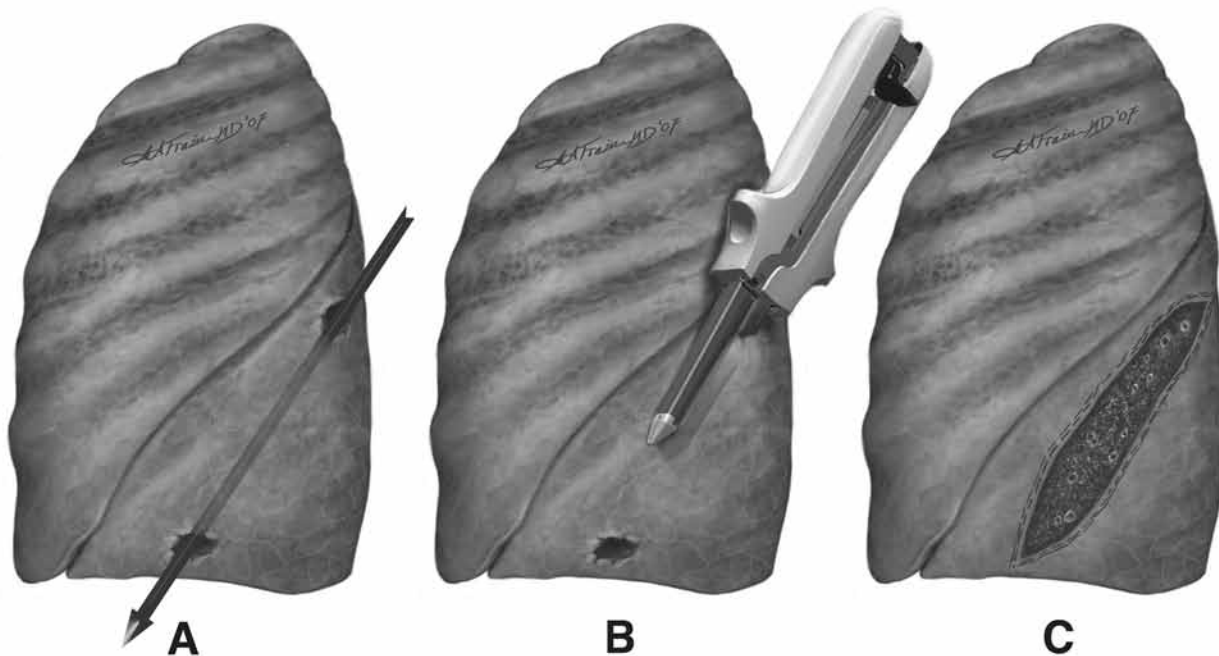


Figure 12. *Illustration of pulmonary tractotomy. Image courtesy of the Borden Institute, Office of The Surgeon General, Washington, DC. Illustrator: Aletta Frazier, MD.*

the lung parenchyma from penetrating injury, a pulmonary tractotomy can be performed. This procedure involves placing two long vascular clamps through the pulmonary wound tract, clamping them, and incising between the two. The lung edges can then be stapled with a TA™ stapler. Alternatively, a GIA™ stapler can be advanced through the tract and fired, creating a linear passage to the source of hemorrhage. The focus of hemorrhage will lie at the base of the tract and can be sutured with 4-0 or 5-0 vascular suture.

Pulmonary and tracheobronchial damage control procedures that are performed to control hemorrhage or air leak may include: (1) nonanatomic pulmonary resection; (2) pulmonary tractotomy; and (3) pneumonectomy.

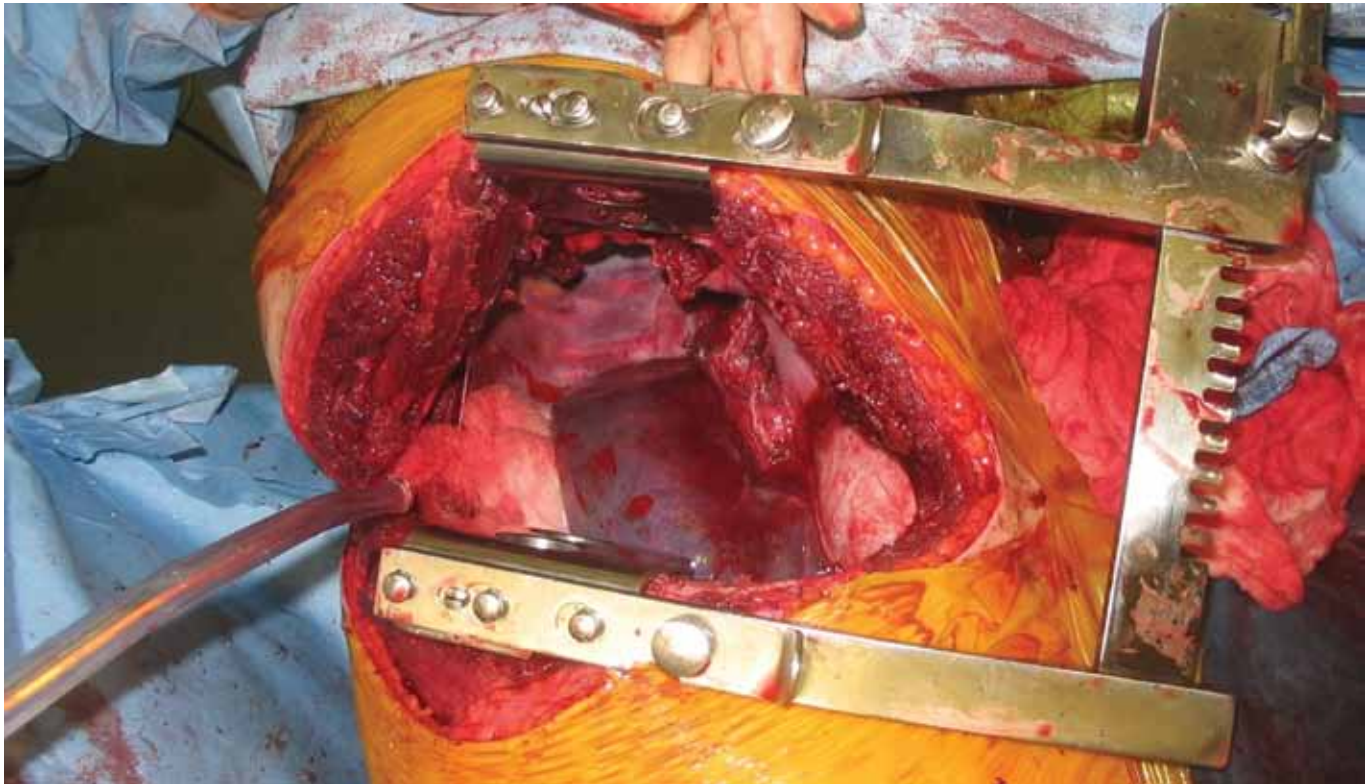
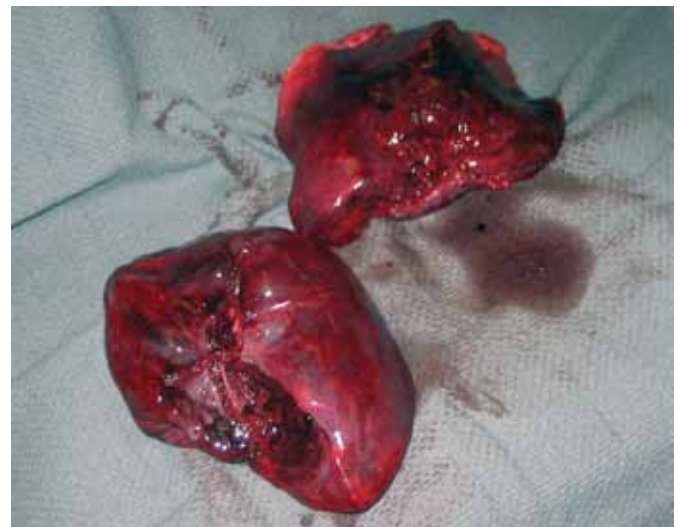

Figure 13. (Above) *Patient with penetrating right chest injury from a mortar round. A posterolateral thoracotomy was performed, demonstrating intact lower lobe and stapled upper and middle lobe structures. (Right) Resected right upper and middle lobes of the lung. Images courtesy of the Borden Institute, Office of The Surgeon General, Washington, DC.*



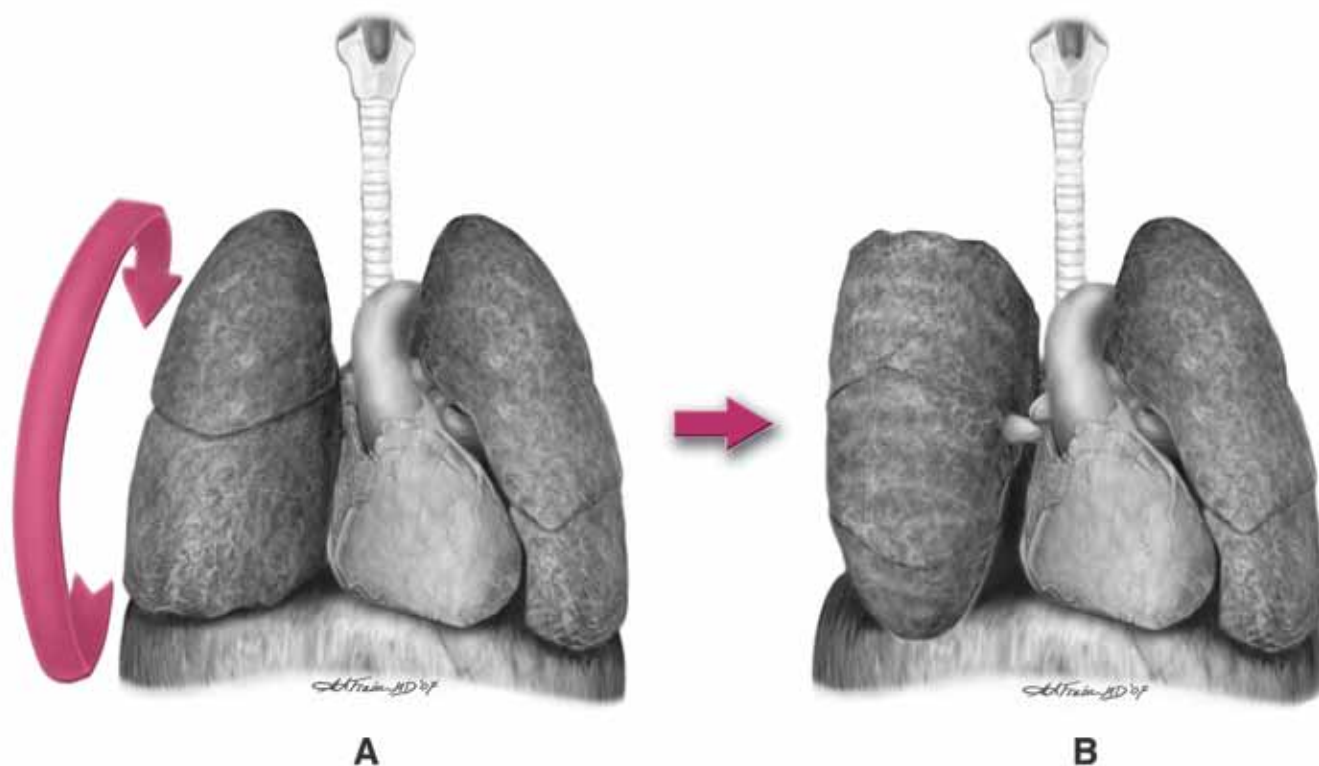


Figure 14. *Hilar clamping or “hilar twist.” Image courtesy of the Borden Institute, Office of The Surgeon General, Washington, DC. Illustrator: Aletta Frazier, MD.*

In patients with global or hilar parenchymal lung injury, pneumonectomy is an option of last resort. There is a stepwise increase in mortality with more extensive lung resections that is independent of injury severity.⁴³ The mortality of trauma patients undergoing pneumonectomy is over 50 percent.^{43,44,45} Large air leaks from the bronchial tree or major pulmonary hemorrhage can temporarily be controlled by incising the inferior pulmonary ligament and clamping the pulmonary hilum, or by twisting the lung 180 degrees around its hilar axis (Figs. 14 and 15).⁴⁶ Should pneumonectomy or hilar clamping be necessary, the hilum of the lung should be clamped slowly. This will give the other lung a chance to accommodate, and volume resuscitation should be minimized to avoid acute right heart failure, which inevitably occurs. Ligation of hilar vascular and bronchial structures should be performed by isolation, stapling, or suture ligation and buttressed with pleural or other easily mobile soft-tissue such as intercostal muscle.

Esophageal Injury

The incidence of esophageal injuries is low, and injuries are most often the result of penetrating trauma.⁴⁷ The cervical esophagus represents the most common site of injury. Injuries involving less than 50 percent of the circumference of the esophagus can be closed in layers after debridement. Esophageal repairs need to be buttressed with pleural or intercostal muscles due to the tenuous nature of these types of repairs. If the injury encompasses more than 50 percent of the circumference of the esophagus, or the patient remains physiologically compromised, the esophageal injury is locally resected and the esophagus is stapled in discontinuity. The proximal esophagus should be drained via nasogastric tube. Consideration should be given to concurrently performing gastric decompression (i.e., gastrostomy tube) and feeding jejunostomy; however, both could be performed during definitive repair. The hemithorax must be widely drained with

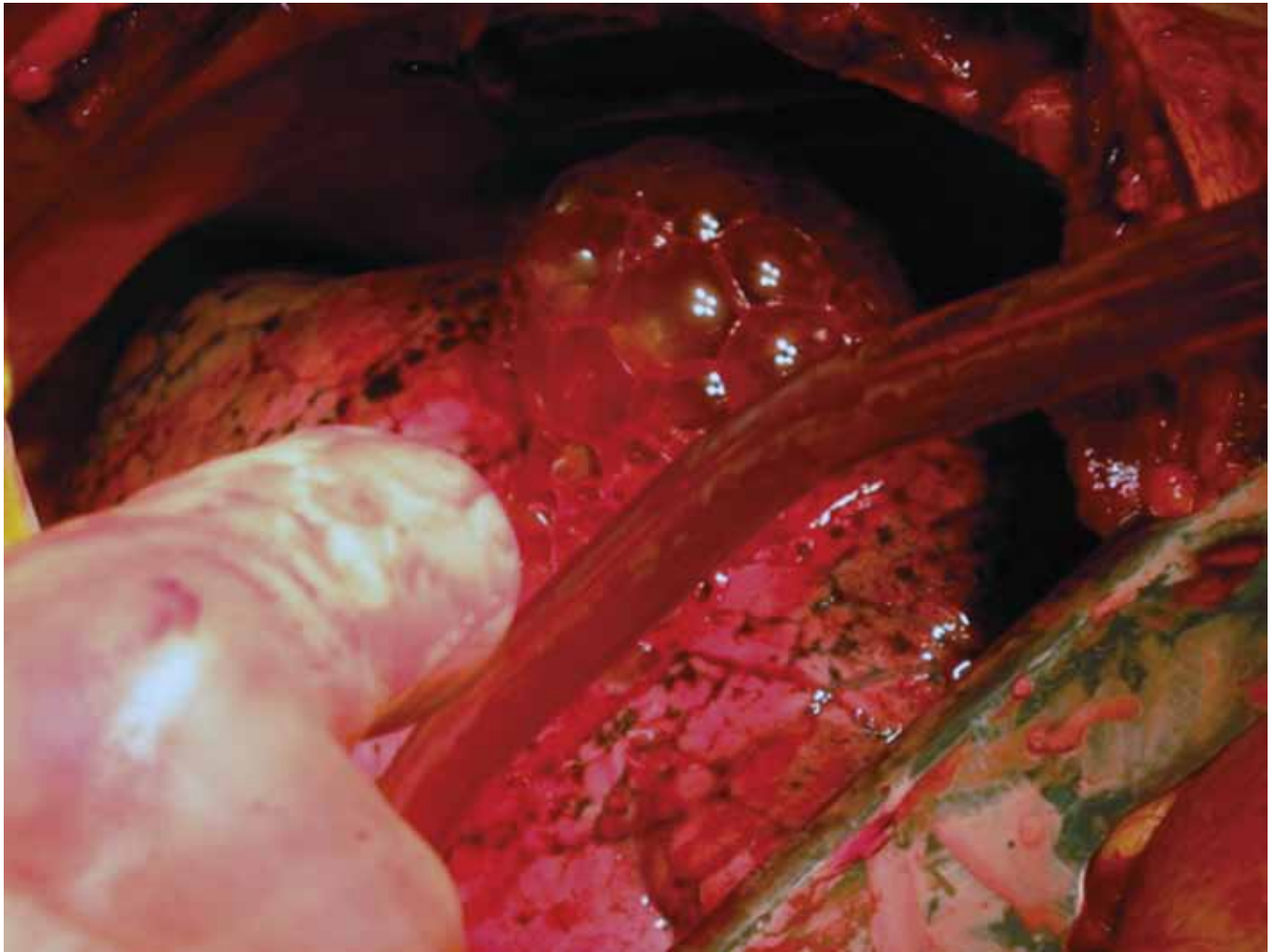


Figure 15. A patient with penetrating injuries to the right chest. This image demonstrates the right lung after it has been mobilized and twisted around the hilum to achieve hemorrhage control. Image courtesy of the Borden Institute, Office of The Surgeon General, Washington, DC.

a large-bore (32 French or larger) chest tube. Subsequently, definitive restitution of continuity or cervical esophagostomy can be performed once the patient has stabilized.^{48,49}

The incidence of esophageal injuries is low. Esophageal injuries are most often the result of penetrating trauma, and the cervical esophagus represents the most common site of injury.

Neck Injury Damage Control

Vascular injury is noted in 20 percent of cases of penetrating neck trauma, and exsanguinating hemorrhage is the primary cause of death.⁵⁰ The neck is traditionally divided into three zones to aid decision making and management (Fig. 16). A more detailed discussion of damage control surgery in the neck is provided in the Maxillofacial and Neck Trauma chapter.

Zone II neck injuries with hard signs of vascular injury require immediate exploration (Fig. 17). These hard

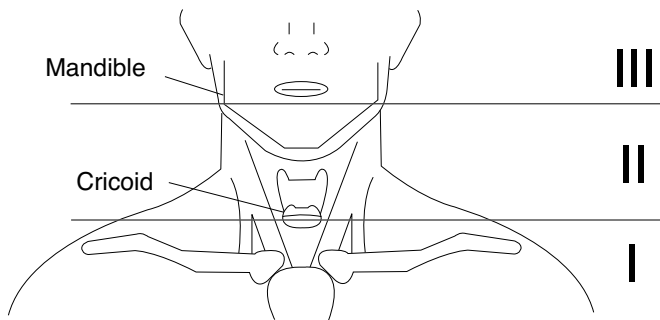


Figure 16. The neck is commonly divided into three anatomic zones for purposes of initial assessment and management.

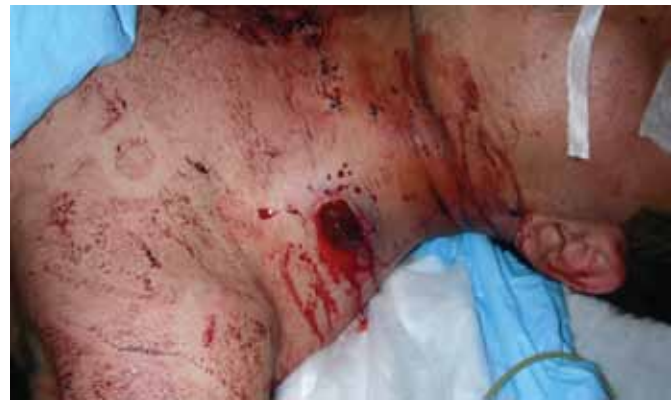

Figure 17. Penetrating neck trauma with expanding hematoma mandating immediate surgical exploration. Image courtesy of David B. Powers, DMD, MD, COL, US Air Force.

signs include uncontrollable hemorrhage, rapidly expanding hematoma, pulsatile hemorrhage, palpable thrill or audible bruit, or signs of neurovascular compromise (Table 1).^{51,52} As a general principle, the groin and upper thigh should be prepped to allow for saphenous vein interposition graft harvesting prior to vascular exploration. A standard neck incision is made from the mastoid to the sternal notch on the anterior border of the sternocleidomastoid muscle. The facial vein should be identified and ligated and the internal jugular vein retracted posteriorly using a self-retaining retractor. Injuries to the internal jugular vein can be repaired with lateral venorrhaphy or ligated (Fig. 18). After repairing vascular injuries in this zone, one must have a high index of suspicion and assess for esophageal and tracheal injuries.

HARD SIGNS MANDATING IMMEDIATE EXPLORATION OF THE NECK	
<ul style="list-style-type: none"> • Uncontrollable hemorrhage • Rapidly expanding hematoma • Pulsatile hemorrhage • Palpable thrill or audible bruit • Focal neurologic compromise • Absent or decreased pulses in the neck or arms 	

Table 1. Hard signs mandating immediate exploration of the neck.

After repairing vascular injuries in Zone II, one must have a high index of suspicion and assess for esophageal and tracheal injuries.

The common carotid artery can be explored from the thoracic inlet to the base of the skull. Suspected proximal (Zone I) carotid injury requires partial sternotomy for proximal vascular control. Injuries to the common or internal carotid arteries may be repaired using lateral arteriorrhaphy, patch angioplasty, end-to-end anastomosis, or bypass.⁵³ If the patient is in extremis, the common or internal carotid vessels could be ligated. This approach leads to dismal outcomes, with stroke rates exceeding 20 percent and mortality approaching 50 percent.⁵⁴ Recent studies suggest patients fare better when the internal carotid artery is repaired rather than ligated.⁵³ Therefore, it is advisable to repair the injury as long as the patient remains

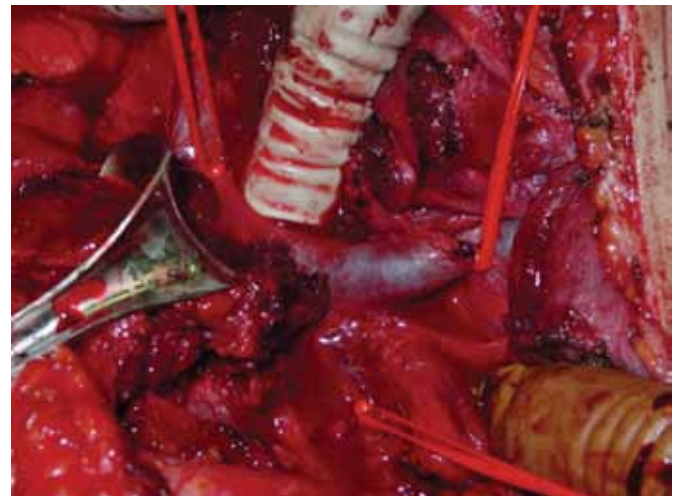
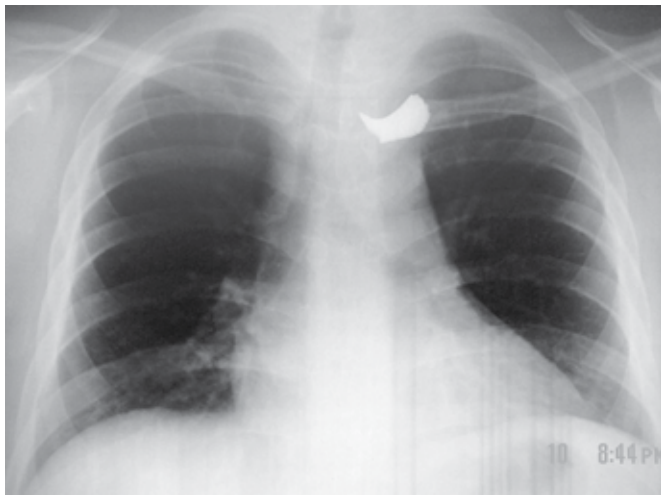
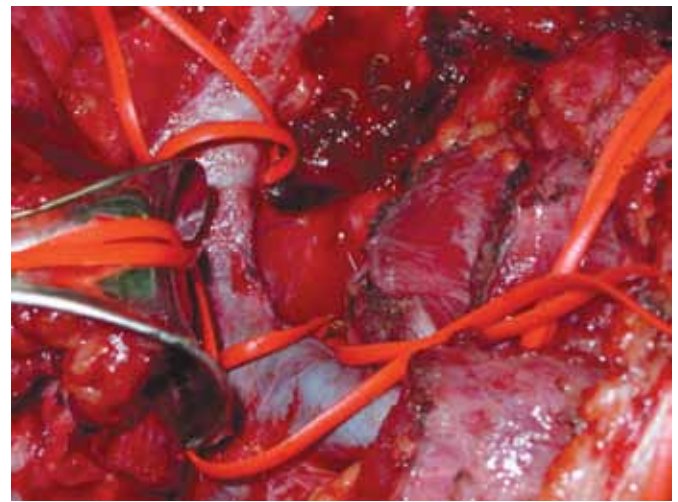


Figure 18. *Penetrating neck injury (initial point of entry was anatomic-right side of neck; Zone II). (Top Left) Preoperative radiograph demonstrates a fragment from a 40-millimeter grenade overlying the left sternoclavicular joint. (Top Right) Upon median sternotomy and exploration, the fragment was noted in the innominate vein, digital pressure was applied, and vascular control was obtained. (Bottom Right) A venorrhaphy was performed. After repairing vascular injuries in this zone, one must have a high index of suspicion and assess for esophageal and tracheal injuries. Images courtesy of the Borden Institute, Office of The Surgeon General, Washington DC.*



clinically stable. An alternative approach to ligation would be placement of a temporary shunt between the two ends tied in place with 2-0 silk suture.

In the case of a distal (Zone III) internal carotid artery injury that is too high for reconstruction, ligation is appropriate if the distal end can be ligated. In the case of a distal carotid lesion that is within the skull base, a size 3 Fogarty embolectomy catheter can be inserted into the distal end of the internal carotid artery, placing two clips just below the balloon to keep it expanded and cutting the shunt to leave the balloon in the internal carotid artery to tamponade it and allowing it to thrombose.⁵³ Lastly, injuries to the external carotid artery may be repaired using standard techniques or ligated. Transposition of the external carotid artery to the internal carotid artery is particularly useful when the internal carotid artery cannot be primarily repaired. This technique is used as an alternate to ligation.⁵⁵

Transposition of the external carotid artery to the internal carotid artery is particularly useful when the internal carotid artery cannot be primarily repaired.

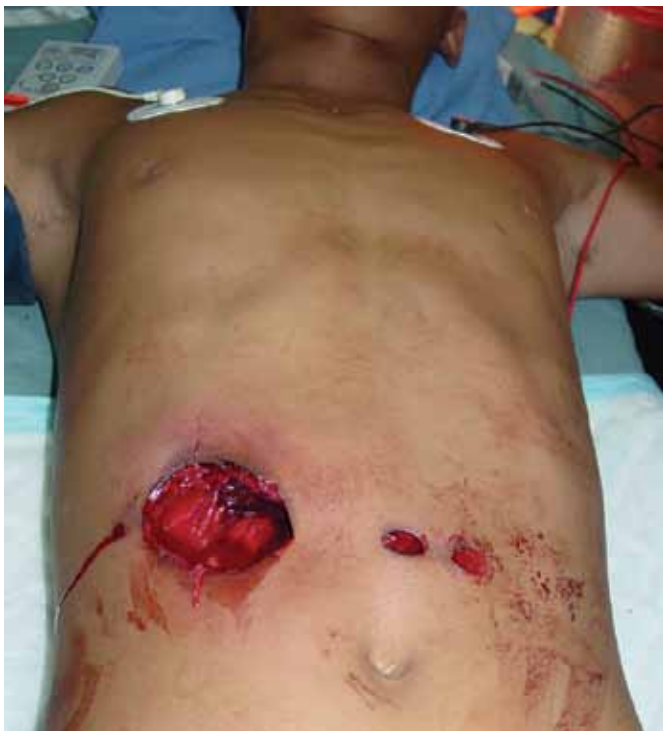
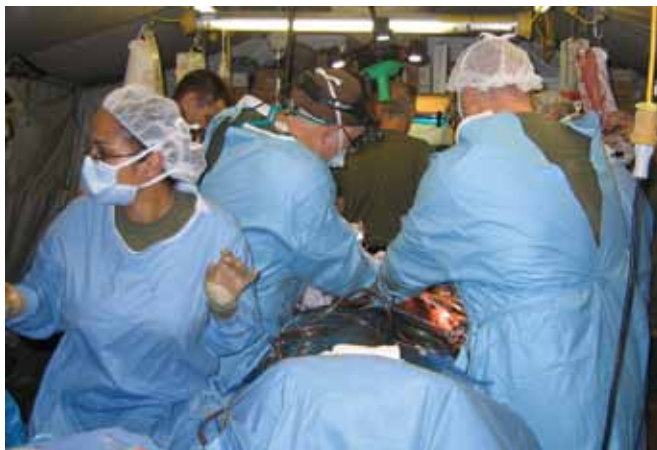
Figure 19. (Left) *Abdominal damage control surgery is indicated for abdominal injury with severe physiologic derangement. This patient was injured by an M16 round. Image courtesy of the Borden Institute, Office of The Surgeon General, Washington, DC.*

Figure 20. (Below) *Resource constraints in a battlefield environment (e.g., mass-casualty-incident) may mandate an abbreviated operation. Image courtesy of Harold Bohman, MD, CAPT, MC, US Navy.*



Abdominal Injury Damage Control

The battlefield environment presents two discrete conditions in which damage control abdominal surgery is indicated: first and foremost is abdominal injury with severe physiologic derangement and second are the resource constraints of the austere environment. Examples of the former include casualties with penetrating abdominal injury with shock, high-velocity gunshot or abdominal penetrating injury from a secondary blast injury mechanism, or multisystem trauma with major abdominal injury (Fig. 19). An example of the latter is a mass-casualty-incident; each casualty presents with discrete surgical requirements that temporarily overwhelm the capacity of the system. This necessitates performing abbreviated operations (i.e., not definitive repairs) to accommodate all patients in an expedient manner (Fig. 20). In a recent military analysis, the presence of shock and penetrating torso injury was an independent risk factor for the requirement for damage control resuscitation and expedited operative intervention.^{29,56}

Damage Control Laparotomy

Early anticipation of the necessity for damage control resuscitation and surgery improves outcomes in this severely injured population.

Adequate patient preparation is essential. Once in the operating room, the patient is placed in the supine position and prepped from chest to groin. A generous midline incision is made and carried down through the midline fascia. Once the peritoneum is opened, the aorta may be manually compressed at the hiatus of the diaphragm if severe arterial hemorrhage is noted, and intraperitoneal blood can be quickly evacuated. This can be rapidly accomplished by pressing the sides of the abdomen together, expressing most of the blood and clot out onto the drapes, and subsequently packing any areas of ongoing hemorrhage. If control

of hemorrhage is adequate, time is given to the anesthesiologist to restore intravascular volume in response to any decrease in blood pressure caused by releasing the peritoneal tamponade.

In patients with persistent hemorrhage from abdominal great vessel injury not amenable to packing, priority is given to inflow and outflow control of the injured vessel. Temporary aortic control can be gained at the diaphragmatic hiatus by posterior compression with a Richardson retractor or clamping of the aorta, which can be accessed through the gastrohepatic ligament. Likewise, control of the aorta can be obtained through the left chest via left-sided anterolateral thoracotomy if more proximal control is necessary. Once aortic inflow is controlled, exposure is the key to abdominal vascular control. The entire abdominal aorta and the common iliac vessels can be visualized through a left medial visceral rotation. Conversely, a right medial visceral rotation with a Catell-Braasch maneuver will allow visualization of the infrarenal inferior vena cava and the aorta up to the level of the superior mesenteric artery axis (Fig. 21). Adding a Kocher maneuver will expose the inferior vena cava to the subhepatic level as well as fully mobilize the duodenum and head of the pancreas.

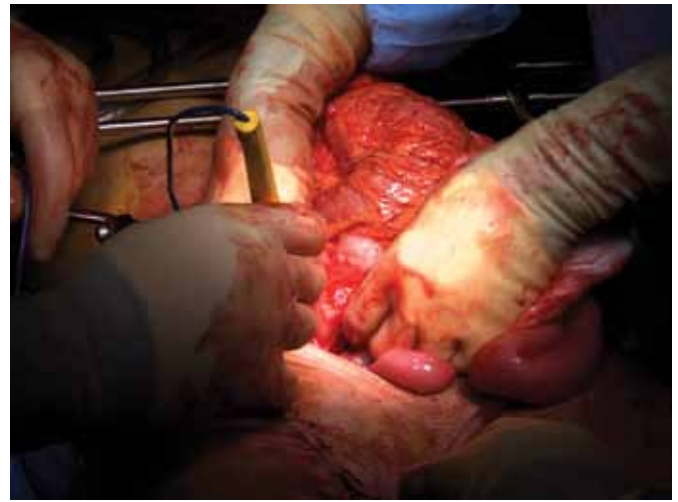


Figure 21. A right medial visceral rotation with a Catell-Braasch maneuver will allow visualization of the infrarenal inferior vena cava and the aorta up to the level of the superior mesenteric artery axis.

In patients with persistent hemorrhage from abdominal great vessel injury not amenable to packing, priority is given to inflow and outflow control of the injured vessel.

Once the injury is identified, a damage control therapeutic plan can be better developed. With injuries to the suprarenal aorta, lateral arteriorrhaphy should be strongly considered since protracted clamping of the aorta at this level during repair will result in visceral ischemia and exacerbation of physiologic anomalies.⁵⁷ For an infrarenal aortic injury, an attempt should be made at local repair, and at this point aortic clamping should be reassessed and either removed or repositioned to the most distal portion of the aorta. If not feasible, an interposition tube graft is a better option than patch angioplasty. It should be remembered that in young adults, the aorta is quite small and rarely will accommodate a graft larger than 16 millimeters (mm). Repair in young or thin patients should be buttressed with omentum due to the thin retroperitoneum. In dire circumstances, a temporary chest tube shunt can be considered. The iliac arteries can likewise be shunted in the damage control setting. In select circumstances, the surgeon may need to transect the overlying right common iliac artery to expose and control an injury to the confluence of the common iliac veins for hemorrhage control.

With injuries to the suprarenal aorta, lateral arteriorrhaphy should be strongly considered since protracted clamping of the aorta at this level during repair will result in visceral ischemia, and exacerbation of physiologic anomalies. For an infrarenal aortic injury, an attempt should be made at local repair.

Retrohepatic Hematoma

A retrohepatic hematoma controlled with packing should not be explored. If vigorous hemorrhage is emanating from the posterior aspect of the liver, a Pringle maneuver should be performed to control hepatic arterioportal vascular inflow. If this maneuver controls the hemorrhage, then the hemorrhagic source is intrahepatic. If this maneuver does not control the hemorrhage, then there is a high likelihood that the patient has a retrohepatic vena cava injury.⁵⁸ Upon identifying a retrohepatic vena cava injury that is not amenable to tamponade by packing, an immediate decision needs to be made to approach the injury via total hepatic vascular isolation. Anesthesia must be forewarned that the isolation procedure will restrict preload from the lower half of the body so large-bore upper central venous access is mandatory. The hepatic arterioportal inflow occlusion is maintained. Then, control of the inferior vena cava above the renal veins is developed.⁵⁹ At this point, control of the suprahepatic inferior vena cava is obtained in order to minimize manipulation of the retrohepatic hematoma. This can be done most easily by gaining control within the pericardium. Pericardial access can be developed through the diaphragm or via median sternotomy and pericardiectomy.

A retrohepatic hematoma controlled with packing should not be explored.

An alternate approach to the suprahepatic inferior vena cava would be to extend the abdominal incision via a right thoracoabdominal incision, which would also offer better exposure to the right and superior portions of the liver. In either approach, it is important to mobilize the right triangular ligament of the liver first. Once the injury is identified, it can be repaired using monofilament suture. Penetrating injuries with suspicion of injury to the subhepatic inferior vena cava require exploration. These juxtarenal caval injuries also require repair. If hemorrhage stops with repair of the anterior hole, it is not necessary and even may be counterproductive to expose the posterior wall of the vena cava looking for a posterior hole in the damage control setting. Infrarenal inferior vena cava injuries can be ligated if patient acuity dictates. Infrarenal inferior vena cava ligation is fairly well tolerated in younger patients.⁶⁰ However, ligation of the suprarenal inferior vena cava is usually associated with renal failure and massive lower extremity edema.^{61,62}

Infrarenal inferior vena cava injuries can be ligated if patient acuity dictates. However, ligation of the suprarenal inferior vena cava is usually associated with renal failure and massive lower extremity edema.

Perihepatic Vascular Injury

Perihepatic vascular injuries require special consideration. Once again, packing is the damage control mainstay, provided it controls hemorrhage. Hepatic artery ligation may be useful in controlling hemorrhage if packing is not successful.^{63,64} The supraduodenal portal vein may be ligated for damage control. When both the portal vein and hepatic artery are damaged, at least one of the vessels must be salvaged.

Hepatic Parenchymal Injury

Bleeding from within the hepatic parenchyma can often be controlled initially with manual compression, with placement of hands on either side of the major laceration(s) and pressing together. This will allow the anesthesia team to restore intravascular volume via blood component transfusions before proceeding. The decision at this point should be whether packing (superiorly, anteriorly, and posteriorly) is adequate to maintain hemostasis.

Adjunctive measures like topical hemostatic agents (e.g., fibrin sealants) in conjunction with packing may be useful with large hepatic lacerations. Topical hemostatic agents may not be readily accessible and are often time-consuming to prepare. Direct suturing is one of the oldest techniques to control deep parenchymal bleeding using large blunt-tipped 0-chromic sutures.⁶⁵ The sutures may be placed in a continuous or mattress configuration. Suturing should be limited to lacerations less than three centimeters in size to prevent blind suturing leading to significant bile duct injuries.^{66,67} More complex lacerations often involve larger hepatic artery or portal branch vessels, which usually do not respond to packing. Gentle finger fracturing may be used to identify specific bleeding vessels and facilitate ligation.⁶⁸ One must be careful not to create excessive additional parenchymal bleeding using this finger-fracturing technique.

Bleeding from within the hepatic parenchyma can often be initially controlled with manual compression. Suturing should be limited to lacerations less than three centimeters in size, as blind suturing may lead to significant bile duct injuries.

Omental packing has been successfully used for tamponading dead spaces with live-tissue, as well as for achieving hemostasis following hepatic hemorrhage. The omentum is first mobilized from the transverse mesocolon in the avascular plane and then off the greater curvature of the stomach. In general, this technique is superior to most direct techniques of hemorrhage control.^{68,69} In civilian study populations, severe and complex liver lacerations treated with formal hepatic resections are associated with low mortality and liver-related morbidity.⁷⁰ The authors in these studies achieved 9 percent liver-related mortality and 17.8 percent liver-related morbidity with senior surgeon support (often a surgeon specifically from the liver service). A similar level of surgical expertise (i.e., liver specialists) is not available in a combat theater, hence such surgical interventions are generally avoided in a deployed setting.

Pancreatic and Duodenal Injuries

The surgical management of duodenal and pancreatic (particular head region) injuries can be challenging and complex. Pancreatic injuries (other than distal injuries) should be treated with hemorrhage control, modest debridement of devitalized tissue, and wide closed-suction drainage.^{71,72} Placement of a feeding jejunostomy tube, assessment for pancreatic ductal continuity, and further definitive care should be performed at the next rearward level-of-care. Pancreatic injuries distal to the superior mesenteric artery can be managed with distal pancreatectomy and closed-suction drainage.⁷³

Pancreatic injuries (other than distal injuries) should be treated with hemorrhage control, modest debridement of devitalized tissue, and wide closed-suction drainage. Pancreatic injuries distal to the superior mesenteric artery can be managed with distal pancreatectomy and closed-suction drainage.

Duodenal injuries can be primarily repaired when there is no risk of luminal compromise.⁷¹ The duodenum should be debrided and closed transversely if the injury involves less than 50 percent of the circumference of the duodenal wall (Fig. 22). If tissue destruction is extensive, the repair will necessitate pyloric exclusion with triple-tube placement: gastrostomy tube, retrograde jejunostomy (to decompress the duodenum), and antegrade feeding jejunostomy.⁷⁴ With complete duodenal transection, it would be best to perform closure of the proximal and distal duodenum with definitive repair at the next rearward level-of-care with either Roux-en-Y jejunostomy or duodenojejunostomy.⁷⁵ In uncommon cases of destructive combined injuries to the duodenum and pancreatic head, a pancreaticoduodenectomy (Whipple procedure) is a surgical option.⁷² This should only be performed by experienced personnel in well-resourced facilities.

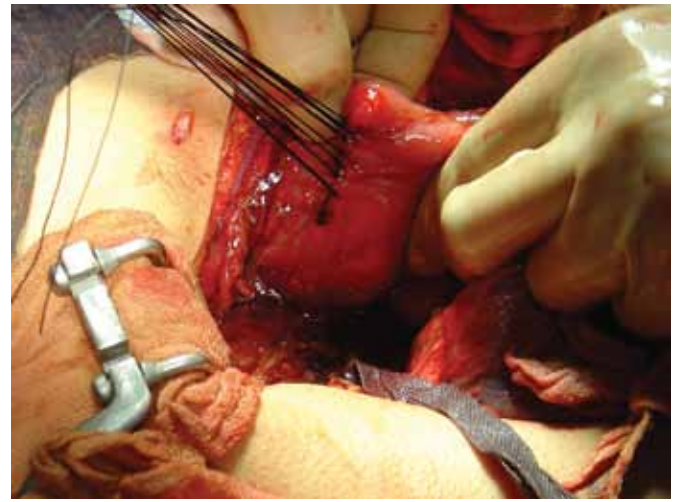
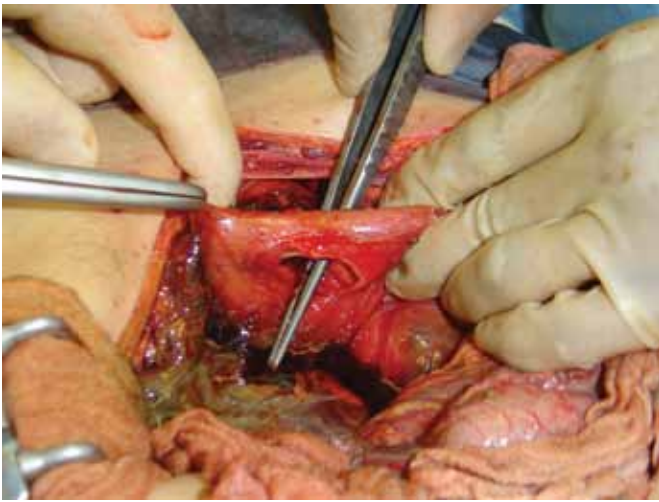
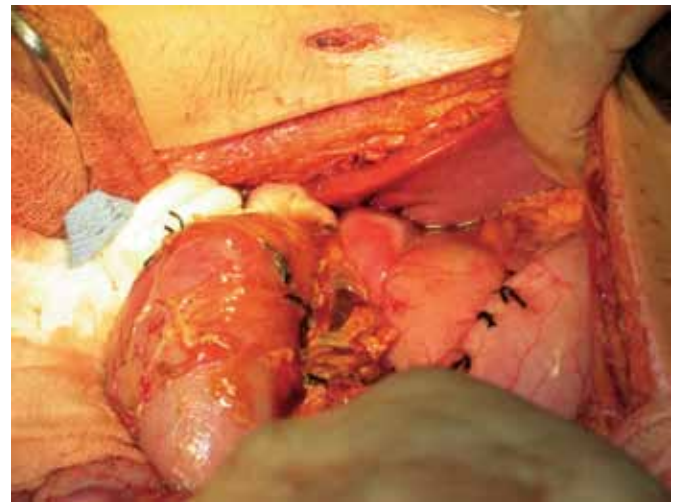


Figure 22. Duodenal injuries can be primarily repaired when there is no risk of luminal compromise. (Top Left) Kocher maneuver demonstrating through-and-through injury to the duodenum. (Top Right) Repair of injury with two-layer closure. (Bottom Right) Closed duodenum. Images courtesy of the Borden Institute, Office of The Surgeon General, Washington, DC.



A pancreaticoduodenectomy should not be performed in an austere environment. In a damage control surgery setting, destructive injury to the pancreatic head should be treated with drainage.

Renal Injury

Renal injuries will often respond to compressive tamponade in the damage control setting provided that Gerota's fascia has not been violated. Nonexpanding hematomas within Gerota's fascia need not be explored during a damage control celiotomy. Subsequent management can be determined after the patient is stable.^{76,77}

Although the dictum for renal vascular injuries has been proximal and distal control prior to opening Gerota's fascia, vascular control of the renal hilum has been shown to have no impact on nephrectomy rates, transfusion requirements, or blood loss.

Absolute indications for renal exploration during damage control laparotomy include hemodynamic instability, expanding pulsatile renal hematoma, suspected renal pedicle avulsion, and ureteropelvic junction disruption (Figs. 23 and 24).^{76,77} Although the dictum for renal vascular injuries has been proximal and distal control prior to opening Gerota's fascia, vascular control of the renal hilum has been shown to have

Figure 23. (Top Right) *Penetrating renal injury. A nephrectomy should be performed following complex renal injuries in an unstable patient. Image courtesy of the Borden Institute, Office of The Surgeon General, Washington, DC.*

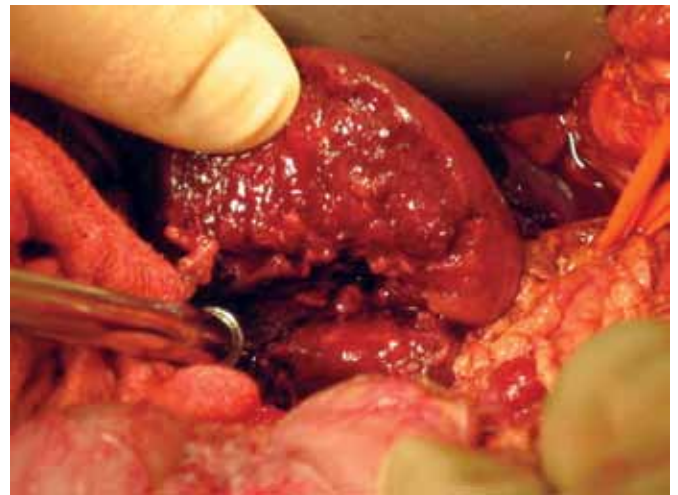
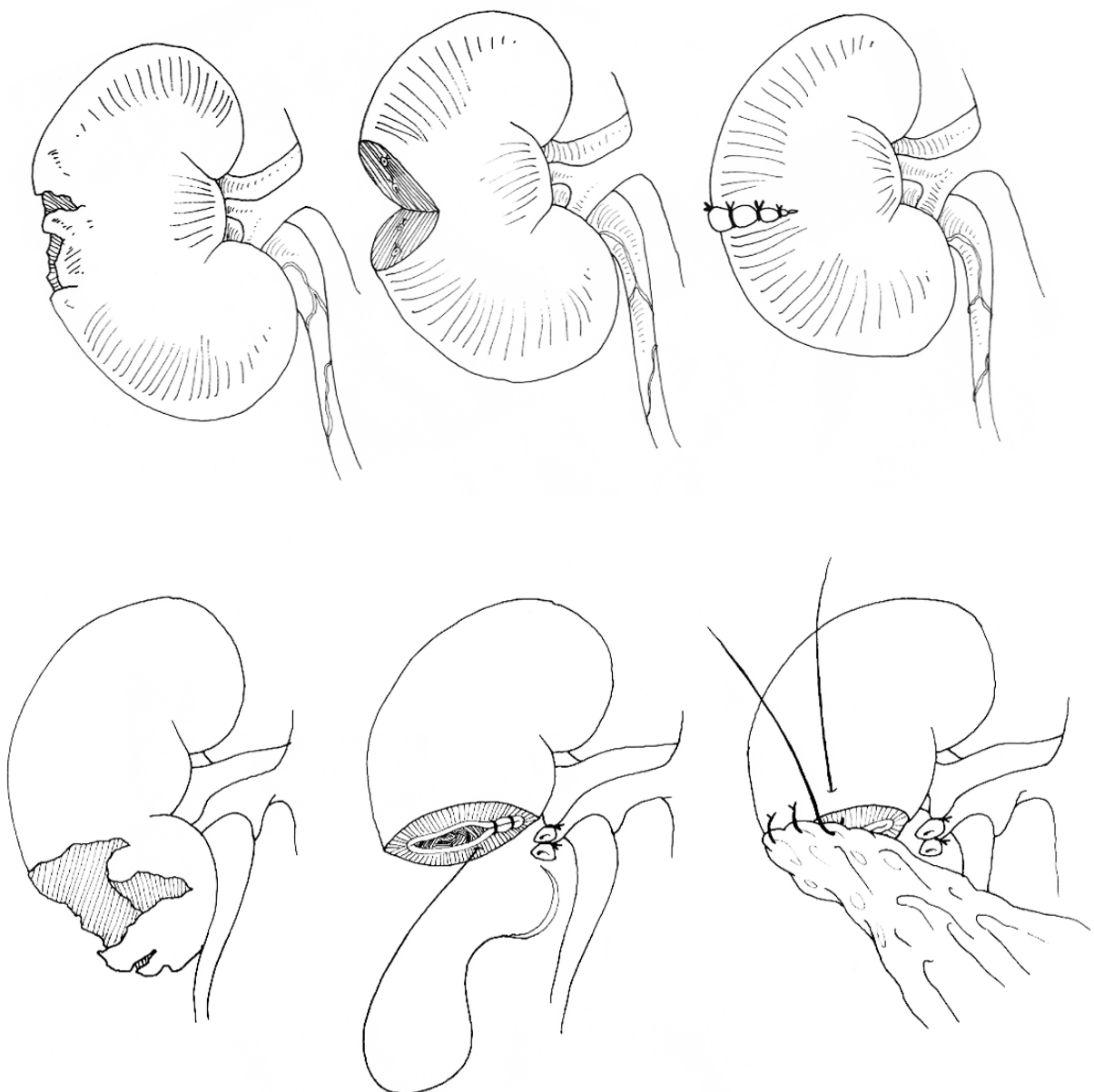


Figure 24. (Middle) *A renal injury may be locally debrided and closed if operative conditions allow or (Bottom) excised in the course of partial nephrectomy. Images courtesy of the Borden Institute, Office of The Surgeon General, Washington, DC. Illustrator: Jessica Shull.*



no impact on nephrectomy rates, transfusion requirements, or blood loss.⁷⁸ In fact, operative time may be increased with such vascular control techniques. Based on this study and the fact that most surgeons are not experienced in renal hilum isolation, it is recommended to forego renal hilar vascular control prior to entering Gerota's fascia. With complex injuries and/or an unstable patient, a nephrectomy should be performed rather than attempting repair. If nephrectomy is considered, the presence of a contralateral kidney should be confirmed.

A nephrectomy should be performed following complex renal injuries in an unstable patient, rather than attempting repair.

Ureteral Injury

Ureteral injuries are uncommon and account for only 1 to 3 percent of penetrating urologic trauma.^{79,80,81} They are often overlooked when not appropriately considered and are more likely to be associated with retroperitoneal hematoma and injuries of the fixed portions of the colon, duodenum, and spleen.^{82,83,84} Management of ureteral injuries depend on location, severity of injury, and hemodynamic stability of the patient.

Primary ureteral repair is not recommended in patients who present in shock or in those with severe colonic injury requiring colostomy.⁸³ Ureteral repair in these patients necessitates exteriorization of the ureter via tube or cutaneous ureterostomy, ureteral ligation and nephrostomy, or even ligation and primary nephrectomy.⁸³ Short proximal and midureteral injuries in hemodynamically stable patients are best managed by end-to-end spatulated anastomosis over a stent. Longer segment injuries may require ureteral exteriorization or ligation with nephrostomy (Fig. 25).⁸²

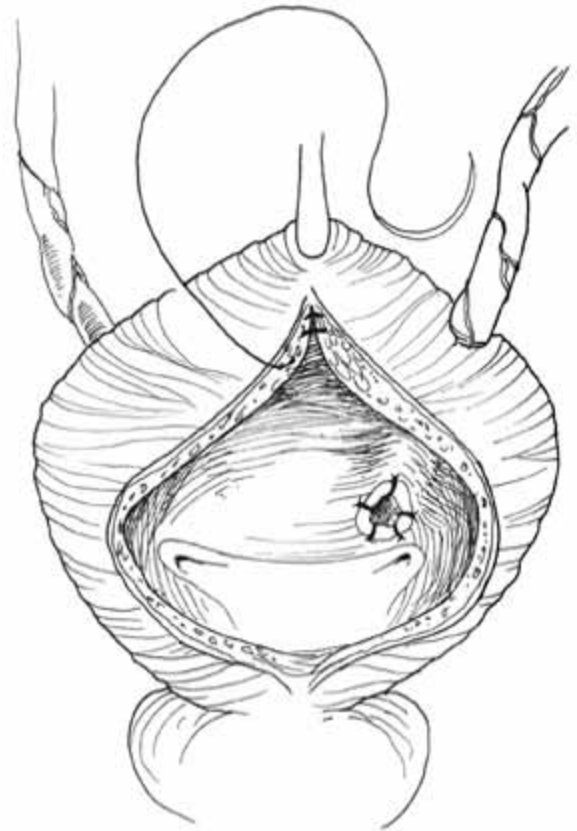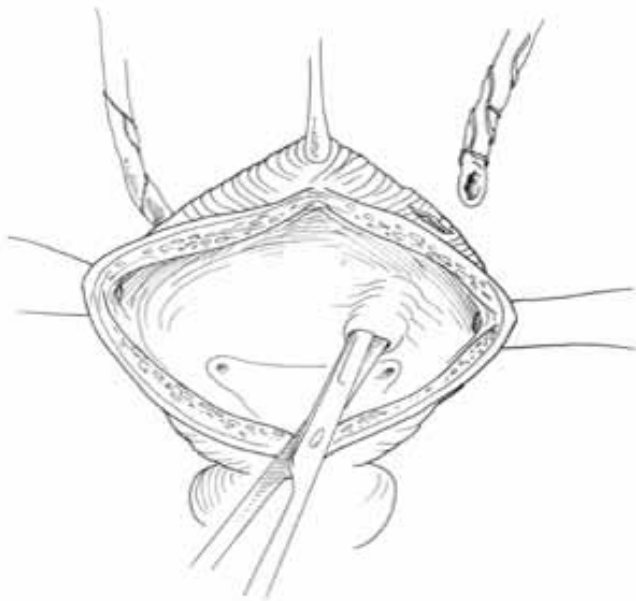
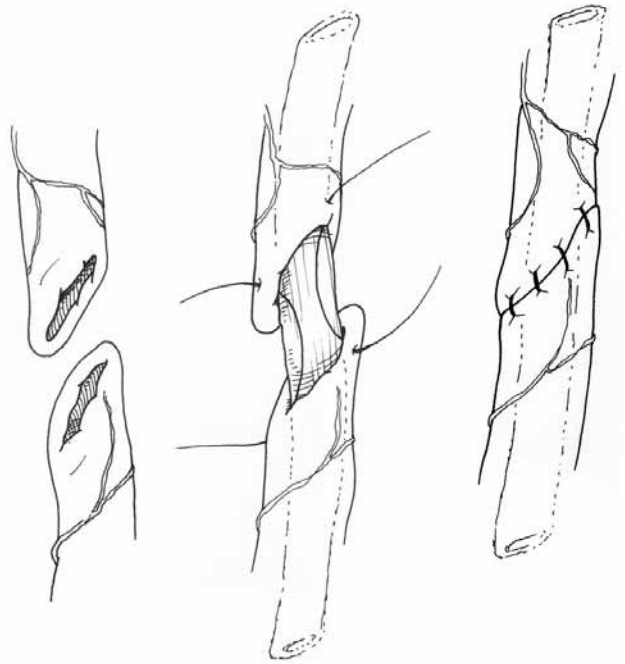
Short ureteral injuries may be managed by anastomosis over a stent, while longer ureteral injuries may require cutaneous ureterostomy with stent placement or ureteral ligation with tube nephrostomy.

Distal ureteral injuries are best managed by ureteroneocystostomy. This is performed by a transverse cystotomy, which elongates the bladder to the location and fixation of the bladder to the psoas fascia. Both maneuvers facilitate the construction of a tension-free anastomosis.⁸² Some have advocated against ureteral reimplantation following distal ureteral injuries associated with rectal injuries due to concerns about wound dehiscence.^{82,83} Successful ureteroneocystostomy following distal ureteral injuries complicated by rectal injuries has been reported.⁸⁵ Meticulous debridement of all necrotic tissues, urinary and fecal diversion, tension-free wound closure with well-vascularized tissue, and adequate drainage and separation of injured sites with well-vascularized tissue (such as omentum) are integral to reducing the incidence of fistulae formation following combined ureteral and rectal injuries.⁸⁵

Splenic Injury

Severely injured combat casualties undergoing damage control surgery with active hemorrhage from the spleen should undergo immediate splenectomy (Fig. 26). Observational management or packing of the spleen following injury is not feasible in most injured US service members. Such patients rapidly undergo aeromedical evacuation and are cared for by multiple careproviders as they are moved to more rearward facilities for definitive care. These factors make observational (nonoperative) management of significant splenic injuries impractical. This approach differs significantly from civilian trauma care where

Figure 25. Ureteral injuries: (Top Right) Short proximal and midureteral injuries in hemodynamically stable patients are best managed by end-to-end spatulated anastomosis over a stent. Longer segment injuries may require ureteral exteriorization or ligation with nephrostomy. (Bottom Left and Bottom Right) Distal ureteral injuries are best managed by ureteroneocystostomy. This is performed by a cystotomy, which elongates the bladder to the location and fixation of the bladder to the psoas fascia. Images courtesy of the Borden Institute, Office of The Surgeon General, Washington, DC. Illustrator: Jessica Shull.



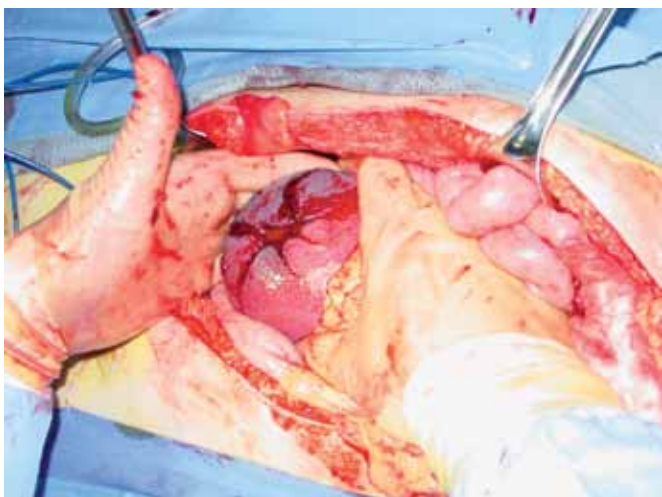


Figure 26. *Splenic laceration due to gunshot wound (GSW). Severely injured combat casualties with active hemorrhage from the spleen should undergo immediate splenectomy. Images courtesy of the Borden Institute, Office of The Surgeon General, Washington, DC.*

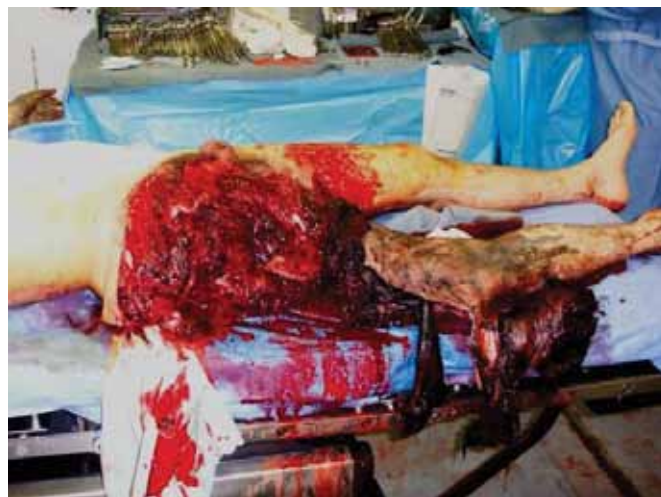

Figure 27. *Large abdominal soft-tissue and retroperitoneal wounds, seen with explosion-related injuries, will have difficult to control hemorrhage. Image courtesy of David Burris, MD, COL, MC, US Army.*

nonoperative management of blunt splenic injury is the treatment of choice for a hemodynamically stable patient, regardless of grade of injury.⁸⁶ Angiographic embolization is a useful adjunct in the nonoperative management of a hemodynamically stable patient with continued bleeding from a splenic injury.⁸⁷ Unfortunately, this interventional technology is not readily available in Level III facilities in Iraq and Afghanistan.

Severely injured combat casualties undergoing damage control surgery with active hemorrhage from the spleen should undergo immediate splenectomy.

Large Soft-Tissue and Retroperitoneal Wounds

Large abdominal soft-tissue and retroperitoneal wounds are not uncommon in the combat environment, particularly with explosion-related injuries (Fig. 27). These wounds present the vexing challenge of controlling a large area of soft-tissue hemorrhage in an often coagulopathic casualty. Temporizing hemorrhage control can be achieved with the combination of topical hemostatic agents such as SURGICEL® NU-KNIT® (Ethicon, Inc.) or GELFOAM® tightly compressed into the wound with laparotomy pads.⁸⁸

Intestinal (Enteric) Injuries

Once control of hemorrhage is obtained, attention is turned to control of contamination. In the damage control laparotomy, all enteric injuries that cannot be repaired by simple suture repair are resected locally, or en bloc if multiple injuries in close proximity are noted (Fig. 28). The bowel is then stapled with a GIA™ stapler and left in discontinuity. No attempt should be made to do a primary enteric anastomosis in the damage control setting.⁸⁹ Likewise, enteric diversion should be postponed and not performed during the initial damage control procedure.⁹⁰ Abdominal wounds associated with colonic injuries (particularly left-sided) need to be monitored closely, and serial local debridement should be strongly considered since these injuries are often complicated by infections.

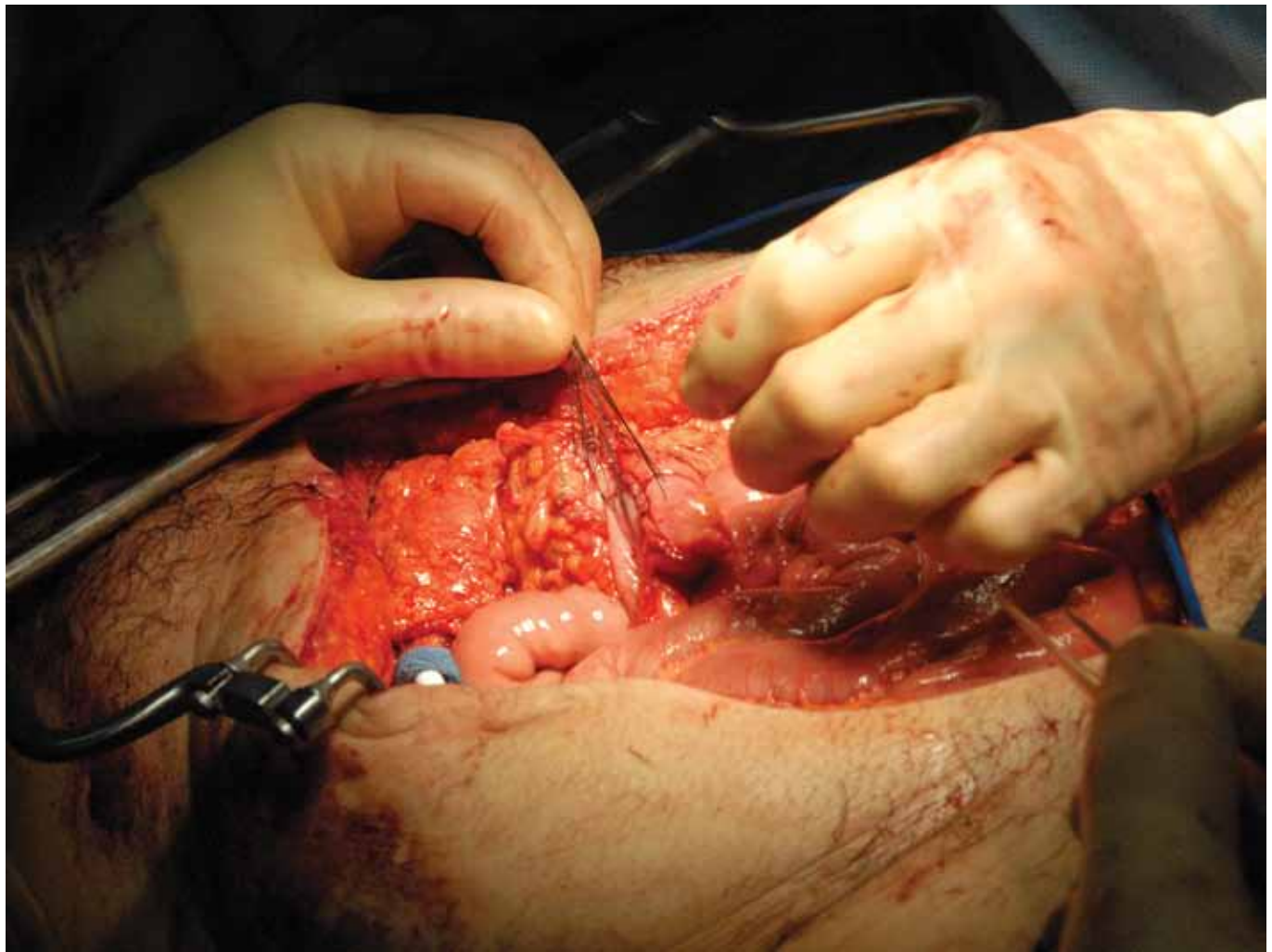


Figure 28. *Suture repair of small bowel perforations following penetrating abdominal injury.*

During damage control laparotomy, all enteric injuries that cannot be repaired by simple suture repair should be resected locally, or en bloc if multiple injuries in close proximity are noted. Primary enteric anastomosis should not be attempted during the initial damage control laparotomy.

Rectal Injury

Injuries to the rectum should be defined as either intraperitoneal or extraperitoneal. Intraperitoneal rectal injuries follow the same concepts outlined previously with enteric injuries. However, extraperitoneal rectal injuries should be treated with end colostomy or loop colostomy. If the rectal defect is not readily identifiable for closure, one should not perform extensive dissection and mobilization of the rectum. Although civilian data suggest that presacral drains and distal stump washout are of limited benefit, military doctrine remains to place presacral drains and consider a distal washout for massive injuries.^{91,92,93}

Extraperitoneal rectal injuries should be treated with end colostomy or loop colostomy.

Abdominal Wall Closure

Once hemorrhage is controlled and the contamination contained, the abdomen is covered with a sterile dressing and a negative-pressure suction device applied. The open abdomen accommodates abdominal visceral swelling, which is a consequence of reperfusion injury, and minimizes the risk of postoperative abdominal compartment syndrome (Fig. 29).^{94,95,96,97} Abdominal compartment syndrome (intraabdominal hypertension) is a potentially lethal disorder caused by conditions that elevate intraabdominal pressure to the point of impairing end-organ function. Excessive fluid resuscitation, reperfusion injury, burn injury, abdominal cavity packing, and intraperitoneal hemorrhage are examples of factors that can lead to abdominal compartment syndrome in the combat casualty.^{98,99}

The fascia is left open following damage control surgery, and the abdomen is temporarily sealed with a sterile dressing and negative-pressure suction device. Skin closure may lead to abdominal compartment syndrome.

The physiologic effects of abdominal compartment syndrome affect many organs.^{99,100,101,102} Clinical manifestations result from diminished preload (decreased venous return) and elevated systemic vascular resistance leading to a decrease in end-organ perfusion. Patients will also exhibit evidence of respiratory insufficiency due to diminished lung volumes (due to impeded diaphragmatic excursion). Patients undergoing mechanical ventilation will exhibit high peak airway pressures and decreased urine output caused by falling renal perfusion pressures, despite adequate volume resuscitation. Elevated intracranial pressures and adverse effects on cerebral perfusion pressures have also been linked to abdominal compartment syndrome in patients with severe head injuries.^{99,102}

Abdominal compartment syndrome was noted in 33 percent of patients in one case series of patients undergoing a damage control surgery in a civilian setting.⁹⁷ The diagnosis of abdominal compartment syndrome is made by indirectly assessing intraabdominal pressures via Foley catheter bladder pressure measurements. A partially filled bladder is very compliant and has been used as an accurate method to assess surrounding intraperitoneal pressures.⁹⁸ Abdominal compartment syndrome has been defined by

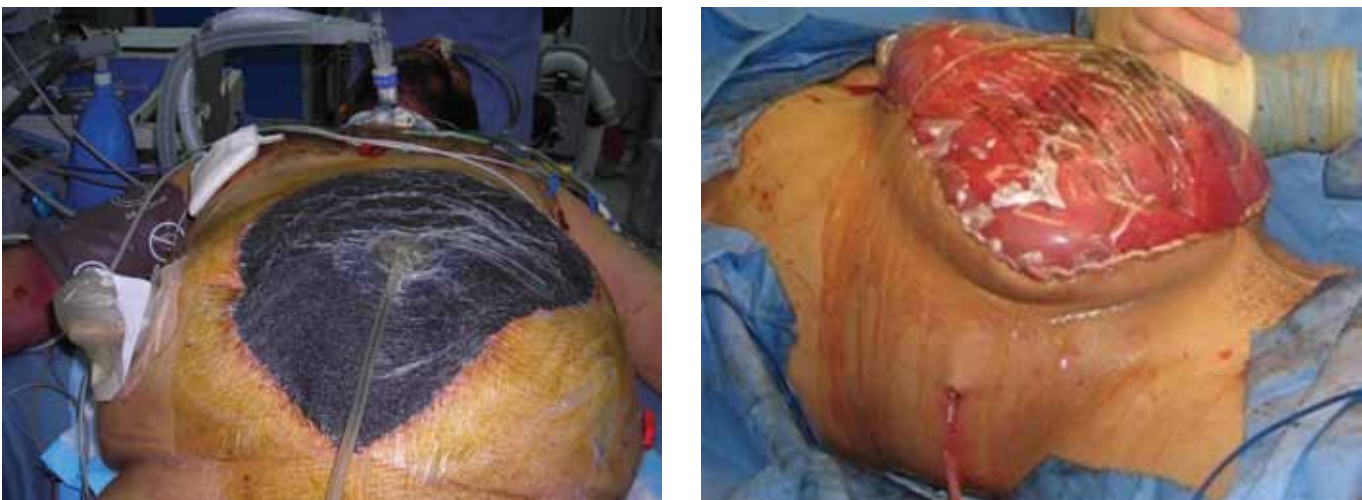


Figure 29. Temporary abdominal wall closure. Leaving the abdominal wall open accommodates abdominal visceral swelling and minimizes the risk of postoperative abdominal compartment syndrome. (Left) A sterile dressing with negative-pressure suction device. (Right) A sterile three-liter crystalloid solution bag used for closure. Right-sided image courtesy of the Borden Institute, Office of The Surgeon General, Washington, DC.

intraabdominal pressures greater than 20 mm Hg, abdominal perfusion pressure less than 60 mm Hg (mean arterial pressure minus intraabdominal pressure), and single or multisystem organ failure.^{98,100,103} It is important to remember that an abdominal compartment syndrome can develop even with an open abdomen, and it is imperative that serial evaluation for this contingency occurs with revision of the closure if necessary. The exact intraabdominal pressure that warrants an intervention remains unclear. There appears to be consensus agreement that intraabdominal pressures greater than 30 mm Hg require an intervention.^{98,99,100,104} Decompressive laparotomy, or an alternative intervention (e.g., loosening of abdominal dressings), to relieve intraabdominal pressures in patients with an open abdomen is indicated when abdominal compartment syndrome is suspected. If left untreated, abdominal compartment syndrome can lead to death.

Peripheral Vascular Injury Damage Control

The concept of successful damage control surgery for peripheral vascular injury had not been fully realized until the recent implementation of temporary vascular shunts in Afghanistan and Iraq.^{105,106} During World War I, German surgeons reported repair of over 100 arterial injuries and pioneered autogenous reconstruction of injured vessels.¹⁰⁵ However, the proclivity for mass casualties, significant soft-tissue injury, and protracted transport times made routine vascular reconstruction impractical, and subsequently, ligation of vessels became standard practice.^{105,106,107} DeBakey reported 2,471 arterial injuries treated by ligation in World War II with a 49 percent amputation rate.¹⁰⁸ With these dismal results, the standard of practice became definitive arterial repair in the Korean War with a dramatic reduction in amputation rate to 13 percent.¹⁰⁹ Similar successes were documented during the Vietnam conflict.^{105,106,107} Therefore, leading up to the conflicts in Afghanistan and Iraq, damage control with ligation was abandoned in favor of definitive vascular repair with greatly improved results.

Arterial Injury and Temporary Vascular Shunts

Improvements in the paradigm of casualty resuscitation during Operation Enduring Freedom (OEF) and Operation Iraqi Freedom (OIF) have provided greater opportunities for deployed surgeons to successfully perform vascular repair after injury on the battlefield. The use of temporary vascular shunts allowed the extension of this damage control paradigm to the treatment of peripheral vascular injuries. In one report, 57 percent of casualties with peripheral arterial injuries had shunts placed at forward surgical facilities, and 86 percent of these shunts were patent when the patient arrived at the Combat Support Hospital (CSH). In two separate analyses of data from the Joint Trauma Theater Registry (JTTR), damage control resuscitation and damage control surgery techniques applied in the context of vascular injury using temporary shunts allowed for delayed prolonged complex limb revascularizations with limb salvage rates of 95 percent.^{110,111} Clouse and Sohn independently demonstrated similar in-theater acute limb salvage rates for revascularization of 92 to 95 percent.^{112,113} The successful use of temporary vascular shunts allows for ongoing patient resuscitation and transport to definitive care with a perfused extremity.¹¹⁴

Temporary vascular shunts are an effective tool in the management of extremity vascular injury and allow for ongoing patient resuscitation and extremity perfusion during transport to definitive care.

An important difference between combat and civilian practice is the role of arteriographic study to rule out vascular injury for proximity wounds. Civilian practice has evolved to expectant management of wounds in

proximity to critical blood vessels if there are no hard signs of vascular injury. Studies have demonstrated no increase of vascular lesions requiring surgical therapy under these circumstances.^{115,116,117} However, the high-energy nature of combat wounds led military investigators to reevaluate this management paradigm in combat casualties (Fig. 30). In a study of 99 patients who underwent angiography after evacuation for wound proximity, 47 percent had vascular abnormalities noted on angiography. Two-thirds of this group had a normal physical examination. Importantly, 52 percent of the patients with an abnormal arteriogram required operative intervention.¹¹⁸ In an analysis of combat-related penetrating neck trauma by Fox et al., 30 percent of patients undergoing computerized tomographic angiography had occult injury and 50 percent of these required interventional or surgical management.¹¹⁹

Role of Temporary Vascular Shunts in Afghanistan and Iraq

Experience from nearly a decade of war in Afghanistan and Iraq suggests that temporary vascular shunts are a feasible and effective tool in the management of extremity vascular injury.^{114,120,121,122} The use of temporary vascular shunts is particularly germane in modern combat where the rate of vascular injury (5 to 7 percent) is much higher than reported in previous wars.^{112,120} The increased use of body armor and other force protection measures as well as tourniquets may increase the survivability of wounds that were deadly in previous wars.¹²³ As such, injured service members who in the past may have succumbed to torso wounds or exsanguination from extremity injuries now survive to have vascular injuries recorded and treated.¹²⁰

In this context, temporary vascular shunts are part of a management triad of: (1) vascular injury exploration; (2) thrombectomy and restoration of flow; and (3) fasciotomy. Following injury exploration, vascular shunts are inserted in both ends (proximal and distal) of the disrupted vessel to bridge and provide flow distal to the defect, and maintain limb viability (Fig. 31). Shunts can typically be placed in an expeditious manner and require less time and technical expertise than formal vascular repair. Data from the Balad Vascular

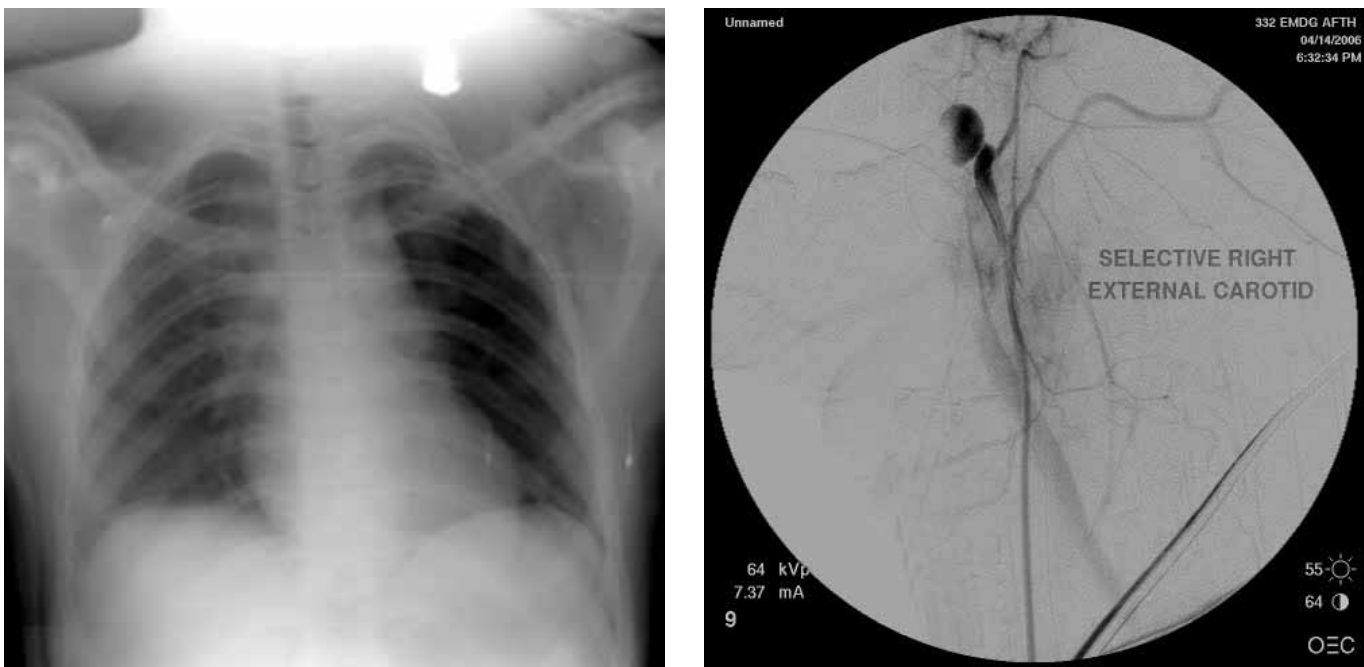


Figure 30. Proximity wounds. (Left) Due to the greater energy imparted by military ballistic projectiles, injury in proximity to critical blood vessels, particularly in the cervical region, should be evaluated by angiography to mitigate the risk of occult vascular injury. (Right) The subsequent carotid angiogram revealed a vascular injury requiring coil repair. Images courtesy of David B. Powers, DMD, MD, COL, US Air Force.

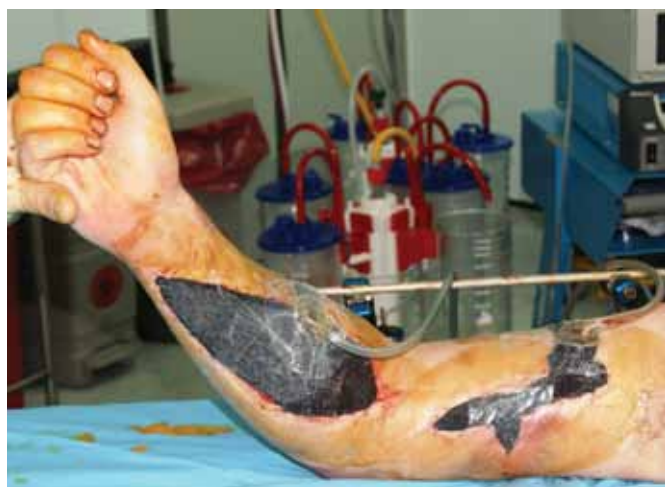
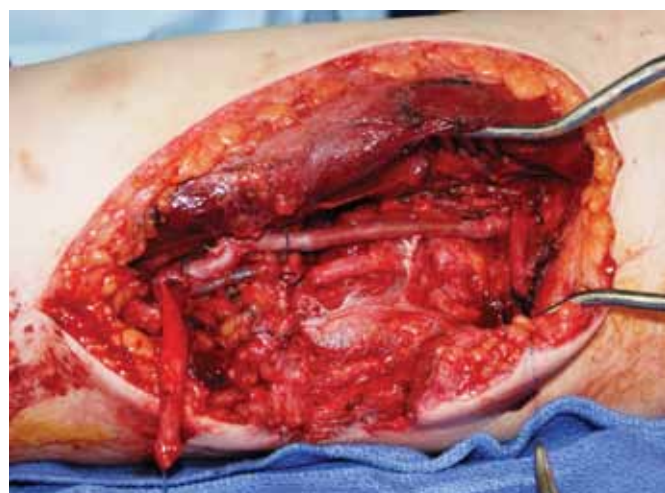
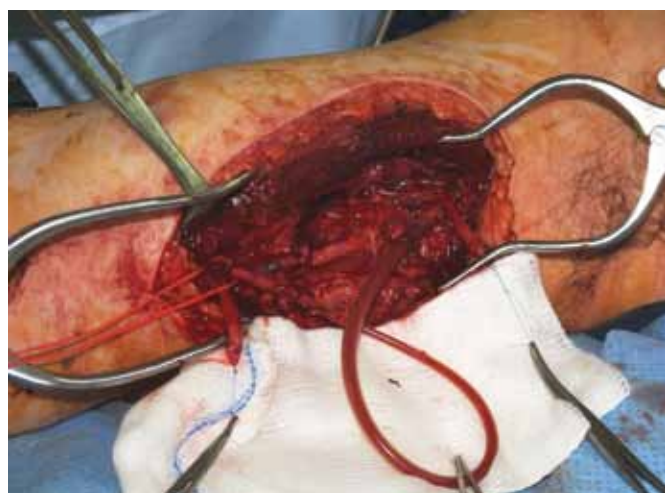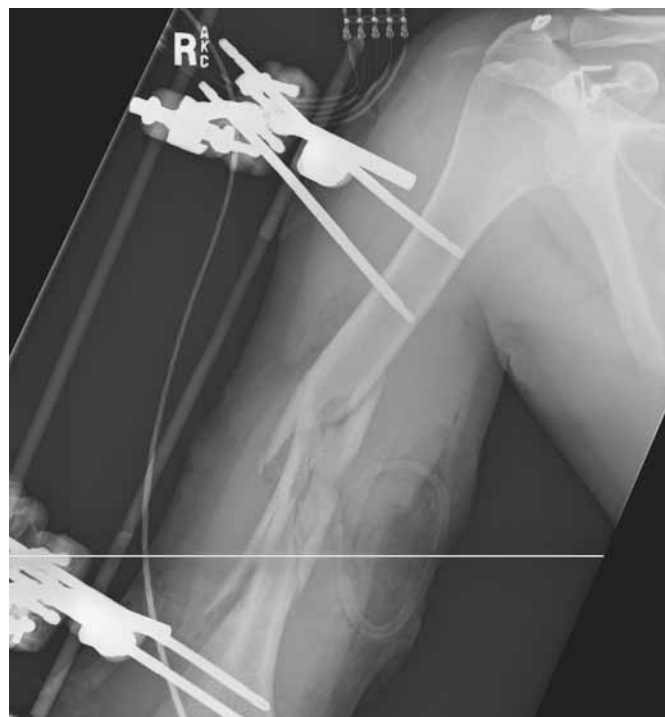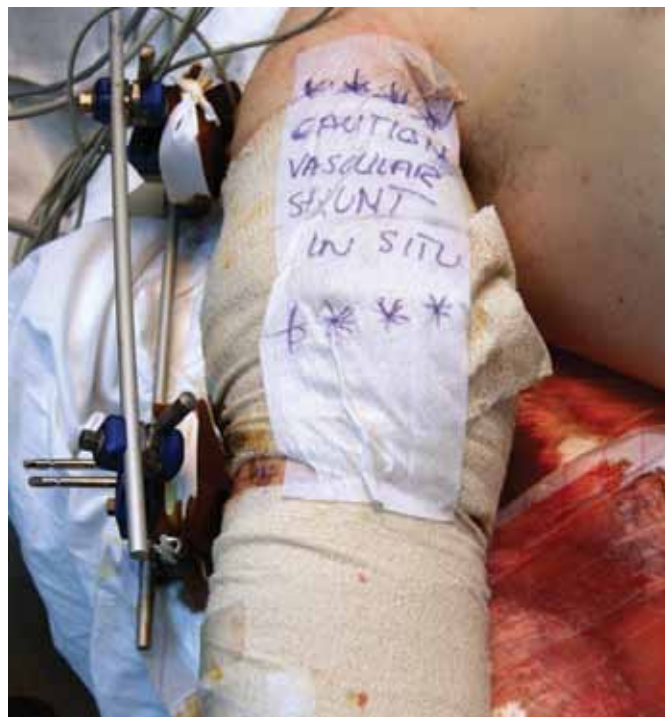Figure 31. Vascular repair: (Top Left) Level III facility care of a casualty with a GSW to the right upper arm with an open comminuted humeral fracture and transected right brachial artery and median nerve. The casualty was initially treated at a Level II facility and underwent vascular injury exploration, placement of a Javid™ temporary vascular shunt in the right brachial artery, and forearm fasciotomy. An external fixator was applied. (Top Right) A radiograph obtained at the Level III ED five hours following injury reveals the presence of an indwelling shunt. (Center Left) A patent shunt with excellent Doppler signal was noted during surgical exploration. (Center Right) The shunt was removed and an interposition vein graft repair of the brachial artery was performed. (Bottom Left) A negative-pressure suction device was applied and the patient was transported to a Level IV facility.

Registry reveals that a majority of temporary vascular shunts are placed during Level II damage control surgical care, prior to the medical evacuation of casualties to Level III facilities.^{112,114} A review of in-theater evacuation data reveals an average time from loading on a helicopter to arrival at a Level III facility of 46 minutes.¹²⁰

Temporary vascular shunts are part of a management triad of: (1) vascular injury exploration; (2) thrombectomy and restoration of flow; and (3) fasciotomy.

Once placed, shunts maintain perfusion to the extremity (distal to the site of injury) during medical evacuation (MEDEVAC) or treatment of other life-threatening torso or head injuries. In this sense, shunts are amenable to use in forward surgical units where damage control or abbreviated operations (less than one hour) are the goal.^{114,121,122} The alternative to initiating the previously mentioned management triad is deferring vascular injury treatment during MEDEVAC and/or management of other injuries. If restoration of flow to the extremity is delayed in these instances, warm-ischemia time compounds increasing neuromuscular damage and decreases the likelihood of limb recovery and salvage.

Data from a large-animal model of hind-limb ischemia and reperfusion demonstrated that early restoration of flow using temporary vascular shunts reduced circulating markers of injury and resulted in improved flow in the injured extremity.¹²⁴ Specifically, this study showed that restoration of flow following one hour of ischemia resulted in an 18-hour reperfusion profile that was the same as controls (i.e., no ischemia). In contrast, restoration of extremity flow with a temporary vascular shunt after three to six hours resulted in reperfusion profiles that were incrementally adverse. The conclusion of this study was that early (one hour) versus delayed (greater than three hours) restoration of flow was associated with measurably improved responses.¹²⁴ The presence of shock or other soft-tissue or bony injury may even further reduce this ischemic threshold to less than three hours, after which recovery of the limb should not be expected. Results from these large-animal experiments inform surgeons that the critical warm-ischemia time for an extremity in the combat setting (i.e., with hemorrhage and soft-tissue injury) is likely less than three hours and may be as short as one hour.

Results from large-animal experiments suggest that the critical warm-ischemia time for an extremity in a combat setting (i.e., with hemorrhage and soft-tissue injury) is likely less than three hours and may be as short as one hour.

Early reports from Iraq indicated that shunts were being used effectively at forward Level II facilities.^{114,121,122} Specifically, Javid™, Argyl™, and Sundt™ shunts have been extensively used. Shunts remained in place during MEDEVAC to higher levels of in-theater care where they were then removed and definitive reconstruction performed.^{114,121,122} During times of high casualty rates in Iraq, shunts were used in up to 50 percent of femoral/popliteal injuries, a frequency that is similar to that currently encountered in Afghanistan by the author (TR).¹²⁵

Complications

Early temporary vascular shunt-related complications have been rare, and shunt patency, when placed in larger, more proximal arteries of the extremities, approaches 90 percent at four to six hours.^{114,121,122} Data from the JTTR, Balad Vascular Registry, and the Walter Reed Vascular Registry demonstrate that use of

temporary vascular shunts as an adjunct in damage control surgery did not result in worse outcomes. In fact, the use of shunts extended the window of opportunity for limb salvage in the most severely injured limbs. However, demonstration of definitive benefit was not shown.¹²⁶ Late complications associated with revascularization do occur and include thrombosis, infection, and compartment syndrome.^{110,127} Interestingly, the factor most significantly associated with post-revascularization morbidity was the use of prosthetic graft implants. Unlike the results of civilian vascular injury, when a prosthetic graft was used with combat vascular injuries, the incidence of graft loss was 80 percent.^{110,120,127} Hence, a primary goal of vascular surgeons at Level III facilities is to ensure no temporary vascular shunt or prosthetic conduit be sent out of theater. Definitive repair of vascular injuries with primary or autologous vein repair is a priority.

Vascular surgeons at Level III facilities should perform definitive repair of vascular injuries that have been previously treated with a temporary vascular shunt or prosthetic conduit prior to transport to a Level IV or Level V facility.

Reperfusion injury often results in extremity compartment syndrome following restoration of perfusion to injured limbs. Hence, prophylactic fasciotomy following definitive vascular repair of an injured limb is recommended.¹²⁸ Prophylactic fasciotomy should also be considered (especially if prolonged medical evacuation times are anticipated) concurrent with the placement of temporary vascular shunts, for similar reasons.

Recent increased operational activity in the Afghanistan Theater has provided the opportunity to assess the effectiveness of temporary vascular shunts in an environment with unique casualty evacuation (CASEVAC) and MEDEVAC characteristics. In contrast to OIF, CASEVAC and MEDEVAC in Afghanistan are challenged by mountain passes, which hinder direct rotary-wing transport in many cases. Additionally, the multinational nature of combat casualty care in OEF results in instances of intratheater transport of injured casualties to nation-specific air hubs for preparation for transcontinental air evacuation (AIREVAC). These realities have given rise to a form of MEDEVAC which includes intratheater use of fixed-wing casualty movement referred to as tactical evacuation (TACEVAC). In this setting, vascular injury management has been challenged by instances of longer times between injury and definitive vascular repair. The generally longer TACEVAC times in OEF have given rise to observations by the author (TR) of longer indwell times of temporary shunts (up to 12 to 24 hours) without complication. Although not tested because of rapid and consistent MEDEVAC during OIF, these observations are consistent with experiments demonstrating up to 24-hour patency of shunts without the use of heparin.^{124,129} In the author's (TR) experience, the use of temporary vascular shunts in Afghanistan is nearly uniform in extremity vascular injuries, and complications remain uncommon. As in Iraq, even if temporary vascular shunts occlude or clot, it does not preclude removal of the shunt and restoration of flow with formal vascular repair at Level III facilities.

Conclusions

In aggregate, this data, combined with a decade's experience in OEF/OIF, lead to the conclusions that early restoration of flow (within one hour) using temporary vascular shunts is advantageous. Specifically, when formal vascular repair is not possible, shunts should be used as part of the management triad of: (1) extremity vascular injury exploration; (2) thrombectomy and restoration of flow; and (3) fasciotomy. The application of this management triad should occur as soon as feasible after injury, in the context of tactical considerations and other concomitant life-threatening head and torso injuries. Whether this triad

is undertaken at a Level II or III facility is a matter of semantics and is more dependent upon the time from injury to point of surgical care. Temporary vascular shunts are part of the management triad of injury exploration, restoration of flow, and fasciotomy. Ideally, their use reduces warm-ischemia time and extends the window of opportunity for limb salvage. Experienced vascular surgeons, cardiothoracic surgeons, or trauma surgeons are usually only located at Level III facilities. Vascular injuries sustained in the combat environment must undergo arterial reconstruction with autogenous material at Level III facilities, since prosthetic grafts have a much higher rate of infection.

Venous Injury

In the context of battlefield venous injury, ligation is a safe and effective option. Venous ligation is an expedient solution that allows the surgeon to address other injuries in critically ill patients. A review of the management of 103 venous injuries from the Global War on Terror indicates ligation (63 percent) is more common than repair (37 percent).¹³⁰ All patients, regardless of management, developed postoperative edema. While thrombosis of the repair was demonstrated in 16 percent of the repaired veins, there was no acute limb loss or venous graft failure associated with venous ligation.¹³⁰ Pulmonary embolus developed in three cases, one in a patient with open repair, and two in cases managed with ligation. Long-term outcomes and follow-up data are needed to determine what the best approach to management should be.

Ligation is a safe and effective option for combat-related venous injury.

Proximity to Great Vessel Injury

Contrary to civilian trauma literature recommendations, penetrating extremity injury in proximity to critical blood vessels, particularly in the cervical region, should be evaluated by angiography to mitigate the risk of occult vascular injury due to the greater energy imparted by military ballistic projectiles.¹¹⁹ It is important to know the patient's total trauma burden and physiology when deciding how to manage that patient's vascular injury. The treatment of vascular injuries in combat casualties can be a challenging endeavor in a resource-limited environment. Optimal care depends upon technical expertise on the part of the operating surgeon and solid judgment regarding when to perform temporizing maneuvers versus definitive repairs. Surgeons at all Level II and III facilities need to be intimately familiar with the use of vascular shunts as a means to stabilize a critically wounded casualty and then move them along the continuum of care.

Penetrating extremity injury in proximity to critical blood vessels, particularly in the cervical region, should be evaluated by angiography to identify occult vascular injury.

Extremity Tourniquets

Control of life-threatening hemorrhage following extremity injury has been greatly improved through the field application of the extremity tourniquet.^{131,132} Patients requiring damage control procedures for presumed extremity vascular hemorrhage should have the prehospital tourniquet prepped into the operative field or replaced by a sterile tourniquet in the operating room (Fig. 32). Basic vascular surgery principles of proximal and distal control are employed to access extremity vessel injury (Fig. 33). The majority of injuries in patients with penetrating extremity trauma can be explored directly with no need for preoperative arteriography. However, in patients with diffuse or multiple extremity injuries associated with vascular compromise, arteriography is often useful if the patient's physiologic status will tolerate the procedure.^{118,133}

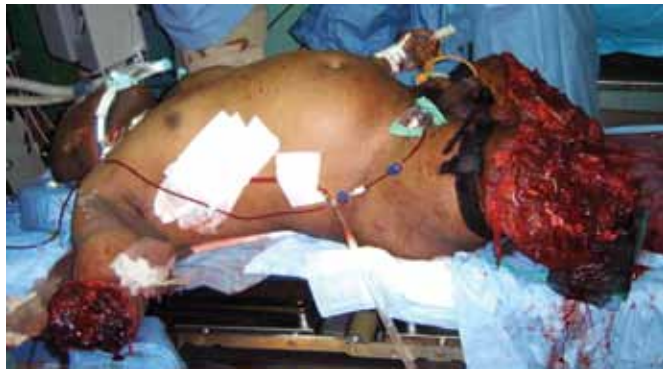

Figure 32. Control of life-threatening hemorrhage following extremity injury has been greatly improved through the field application of the extremity tourniquet. Image courtesy of Joint Combat Trauma Management Course, 2007.

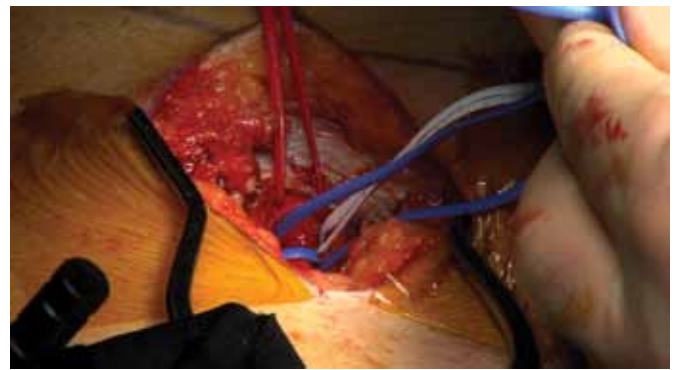


Figure 33. Basic vascular surgical principles of proximal and distal vessel control are a cornerstone of extremity injury management.

Upper Extremity Arterial Injury

The axillary artery can be exposed through an infraclavicular incision from midclavicle to the deltopectoral groove through the clavipectoral fascia. The brachial artery is accessed by incising the medial aspect of the upper arm between biceps and triceps. When gaining control of the brachial vessel, care should be taken to avoid injury to the basilic vein and median nerve. An S-shaped incision is required if the incision crosses antecubital fossa. If the vascular injury is below the profunda brachii, the patient will usually tolerate ligation. The radial and ulnar arteries can generally be singly ligated.¹³⁴ However, an Allen test is required to assess the vascular integrity of the hand prior to vessel ligation.

Femoral Vasculature Injury

In the lower extremity, the femoral artery can be accessed proximally via a standard femoral cutdown. For superficial femoral arteries, acute occlusion in young healthy patients without established collateral flow is not well-tolerated.¹³⁵ In the damage control setting, the superficial femoral vessels are easily shunted by standard shunting techniques. This vessel can be definitively repaired or an autogenous interposition graft placed once the patient has been adequately resuscitated. The majority of venous injuries can be ligated, especially if the patient is in extremis.¹³⁰ After performing a deep venous ligation in the lower extremity, it is incumbent upon the surgeon to be aware of the subsequent lower extremity venous hypertension and risk for the development of a lower extremity compartment syndrome. As such, liberal use of four compartment fasciotomies through extended incisions should be considered.

Popliteal and Tibial Vasculature Injuries

The popliteal artery behind the knee requires an extended medial approach, dividing tendinous muscular attachments of the hamstring complex and the soleus. Again, depending upon the acuity of the patient and available resources, the therapeutic options include shunting, repair, or bypass. If the popliteal vein is injured, it should be repaired if the patient's condition allows. This will reduce subsequent lower extremity venous hypertension and the risk for compartment syndrome. Tibial arteries are uniformly ligated in the damage control paradigm.¹³⁶

Pelvic Injury Damage Control

Background

Pelvic fracture is a marker of severe injury and is classically associated with a substantial rate of morbidity and mortality. Although pelvic fractures account for only 3 percent of all acute fractures, mortality in this patient population varies from 10 to 50 percent depending upon fracture pattern.^{137,138,139} Morbidity and mortality in this patient population are multifactorial and often associated with concomitant injury to the brain, thorax, and abdomen since the force imparted to fracture the pelvis is also imparted to other regions of the body.^{137,138,139} Pelvic fractures can be associated with considerable hemorrhage, especially when the posterior elements of the pelvis are significantly disrupted.^{137,138,139} The resultant pelvic hemorrhage can be both arterial and venous and may emanate from the major vasculature or its truncal branches, the presacral venous plexus, the soft-tissue, or the large bulk of open cancellous bone in the region (Fig. 34). Survival of patients with pelvic fracture is optimized by prompt diagnosis of the pelvic fracture, vigorous resuscitation, pelvic stabilization, and definitive control of hemorrhage.^{137,138,139}

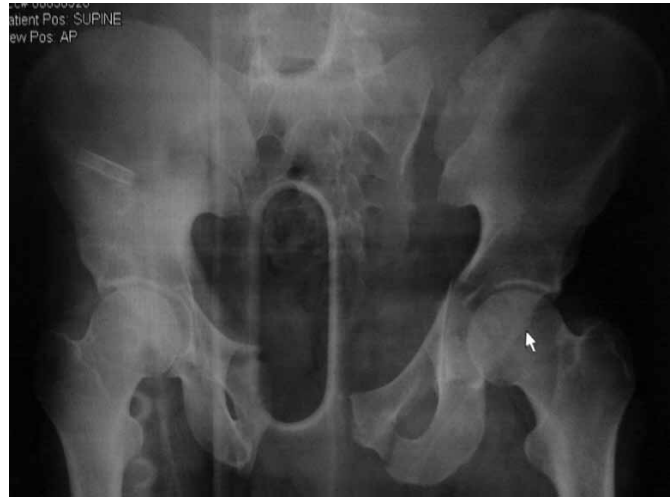

Figure 34. Pelvic fractures can be associated with considerable hemorrhage, especially when the posterior elements of the pelvis are significantly disrupted as depicted in this radiograph.

Pelvic fractures can be associated with considerable hemorrhage, especially when the posterior elements of the pelvis are significantly disrupted.

The effective management of pelvic fractures and associated hemorrhage, especially in the deployed military environment, requires multidisciplinary cooperation of the emergency physician, trauma surgeon, and the orthopedic surgeon. While the use of interventional angiographic embolization has dramatically improved outcomes in the civilian management of severe pelvic fracture hemorrhage, interventional radiology is not typically available on the battlefield. To date, this has meant that damage control maneuvers such as pelvic wrapping and external fixation have become the primary means for temporizing hemorrhage control. Unfortunately, these maneuvers cannot reliably control pelvic arterial hemorrhage. The relatively recent adoption of extraperitoneal pelvic packing through the space of Retzius has offered a potentially effective damage control procedure for pelvic fracture-associated hemorrhage that may temporarily arrest or abrogate hemorrhage, to allow transport to a facility capable of angiographic embolization.¹⁴⁰

Extraperitoneal pelvic packing through the space of Retzius is a potentially effective damage control procedure for pelvic fracture-associated hemorrhage. It may temporize bleeding until angiographic embolization can be performed.

Physical Examination

Pelvic fracture should be suspected in all patients with appropriate mechanisms of injury. Evidence of systemic hypoperfusion in combination with a pelvic fracture suggests fracture-associated hemorrhage and requires prompt resuscitative and therapeutic interventions.¹³⁹ The objectives of the pelvis examination are to estimate the likelihood of fracture, assess pelvic ring stability, and identify injuries to the adjacent structures. The examination begins with visual inspection of the pelvis for signs of injury. Look for abrasions, contusions, and lacerations. The presence of progressive flank, scrotal, perineal ecchymosis, or edema suggests pelvic injury with significant bleeding. Destot's sign is a hematoma above the inguinal ligament. Grey-Turner's sign is a flank ecchymosis secondary to retroperitoneal hemorrhage. Wounds in the pelvic area should be assessed carefully to exclude an open pelvic fracture. Lacerations involving the perineum, vagina, rectum, or scrotum are highly suggestive of an open pelvic fracture. Failure to thoroughly examine the gluteal cleft, buttock fold, rectum, and vagina for open wounds may lead to missed injuries. All patients with pelvic fractures should undergo a rectal exam with special attention to the rectal tone, the presence of rectal bleeding, and the position of the prostate. Diminished rectal tone could result from a pelvic fracture with accompanying lumbosacral nerve plexus injury. Gross blood or stool that tests guaiac-positive could represent a possible open pelvic fracture.¹⁴¹ A high-riding or free-floating prostate suggests membranous prostatic urethral injury.¹⁴² In patients with a concomitant pelvic hematoma, the outline of the prostate may be indistinct to palpation despite a normal position. A positive Earle's sign is the presence of a bony prominence, palpable hematoma, or tender fracture line on rectal exam. The genitourinary system should be carefully examined. Scrotal swelling or ecchymosis and the presence of bleeding from the urethral meatus are signs of urethral disruption (Fig. 35). A vaginal examination should be performed in female patients to assess for palpable fractures, vaginal lacerations, and blood within the vaginal vault. Pelvic fractures in association with vaginal or rectal lacerations are considered open fractures.¹⁴³

Examination of the lower extremities begins with visual inspection. Discrepancies in leg length, gross rotational deformities, or asymmetry of the hips should be noted. In the absence of a lower extremity fracture, these findings suggest a pelvic fracture or hip dislocation. A patient with a posterior hip dislocation will have a shortened extremity held in an internally rotated position. Range of motion at each hip should be assessed. A study by Ham et al. found that the inability to actively flex the hip was the maneuver most reliably predictive of a pelvic fracture. It had a 90 percent sensitivity and 95 percent specificity for detecting a pelvic fracture.¹⁴⁴ The stability of the pelvis may be assessed by applying lateral-to-medial compression and anterior-posterior compression over the anterior-superior iliac crests. Many clinicians advocate foregoing any forceful manipulation of a potentially injured pelvis for fear of dislodging clots from injured vessels and precipitating renewed pelvic hemorrhage. Neurologic examination should be thorough, as many patients have significant neurological disability, especially when the pelvic fracture extends into or through the sacral foramina. Particular attention should be paid to the lumbar (L5) and sacral (S1) nerve roots to detect an injury to the lumbosacral nerve plexus or its nerve roots. The L5 nerve root may be tested by assessing dorsiflexion of the great toe against resistance and sensation over the dorsum of the foot. The S1 nerve root is tested by evaluating plantar flexion of the great toe against resistance, sensation along the lateral aspect of the foot, and the Achilles tendon reflex.

Radiographic Evaluation

Contingent upon resources, radiographic evaluation should be performed to allow the surgeon to determine the morphology of the pelvic fracture.

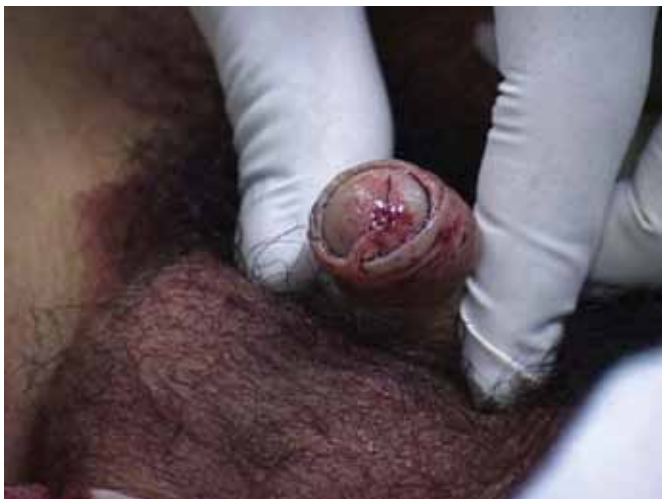

Figure 35. *The presence of urethral meatal bleeding and scrotal swelling or ecchymosis are signs of potential urethral disruption.*

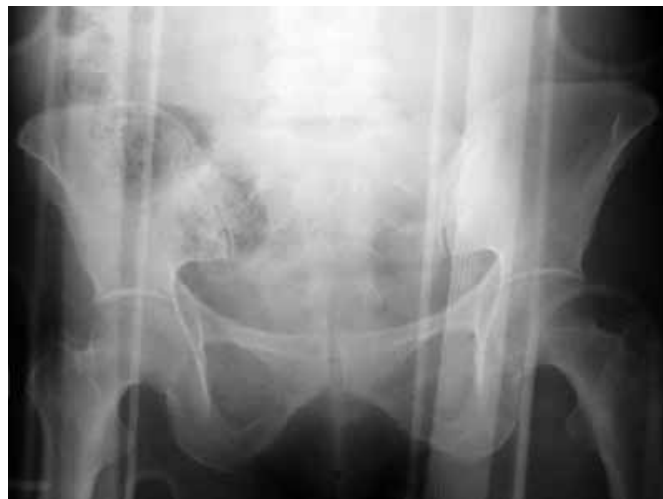

Figure 36. *An anteroposterior (AP) plain radiograph of the pelvis will identify the vast majority of significant pelvic fractures.*

Plain Radiography

An anteroposterior (AP) plain radiograph of the pelvis will identify the vast majority of pelvic fractures (Fig. 36). It allows for early identification of serious pelvic injuries that may be a source of blood loss. It may also detect proximal femur fractures and hip dislocations. When the patient is in a supine position, the AP pelvis radiograph actually provides an oblique view of the pelvic brim. This is because the pelvis lies 45 to 60 degrees oblique to the long axis of the skeleton. Many acetabular fractures are not visible on the AP pelvic radiographs. Plain radiography is not as accurate as computed tomography (CT) imaging for evaluation of pelvic fractures.^{145,146} When compared with CT imaging, plain films missed 57 percent of acetabular rim fractures, 50 percent of femoral head fractures, 40 percent of intraarticular fragments, 34 percent of vertical shear fractures, and 29 percent of sacroiliac diastasis injuries.¹⁴⁷

Computed Tomography Imaging

Computed tomography imaging is extremely valuable in the diagnosis and characterization of pelvic injuries. Computed tomography may be utilized to identify or exclude a pelvic injury in equivocal cases or to further delineate a known pelvic fracture. When compared with plain pelvis radiographs, CT is more sensitive in the detection of pelvic fractures and allows better characterization of the fractures and adjacent soft-tissues.¹⁴⁶ The primary advantage of CT imaging is the ability to simultaneously screen for associated injuries (e.g., visceral injuries). In most trauma victims, the bony pelvis is scanned as part of a combined abdomen and pelvis CT study. If a fracture is detected, further imaging with thinner axial sections may be obtained of the area of interest. An important aspect of CT imaging is the use of reformatted images. Multiplanar reconstruction is the reformatting of data to produce images along the sagittal and coronal planes. Inlet and tangential views may be created, eliminating the need for additional plain films. In addition to multiplanar reconstruction, three-dimensional images may also be constructed using three-dimensional image rendering software. Three-dimensional spiral CT images may detect subtle fractures (specifically those in the axial plane), demonstrate spatial relationships of fracture fragments, and guide management (Fig. 37).

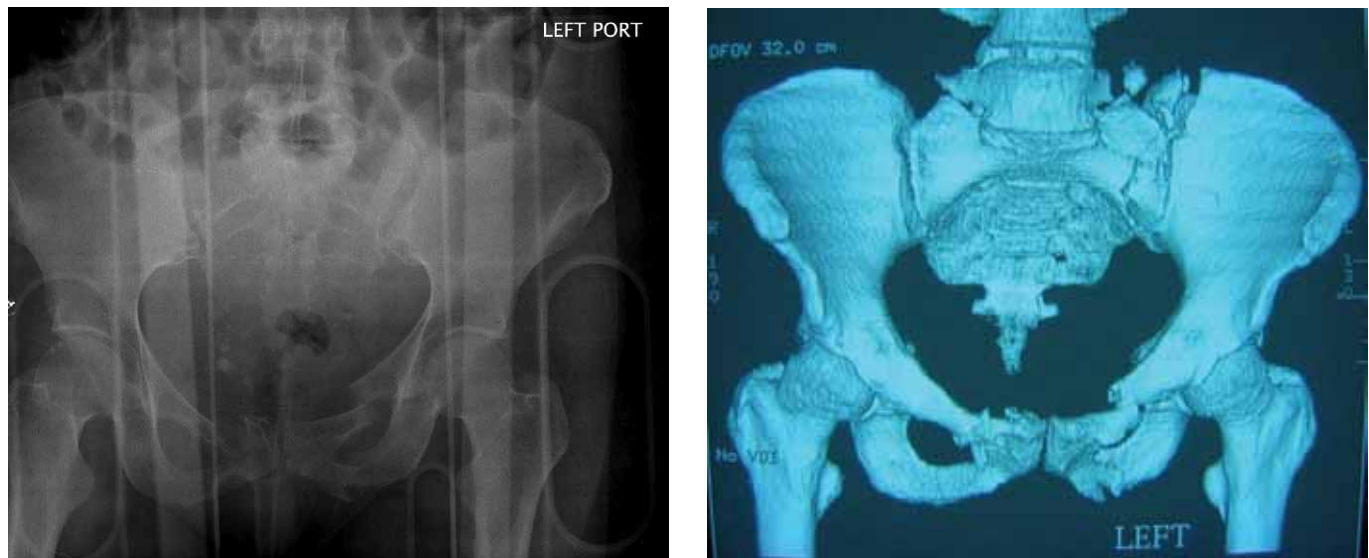


Figure 37. *Three-dimensional CT images may detect subtle fractures, demonstrate spatial relationships of fracture fragments, and guide management. Images courtesy of Swaminatha V. Mahadevan, MD, Stanford University.*

Angiography

The use of intravenous contrast allows simultaneous evaluation of both osseous and vascular structures. Contrast-enhanced CT imaging can demonstrate active arterial bleeding. This is usually from branches of the internal iliac artery or internal pudendal artery. Nonarterial bleeding may also be detected. These hematomas typically originate from disruption of the posterior pelvic veins or the surfaces of fractured bones. The gold standard test for detecting arterial bleeding associated with pelvic fractures is traditional angiography (Fig. 38). Spiral CT angiography of the pelvis has been shown to be moderately sensitive (84 percent) and specific (85 percent) for the detection of acute pelvic bleeding in trauma.¹⁴⁸ Standard angiography has the important advantage of serving as an excellent diagnostic and therapeutic modality (e.g., embolization).^{149,150,151}

Acute Management

The acute management of the patient with pelvic fracture and hemorrhage involves three basic tenets: (1) stabilization of the pelvis; (2) control of pelvic hemorrhage; and (3) identification and control of extrapelvic hemorrhage sources. Pelvic stabilization limits radial expansion of the pelvis and protects against increases in pelvic volume and additional hemorrhage. It is hypothesized that stabilization affects hemostasis via tamponade and clot maintenance.^{137,152} Emergent stabilization of the pelvis is almost exclusively temporizing in nature, from the point of view of fracture fixation and serves as a bridge to later definitive internal fixation once the patient is physiologically stable. Potential stabilizing methods include the pelvic sheet sling, pelvic binder, and external fixation (Fig. 39).^{153,154}

The acute management of the patient with pelvic fracture(s) and hemorrhage involves three tenets: (1) stabilization of the pelvis; (2) control of pelvic hemorrhage; and (3) identification and control of extrapelvic hemorrhage sources.

When placing the sheet sling, the boundaries of the wrap should be the anterior-superior iliac spine (cephalad) and the greater trochanter (caudad). After wrapping the pelvis, twist the wrap in front and clip

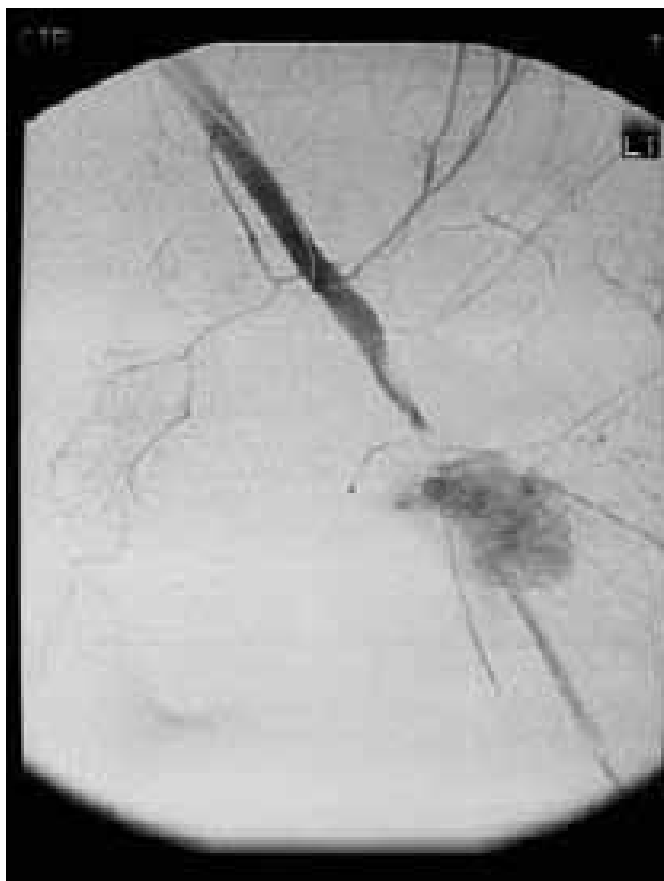

Figure 38. *The gold standard test for detecting arterial bleeding associated with pelvic fractures is traditional angiography.*

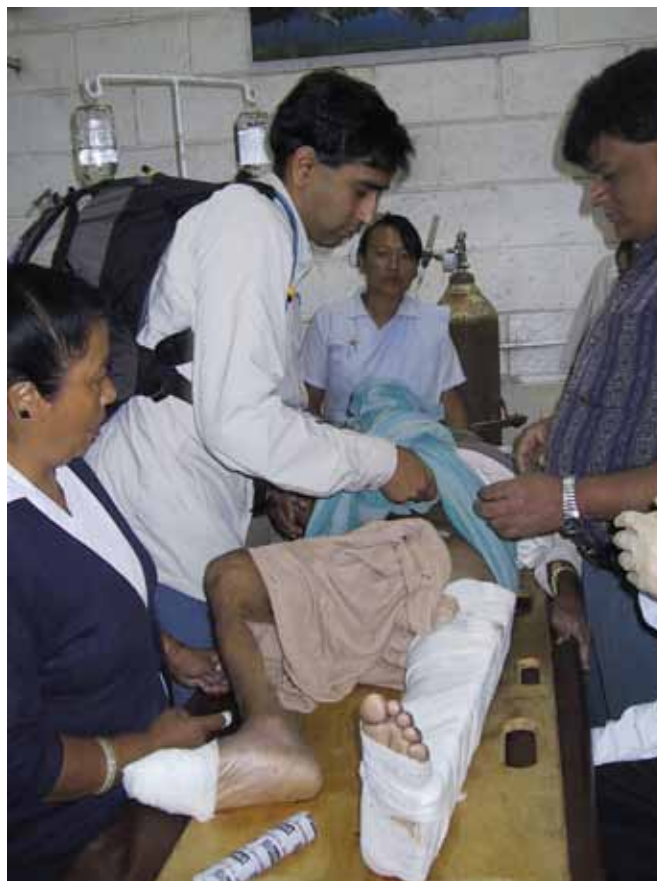

Figure 39. *Pelvic stability may be improved with application of a pelvic binder or bed sheet around the patient's hips. Image courtesy of Swaminatha V. Mahadevan, MD, Stanford University.*

or tie the wrap back to itself to maintain the stabilization.¹⁵⁵ The pelvic binder is a useful adjunct in the battlefield environment because it is light, adaptable to any body size, and easy to apply.

External fixation can be applied within minutes by an orthopedic surgeon or a specially trained general surgeon in more remote environments. When the external fixator is placed, crossmembers should be placed, with thought given to potential future therapeutic adjuncts (Fig. 40). A substantial percentage of pelvic hemorrhage is venous and can be controlled through efforts to effect pelvic ring stabilization in conjunction with blood resuscitation to replace volume loss.^{153,156} This ongoing resuscitation often requires upwards of 10 units of packed red blood cells and additional blood component therapy to accomplish, and the patient must be cared for in the ICU. In general, pelvic hemorrhage is not approached operatively via celiotomy. The primary reason is that once the hematoma has been released into the peritoneal cavity and tamponade-effect lost, bleeding will increase. It is difficult, if not impossible, to locate and ligate the bleeding vessels. Furthermore, packing the pelvis once the retroperitoneal hematoma has been disrupted into the peritoneal cavity is not effective since there is nothing to pack against. This scenario often results in exsanguination.

Early pelvic stabilization can control hemorrhage and reduce mortality. Potential stabilizing methods for pelvic fractures include the pelvic sheet sling, pelvic binder, and external fixation.

Recent evidence from the civilian literature suggests that an alternative preperitoneal approach and packing

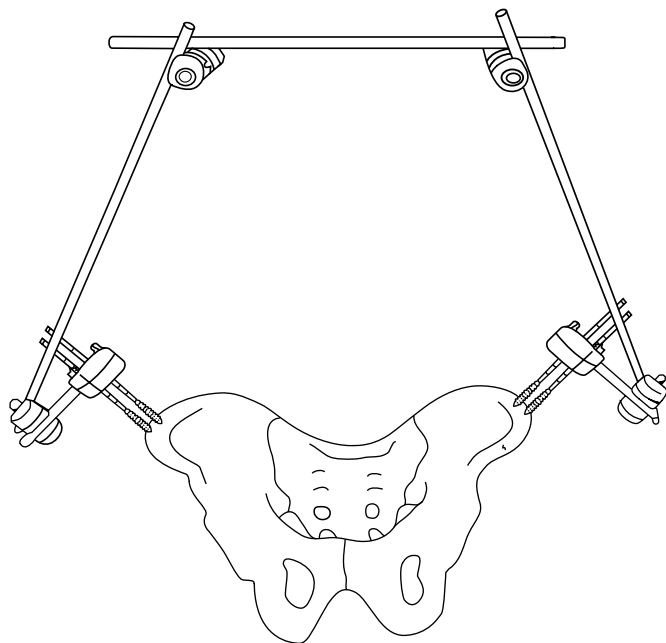


Figure 40. Early pelvic stabilization can control hemorrhage and reduce mortality. External fixator placement in the iliac crests is often used to stabilize the pelvis. Image courtesy of the Borden Institute, Office of The Surgeon General, Washington, DC.

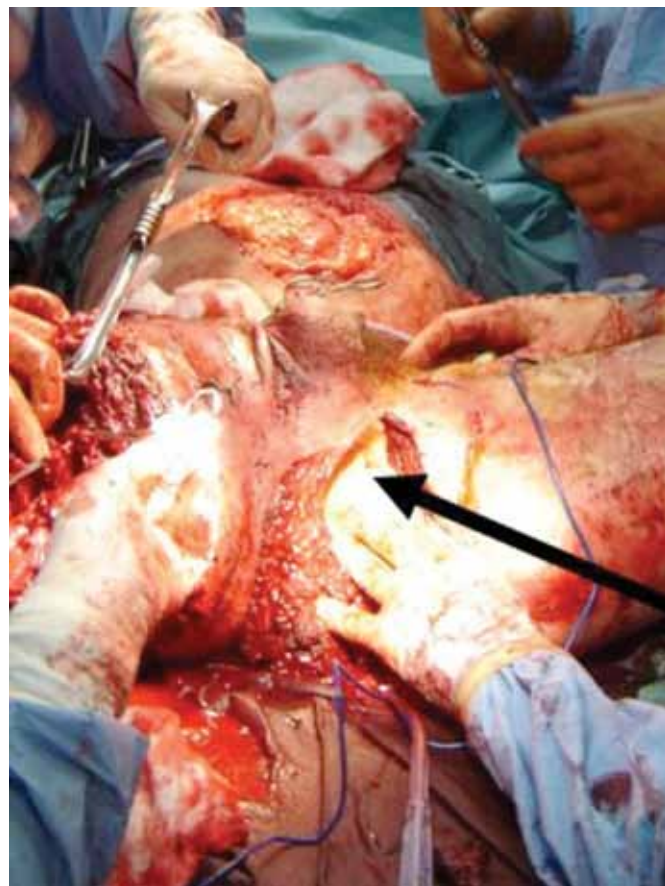


Figure 41. Open pelvic fractures require hemorrhage control, aggressive debridement, and fecal diversion if significant perineal soft-tissue or anorectal disruption exists. Image courtesy of Leopoldo C. Cancio, MD, FACS, COL, MC, US Army.

of the pelvis through the space of Retzius may be more effective. Such an approach controlled pelvic bleeding and significantly reduced blood product transfusions and mortality in a selected high-risk group of patients.^{157,158} Preperitoneal and pelvic packing may prove to be an important intervention in the austere deployed environment where resources and therapeutic options are limited. In this scenario, if a patient does not respond to initial resuscitation, they are taken to the operating room where an initial small laparotomy incision is made above the umbilicus. If the source of hemorrhage is in the abdomen, the incision is extended. On the other hand, if there is a large pelvic retroperitoneal hematoma, a separate lower midline incision is made to enter the extraperitoneal space of Retzius. The pelvic hematoma is evacuated, the bladder displaced, and packs are placed on both sides of the bladder deep into the pelvis. If an unstable pelvic fracture is present, it is necessary to apply a pelvic fixator to provide something to pack against. The patient can then be resuscitated and transported to a rearward facility with angiographic embolization capabilities. Interventional angiography (e.g., embolization) is often only available at Level IV and V care facilities.

Open Pelvic Fractures

Open pelvic fractures present a unique management challenge to the surgeon (Fig. 41). The same basic management principles apply with some notable additions. Efforts must be made to directly control or tamponade external hemorrhage. Soft-tissue injury must be vigorously debrided. Fecal diversion must be

strongly considered in patients with significant perineal soft-tissue or anorectal injuries, though this may be done at subsequent reoperation.^{143,159} As with all combat wounds, the early administration (ideally within three hours of injury) of broad-spectrum prophylactic antibiotics is recommended.¹⁶⁰ Exclusive of associated injury, the prognosis of patients with pelvic fractures is directly correlated with severity of injury and prompt institution of therapeutic strategies for temporizing pelvic stabilization and hemorrhage control. Morbidity and mortality of open pelvic fractures are higher than their closed counterparts.¹⁵⁹ This is secondary to difficulty controlling external pelvic hemorrhage and sepsis associated with soft-tissue and enteric injuries.^{143,159}

Management of open pelvic fractures includes hemorrhage control, aggressive debridement of soft-tissues, pelvic stabilization, and fecal diversion through a colostomy.

Bladder and Urethral Injuries

The incidence of genitourinary injuries associated with pelvic fractures is reported to be as high as 25 percent and includes bladder injuries, urethral injuries, and combined injuries.^{141,142} The posterior urethra is firmly attached to the pubis (in males), making it prone to injuries with anterior pelvic ring fractures. Urethral injury associated with pelvic fractures is much less common in females due to the female urethra's short length, mobility, and lack of attachments to the pelvis.¹⁶¹ The bladder is most commonly injured in association with pubic ramus fractures. Injuries to the vagina or rectum may occur in association with pelvic fractures. Most result from the penetration of a bone fragment but may also occur with pubic symphysis diastasis.

Genitourinary tract injuries should be assumed in all patients with pelvic fractures until proven otherwise.

All pelvic fractures should be assumed to have accompanying genitourinary tract injuries until proven otherwise.^{141,142} A retrograde urethrogram may diagnose urethral injuries in patients who have characteristic physical exam findings (Fig. 42). These include blood at the urethral meatus, a high-riding prostate, scrotal

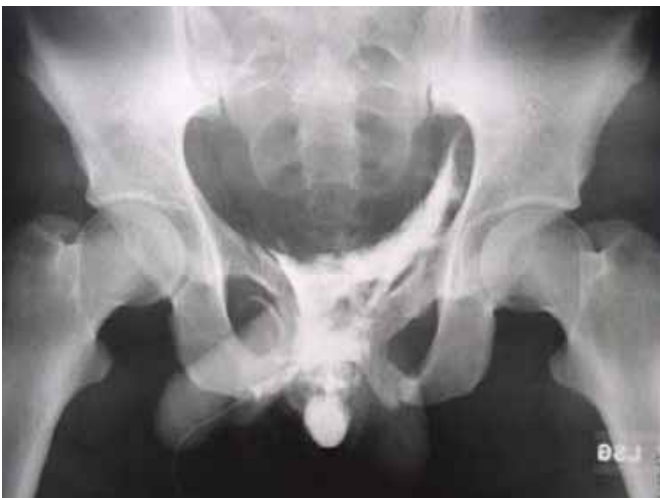

Figure 42. *Retrograde urethrogram demonstrating proximal urethral injury and extraperitoneal extravasation of contrast.*

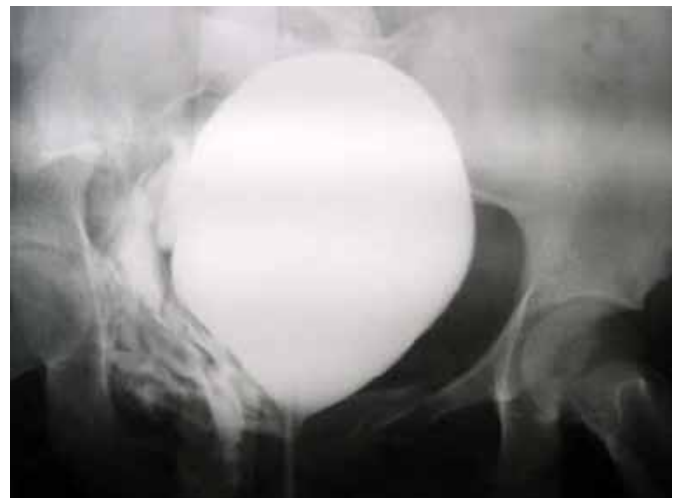

Figure 43. *Retrograde cystogram demonstrating extravasation of contrast from an injured bladder.*

hematoma, an inability to urinate, or difficulty with insertion of a urinary catheter.^{141,142} Physical signs may be absent in some patients with urethral injuries. A retrograde cystogram may help to identify bladder ruptures, which often occur in association with pelvic ring injuries (Fig. 43). Evidence of gross hematuria is an indication for performing a retrograde cystogram. The cystogram may be performed using plain radiography or with CT imaging. The latter is often more convenient and provides more accurate imaging.

Management of Bladder Injuries

Bladder injuries are categorized as intraperitoneal or extraperitoneal. Intraperitoneal injuries are repaired surgically in two-layer fashion with absorbable suture and transurethral catheter drainage. Previous standards included the use of a large-bore suprapubic catheter either alone or in combination with transurethral catheter, but this is no longer recommended due to greater association with complications regardless of degree of bladder injury. In addition, the previous average duration of indwelling suprapubic catheters was 42 days, which with modern treatment standards is now reduced to only 13 days duration of transurethral catheter insertion.^{162,163} These advances along with primary bladder repair approaches have improved outcomes.^{162,163}

The mainstay treatment of extraperitoneal bladder injuries remains nonoperative management with transurethral catheter drainage for 10 to 14 days with follow-up cystogram prior to removal.^{164,165,166} Relative contraindications to nonoperative management of extraperitoneal bladder injuries include bone fragments projecting into the bladder, open pelvic fractures, and bladder injuries associated with rectal perforations.¹⁶⁷

Management of Urethral Injuries

Urethral injury in civilian settings is secondary to blunt trauma, occurring in 10 percent of pelvic fractures.¹⁴¹ However, in combat situations, urethral injury may be associated with pelvic fractures or penetrating gunshot or fragment wounds (Fig. 44). Diagnosis and extent of injury are assessed by retrograde urethrogram. Options for management for partial or complete disruption both include delayed operative reconstruction or primary stenting of injury with a urethral catheter. Either approach appears to have similar complications, impotency rates, and incontinence rates.^{168,169,170,171,172} Consequently, in most cases, bladder drainage, either via retrograde urethral catheter or suprapubic catheter alone, is adequate.

If urethral injury is clinically suspected, urethral integrity can be confirmed by a retrograde urethrogram. Alternatively, a Foley catheter can be gently passed into the urethra. If minimal resistance is encountered the catheter is fully advanced into the bladder and the cuff inflated. If there is difficulty passing the catheter, no further attempts should be made, and a suprapubic tube cystostomy should be performed.

Delayed operative reconstruction requires expertise, which may not be available for host nationals. In these instances, immediate realignment may offer the best chance to reestablish continuity. In the author's experience (AM), based on reports of successful realignment using antegrade cystoscopy, if retrograde urethral catheter placement is unsuccessful, consideration should be given to antegrade urethral catheter placement, particularly if the patient is undergoing laparotomy.^{173,174,175} This procedure is performed by opening the dome of the bladder and passing a Foley catheter antegrade into the urethra. A sterile large-bore Foley catheter is sutured to the antegrade catheter and pulled retrograde into the bladder. The bladder is closed in standard two-layer fashion, and the retrograde urethral catheter can be secured to the foreskin

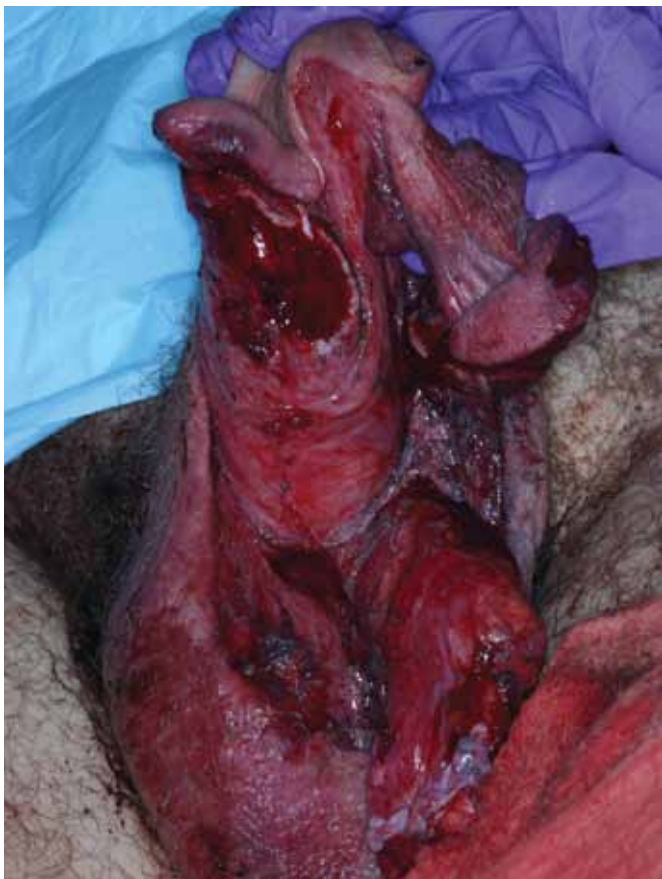
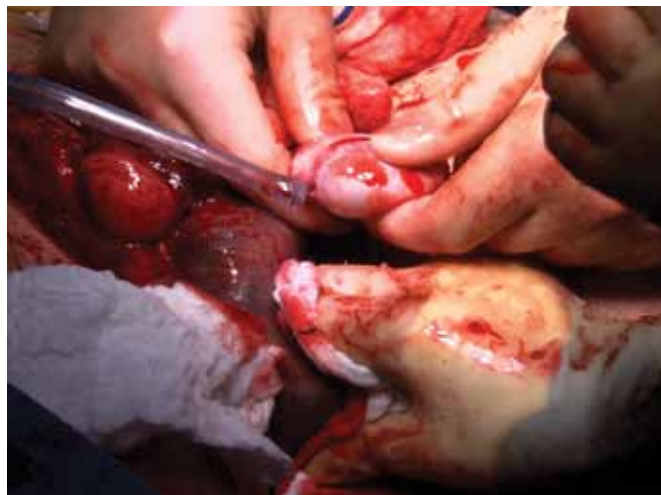
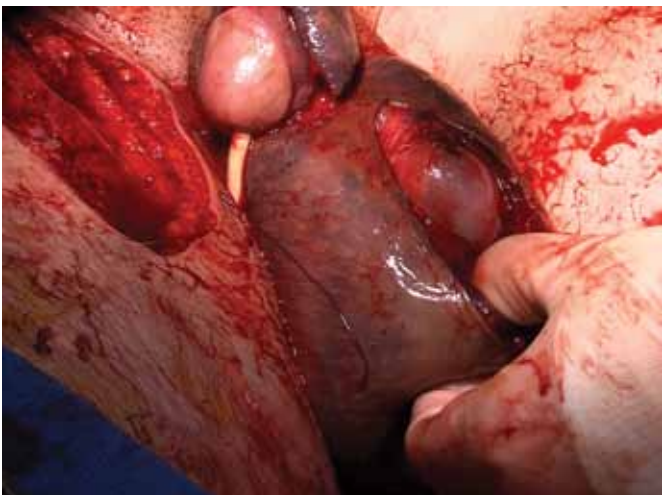Figure 44. (Left) *External genital trauma. There is significant injury to the glans penis and the transected corpus cavernosum is evident. The proximal urethral opening is visible at the base of the wound. A left-sided orchiectomy was performed while the right testicle was repaired.*

Figure 45. (Bottom Left) *Penetrating scrotal injuries require exploration to examine the testicles and spermatic cords for injury.*

Figure 46. (Bottom Right) *Orchiectomy should not be performed unless the testicle is irreparably damaged or its vascular supply is destroyed.*



of the penis to reduce unintentional removal. The catheter should remain in place for a minimum of three weeks with retrograde urethrogram prior to permanent removal of the catheter to ensure continuity is reestablished.

Genitalia Injuries

The management of combat wounds to the penis, scrotum, testes, and spermatic cord comprises hemorrhage control, debridement, and early penile repair to prevent deformity.⁸² Disruption of Buck's fascia in penile injuries requires suture repair to prevent bleeding and long-term penile deformity.

The management of combat wounds to the penis, scrotum, testes, and spermatic cord comprises hemorrhage control, debridement, and early repair to prevent subsequent complications.

The scrotum is very vascular, and extensive scrotal debridement is unnecessary.⁸² Penetrating scrotal injuries require exploration to examine the testes for injury and minimize the risk of hematoma formation (Fig. 45). Management of testicular injuries should be directed toward conservation of tissue with debridement of herniated parenchymal tissue and closure of the tunica albuginea with mattress sutures.^{176,177} Orchiectomy should not be performed unless the testicle is irreparably damaged or its vascular supply is destroyed.¹⁷⁸ The testicle should be replaced in the scrotum, which can be closed primarily within eight hours of injury or closed over a Penrose drain, if longer delays to operative care occur (Fig. 46). If scrotal closure is not possible due to extensive tissue loss, the testicle should be placed in available subcutaneous tissue (e.g., thigh soft-tissue).

Damage Control Summary

Damage control surgery is defined as the rapid initial control of hemorrhage and contamination with packing and temporary closure, followed by resuscitation in the ICU, and subsequent reexploration and definitive repair once normal physiology has been restored. Patients requiring damage control procedures are a higher acuity patient population in whom temporizing procedures to control hemorrhage and contamination improve survival. Damage control techniques are both feasible and effective on the battlefield. This damage control paradigm challenges surgeons in resource-constrained combat environments to have a low threshold to perform damage control procedures in order to mitigate the deleterious consequences of the challenging lethal triad of hypothermia, coagulopathy, and acidosis.

References

1. Helling TS, McNabney WK. The role of amputation in the management of battlefield casualties: a history of two millennia. *J Trauma* 2000;49(5):930-939.
2. Larrey DJ. *Memoires de chirurgicales militaire et campagnes*. Paris; 1812.
3. US War Department. The war of the rebellion: a compilation of the official records of the Union and Confederate Armies. Washington, DC: US Government Printing Office 1880-1901;19(1.27):106-117.
4. Brewer LA III. The contributions of the Second Auxiliary Surgical Group to military surgery during World War II with special reference to thoracic surgery. *Ann Surg* 1983;197(3):318-326.
5. Jones EL, Peters AF, Gasior RM. Early management of battle casualties in Vietnam. An analysis of 1,011 consecutive cases treated at a mobile army surgical hospital. *Arch Surg* 1968;97(1):1-15.
6. Stone HH, Strom PR, Mullins RJ. Management of the major coagulopathy with onset during laparotomy. *Ann Surg* 1983;197(5):532-535.
7. Rotondo MF, Schwab CW, McGonigal MD, et al. 'Damage control': an approach for improved survival in exsanguinating penetrating abdominal injury. *J Trauma* 1993;35(3):375-382.
8. Hirshberg A, Mattox KL. Planned reoperation for severe trauma. *Ann Surg* 1995;222(1):3-8.
9. Moore EE, Thomas G. Orr Memorial Lecture. Staged laparotomy for the hypothermia, acidosis and coagulopathy syndrome. *Am J Surg* 1996;172(5):405-410.
10. Cuello JI, Cryer HG, Miller FB, et al. Packing and planned reexploration for hepatic and retroperitoneal hemorrhage: critical refinements of a useful technique. *J Trauma* 1990;30(8):1007-1011; discussion 1011-1013.
11. Hildebrand F, Giannoudis P, Krettek C, et al. Damage control: extremities. *Injury* 2004;35(7):678-689.
12. Giannoudis PV, Pape HC. Damage control orthopaedics in unstable pelvic ring injuries. *Injury* 2004;35(7):671-677.
13. Rosenfeld JV. Damage control neurosurgery. *Injury* 2004;35(7):655-660.
14. Reilly PM, Rotondo MF, Carpenter JP, et al. Temporary vascular continuity during damage control: intraluminal shunting for proximal superior mesenteric artery injury. *J Trauma* 1995;39(4):757-760.
15. Rotondo MF, Zonies DH. The damage control sequence and underlying logic. *Surg Clin North Am* 1997;77(4):761-777.

16. Feliciano DV, Mattox KL, Burch JM, et al. Packing for control of hepatic hemorrhage. *J Trauma* 1986;26(8):738-743.
17. Cogbill TH, Moore EE, Jurkovich GJ, et al. Severe hepatic trauma: a multi-center experience with 1,335 liver injuries. *J Trauma* 1988;28(10):1433-1438.
18. Beal SL. Fatal hepatic hemorrhage: an unresolved problem in the management of complex liver injuries. *J Trauma* 1990;30(2):163-169.
19. Burch JM, Ortiz VB, Richardson RJ, et al. Abbreviated laparotomy and planned reoperation for critically injured patients. *Ann Surg* 1992;215(5):476-483; discussion 483-484.
20. Morris JA Jr, Eddy VA, Blinman TA, et al. The staged celiotomy for trauma. Issues in unpacking and reconstruction. *Ann Surg* 1993;217(5):576-584; discussion 584-586.
21. Hirshberg A, Wall MJ Jr, Mattox KL. Planned reoperation for trauma: a two year experience with 124 consecutive patients. *J Trauma* 1994;37(3):365-369.
22. Garrison J, Richardson JD, Hilakos AS, et al. Predicting the need to pack early for severe intra-abdominal hemorrhage. *J Trauma* 1996;40(6):923-927; discussion 927-929.
23. Blackbourne LH. Combat damage control surgery. *Crit Care Med* 2008;36(7 Suppl):S304-310.
24. Chambers LW, Rhee P, Baker BC, et al. Initial experience of the US Marine Corps forward resuscitative surgical system during Operation Iraqi Freedom. *Arch Surg* 2005;140(1):26-32.
25. Beekley AC, Watts DM. Combat trauma experience with the United States Army 102nd Forward Surgical Team in Afghanistan. *Am J Surg* 2004;187(5):652-654.
26. Patel TH, Wenner KA, Price SA, et al. A U.S. Army Forward Surgical Team's experience in Operation Iraqi Freedom. *J Trauma* 2004;57(2):201-207.
27. Place RJ, Rush RM, Arrington ED. Forward surgical team (FST) workload in a special operations environment: the 250th FST in Operation Enduring Freedom. *Curr Surg* 2003;60(4):418-422.
28. Borgman MA, Spinella PC, Perkins JG, et al. The ratio of blood products transfused affects mortality in patients receiving massive transfusions at a combat support hospital. *J Trauma* 2007;63(4):805-813.
29. Spinella PC, Perkins JG, Grathwohl KW, et al. Effect of plasma and red blood cell transfusions on survival in patients with combat related traumatic injuries. *J Trauma* 2008;64(2 Suppl):S69-77; discussion S77-78.
30. Spinella PC, Perkins JG, Grathwohl KW, et al. 31st CSH Research Working Group. Fresh whole blood transfusions in coalition military, foreign national, and enemy combatant patients during Operation Iraqi Freedom at a U.S. combat support hospital. *World J Surg* 2008;32(1):2-6. Epub 2007.

31. Beninati W, Meyer MT, Carter TE. The critical care air transport program. *Crit Care Med* 2008;36(7 Suppl):S370-376.
32. Bridges E, Evers K. Wartime critical care air transport. *Mil Med* 2009;174(4):370-375.
33. Rice DH, Kotti G, Beninati W. Clinical review: critical care transport and austere critical care. *Crit Care* 2008;12(2):207.
34. Working Group, Ad Hoc Subcommittee on Outcomes, American College of Surgeons. Committee on Trauma. Practice management guidelines for emergency department thoracotomy. *J Am Coll Surg* 2001;193(3):303-309.
35. Rhee PM, Acosta J, Bridgeman A, et al. Survival after emergency department thoracotomy: review of published data from the past 25 years. *J Am Coll Surg* 2000;190(3):288-298.
36. Edens JW, Beekley AC, Chung KK, et al. Longterm outcomes after combat casualty emergency department thoracotomy. *J Am Coll Surg* 2009;209(2):188-197.
37. Macho JR, Markison RE, Schechter WP. Cardiac stapling in the management of penetrating injuries of the heart: rapid control of hemorrhage and decreased risk of personal contamination. *J Trauma* 1993;34(5):711-715; discussion 715-716.
38. Evans BJ, Hornick P. Use of skin stapler for penetrating cardiac injury. *Ann R Coll Surg Eng* 2006;88(4):413-414.
39. Bowman MR, King RM. Comparison of staples and sutures for cardiorrhaphy in traumatic puncture wounds of the heart. *J Emerg Med* 1996;14(5):615-618.
40. Wilson SM, Au FC. In extremis use of a Foley catheter in a cardiac stab wound. *J Trauma* 1986;26(4):400-402.
41. Moore EE, Mattox KL, Feliciano DV. Indication for thoracotomy. In: Moore EE, Mattox KL, Feliciano DV, editors. *Trauma manual*. 4th ed. McGraw-Hill; 2003. p. 161-169.
42. Moore EE, Mattox KL, Feliciano DV. Injury to the thoracic great vessels. In: Moore EE, Mattox KL, Feliciano DV, editors. *Trauma manual*. 4th ed. McGraw-Hill; 2003. p. 202-213.
43. Martin MJ, McDonald JM, Mullenix PS, et al. Operative management and outcomes of traumatic lung resection. *J Am Coll Surg* 2006;203(3):336-344. Epub 2006.
44. Richardson JD. Outcome of tracheobronchial injuries: a long-term perspective. *J Trauma* 2004;56(1):30-36.
45. Bowling R, Mavroudis C, Richardson JD, et al. Emergency pneumonectomy for penetrating and blunt trauma. *Am Surg* 1985;51(3):136-139.

46. Wilson A, Wall MJ Jr, Maxson R, et al. The pulmonary hilum twist as a thoracic damage control procedure. *Am J Surg* 2003;186(1):49-52.
47. Bryant AS, Cerfolio RJ. Esophageal trauma. *Thorac Surg Clin* 2007;17(1):63-72.
48. Phelan HA, Patterson SG, Hassan MO, et al. Thoracic damage-control operation: principles, techniques, and definitive repair. *J Am Coll Surg* 2006;203(6):933-941.
49. Rotondo MF, Bard MR. Damage control surgery for thoracic injuries. *Injury* 2004;35(7):649-654.
50. US Department of Defense (US DoD). Face and Neck Injuries. In: *Emergency War Surgery, Third United States Revision*. Washington, DC: Department of the Army, Office of the Surgeon General, Borden Institute; 2004. p. 13.1-13.20.
51. Demetriades D, Theodorou D, Cornwell E, et al. Evaluation of penetrating injuries of the neck: prospective study of 223 patients. *World J Surg* 1997;21(1):41-47; discussion 47-48.
52. Brywczyński JJ, Barrett TW, Lyon JA, et al. Management of penetrating neck injury in the emergency department: a structured literature review. *Emerg Med J* 2008;25(11):711-715.
53. Ivatury RR, Stoner MC. Penetrating cervical vascular injuries. In: Rich NM, Mattox KL, Hirschberg A, editors. *Vascular trauma*. 2nd ed. Philadelphia, PA: Elsevier-Saunders; 2004. p. 223-240.
54. du Toit DE, van Schalkwyk GD, Wade SA, et al. Neurologic outcome after penetrating extracranial arterial trauma. *J Vasc Surg* 2003;38(2):257-262.
55. Moore WS. *Vascular surgery: a comprehensive review*. 6th ed. Philadelphia, PA: Elsevier-Saunders; 2002. p. 684-686.
56. McLaughlin DF, Niles SE, Salinas J, et al. A predictive model for massive transfusion in combat casualty patients. *J Trauma* 2008;64(2 Suppl):S57-63; discussion S63.
57. Karmy-Jones RC, Salerno C. Thoracic vascular trauma. In: Zelenock GB, Huber TS, Messina LM, editors. *Mastery of vascular and endovascular surgery*. Philadelphia, PA: Lippincott Williams & Wilkins; 2006. p. 629-635.
58. Feliciano DV, Pachter JL. Hepatic trauma revisited. *Curr Probl Surg* 1989;26(7):453-524.
59. Buckman RF, Pathak AS, Badellino MM, et al. Injuries to the inferior vena cava. *Surg Clin North Am* 2001;81(6):1431-1437.
60. Dente CJ, Feliciano DV. Abdominal vascular injury. In: Moore EE, Mattox KL, Feliciano DV, editors. *Trauma manual*. 6th ed. McGraw-Hill; 2008. p. 746-747.
61. Votanopoulos KI, Welsh FJ, Mattox KL. Suprarenal inferior vena cava ligation: a rare survivor. *J*

Trauma 2009;67(6):E179-180.

62. Ivy ME, Possenti P, Atweh N, et al. Ligation of the suprarenal vena cava after a gunshot wound. J Trauma 1998;45(3):630-632.

63. Mays ET, Conti S, Fallahzadeh H, et al. Hepatic artery ligation. Surgery 1979;86(4):536-543.

64. Mays ET. Options in treating trauma to the liver. Surg Annu 1980;12:103-121.

65. Trunkey DD, Shires GT, McClelland R. Management of liver trauma in 811 consecutive patients. Ann Surg 1974;179(5):722-728.

66. Moore EE. Edgar J. Poth Lecture. Critical decisions in the management of hepatic trauma. Am J Surg 1984;148(6):712-716.

67. Feliciano DV, Mattox KL, Jordan GL Jr, et al. Management of 1000 consecutive cases of hepatic trauma (1979-1984). Ann Surg 1986;204(4):438-445.

68. Pachter HL, Spencer FC, Hofstetter SR, et al. Significant trends in the treatment of hepatic trauma. Experience with 411 injuries. Ann Surg 1992;215(5):492-500; discussion 500-502.

69. Fabian TC, Stone HH. Arrest of severe liver hemorrhage by an omental pack. South Med J 1980;73(11):1487-1490.

70. Polanco P, Leon S, Pineda J, et al. Hepatic resection in the management of complex injury to the liver. J Trauma 2008;65(6):1264-1269; discussion 1269-1270.

71. Asensio JA, Petrone P, Roldán G, et al. Pancreatic and duodenal injuries. complex and lethal. Scand J Surg 2002;91(1):81-86.

72. Bokhari F, Phelan H, Holevar M, et al. EAST guidelines for the diagnosis and management of pancreatic trauma. Eastern Association for the Surgery of Trauma (EAST) 2009 [cited 2010 May 26]. Available from: URL: <http://www.east.org/tpg/pancreas.pdf>.

73. Degiannis E, Levy RD, Potokar T, et al. Distal pancreatectomy for gunshot injuries of the distal pancreas. Br J Surg 1995;82(9):1240-1242.

74. Degiannis E, Boffard K. Duodenal injuries. Br J Surg 2000;87(11):1473-1479.

75. Jansen M, Du Toit DE, Warren BL. Duodenal injuries: surgical management adapted to circumstances. Injury 2002;33(7):611-615.

76. Voelzke BB, McAninch JW. The current management of renal injuries. Am Surg 2008;74(8):667-678.

77. Master VA, McAninch JW. Operative management of renal injuries: parenchymal and vascular. *Urol Clin North Am* 2006;33(1):21-31, v-vi.
78. Gonzalez RP, Falimirski M, Holevar MR, et al. Surgical management of renal trauma: is vascular control necessary? *J Trauma* 1999;47(6):1039-1042; discussion 1042-1044.
79. Brandes SB, McAninch JW. Reconstructive surgery for trauma of the upper urinary tract. *Urol Clin North Am* 1999;26(1):183-199.
80. Holden S, Hicks CC, O'Brien DP, et al. Gunshot wounds of the ureter: a 15-year review of 63 consecutive cases. *J Urol* 1976;116(5):562-564.
81. Walker JA. Injuries of the ureter due to external violence. *J Urol* 1969;102(4):410-413.
82. US Department of Defense (US DoD). Genitourinary Tract Injuries. In: *Emergency War Surgery, Third United States Revision*. Washington, DC: Department of the Army, Office of the Surgeon General, Borden Institute; 2004. p. 18.1-18.13.
83. Velmahos GC, Degiannis E, Wells M, et al. Penetrating ureteral injuries: the impact of associated injuries on management. *Am Surg* 1996;62(6):461-468.
84. Perez-Brayfield MR, Keane TE, Krishnan A, et al. Gunshot wounds to the ureter: a 40-year experience at Grady Memorial Hospital. *J Urol* 2001;166(1):119-121.
85. Franko ER, Ivatury RR, Schwalb DM. Combined penetrating rectal and genitourinary injuries: a challenge in management. *J Trauma* 1993;34(3):347-353.
86. Alonso M, Brathwaite C, Garcia V, et al. Practice management guidelines for the nonoperative management of blunt injury to the liver and spleen. Eastern Association for the Surgery of Trauma (EAST), 2003 [cited 2010 May 26]. Available from: URL: <http://www.east.org/tpg/livspleen.pdf>.
87. Wei B, Hemmila MR, Arbabi S, et al. Angioembolization reduces operative intervention for blunt splenic injury. *J Trauma* 2008;64(6):1472-1477.
88. Achneck HE, Sileshi B, Jamiolkowski RM, et al. A comprehensive review of topical hemostatic agents: efficacy and recommendations for use. *Ann Surg* 2010;251(2):217-228.
89. Vertrees A, Wakefield M, Pickett C, et al. Outcomes of primary repair and primary anastomosis in war-related colon injuries. *J Trauma* 2009;66(5):1286-1291; discussion 1291-1293.
90. Vertrees A, Greer L, Pickett C, et al. Modern management of complex open abdominal wounds of war: a 5-year experience. *J Am Coll Surg* 2008;207(6):801-809.
91. Burch JM, Feliciano DV, Mattox KL. Colostomy and drainage for civilian rectal injuries: is that all? *Ann Surg* 1989;209(5):600-610; discussion 610-611.

92. Gonzalez RP, Falimirski ME, Holevar MR. The role of presacral drainage in the management of penetrating rectal injuries. *J Trauma* 1998;45(4):656-661.
93. Steele SR, Wolcott KE, Mullenix SP, et al. Colon and rectal injuries during Operation Iraqi Freedom: are there any changing trends in management or outcome? *Dis Colon Rectum* 2007;50(6):870-877.
94. Sugrue M, D'Amours SK, Joshipura M. Damage control surgery and the abdomen. *Injury* 2004;35(7):642-648.
95. US Department of Defense (US DoD). Abdominal Injuries. In: *Emergency War Surgery, Third United States Revision*. Washington, DC: Department of the Army, Office of the Surgeon General, Borden Institute; 2004. p. 17.1-17.16.
96. Thal E, Eastridge B, Milhoan R. Operative exposure of abdominal injuries and closure of the abdomen. In: Wilmore, D editor. *ACS Surgery*. WebMD; 2002.
97. Offner PJ, de Souza AL, Moore EE, et al. Avoidance of abdominal compartment syndrome in damage-control laparotomy after trauma. *Arch Surg* 2001;136(6):676-681.
98. Harrahill M. Intra-abdominal pressure monitoring. *J Emerg Nurs* 1998;24(5):465-466.
99. Lozen Y. Intraabdominal hypertension and abdominal compartment syndrome in trauma: pathophysiology and interventions. *AACN Clin Issues* 1999;10(1):104-112.
100. Schein M, Wittmann DH, Aprahamian CC, et al. The abdominal compartment syndrome: the physiological and clinical consequences of elevated intra-abdominal pressure. *J Am Coll Surg* 1995;180(6):745-753.
101. Saggi BH, Sugerman HJ, Ivatury RR, et al. Abdominal compartment syndrome. *J Trauma* 1998;45(3):597-609.
102. Ivatury RR, Diebel L, Porter JM, et al. Intra-abdominal hypertension and the abdominal compartment syndrome. *Surg Clin North Am* 1997;77(4):783-800.
103. Meldrum DR, Moore FA, Moore EE, et al. Prospective characterization and selective management of the abdominal compartment syndrome. *Am J Surg* 1997;174(6):667-672.
104. Mayberry JC, Goldman RK, Mullins RJ, et al. Surveyed opinion of American trauma surgeons on the prevention of the abdominal compartment syndrome. *J Trauma* 1999;47(3):509-513.
105. Rich NM, Rhee P. An historical tour of vascular injury management: from its inception to the new millennium. *Surg Clin North Am* 2001;81(6):1199-1215.
106. Rich N. Military surgery: "bullets and blood vessels." *Surg Clin North Am* 1978;58(5):995-1003.

107. Rich NM. Vascular trauma. *Surg Clin North Am* 1973;53(6):1367-1392.
108. DeBakey ME, Simeone FA. Battle injuries of the arteries in World War II: an analysis of 2,471 cases. *Ann Surg* 1946;123(4):534-579.
109. Hughes CW. The primary repair of wounds of major arteries; an analysis of experience in Korea in 1953. *Ann Surg* 1955;141(3):297-303.
110. Fox CJ, Gillespie DL, Cox ED, et al. Damage control resuscitation for vascular surgery in a combat support hospital. *J Trauma* 2008;65(1):1-9.
111. Fox CJ, Gillespie DL, Cox ED, et al. The effectiveness of a damage control resuscitation strategy for vascular injury in a combat support hospital: results of a case control study. *J Trauma* 2008;64(2 Suppl):S99-106; discussion S106-107.
112. Clouse WD, Rasmussen TE, Peck MA, et al. In-theater management of vascular injury: 2 years of the Balad Vascular Registry. *J Am Coll Surg* 2007;204(4):625-632.
113. Sohn VY, Arthurs ZM, Herbert GS, et al. Demographics, treatment, and early outcomes in penetrating vascular combat trauma. *Arch Surg* 2008;143(8):783-787.
114. Rasmussen TE, Clouse WD, Jenkins DH, et al. The use of temporary vascular shunts as a damage control adjunct in the management of wartime vascular injury. *J Trauma* 2006;61(1):8-12; discussion 12-15.
115. Dennis JW, Frykberg ER, Crump JM, et al. New perspectives on the management of penetrating trauma in proximity to major limb arteries. *J Vasc Surg* 1990;11(1):84-92; discussion 92-93.
116. Frykberg ER, Crump JM, Vines FS, et al. A reassessment of the role of arteriography in penetrating proximity extremity trauma: a prospective study. *J Trauma* 1989;29(8):1041-1050; discussion 1050-1052.
117. Francis H III, Thal ER, Weigelt JA, et al. Vascular proximity: is it a valid indication for arteriography in asymptomatic patients? *J Trauma* 1991;31(4):512-514.
118. Johnson ON III, Fox CJ, White P, et al. Physical exam and occult post-traumatic vascular lesions: implications for the evaluation and management of arterial injuries in modern warfare in the endovascular era. *J Cardiovasc Surg (Torino)* 2007;48(5):581-586.
119. Fox CJ, Gillespie DL, Weber MA, et al. Delayed evaluation of combat-related penetrating neck trauma. *J Vasc Surg* 2006;44(1):86-93.
120. Rasmussen TE, Clouse WD, Jenkins DH, et al. Echelons of care and the management of wartime vascular injury: a report from the 332nd EMDG/Air Force Theater Hospital, Balad Air Base, Iraq. *Perspect Vasc Surg Endovasc Ther* 2006;18(2):91-99.

121. Chambers LW, Green DJ, Sample K, et al. Tactical surgical intervention with temporary shunting of peripheral vascular trauma sustained during Operation Iraqi Freedom: one unit's experience. *J Trauma* 2006;61(4):824-830.
122. Taller J, Kamdar JP, Greene JA, et al. Temporary vascular shunts as initial treatment of proximal extremity vascular injuries during combat operations: the new standard of care at Echelon II facilities? *J Trauma* 2008;65(3):595-603.
123. Zouris JM, Walker GJ, Dye J, et al. Wounding patterns for U.S. Marines and sailors during Operation Iraqi Freedom, major combat phase. *Mil Med* 2006;171(3):246-252.
124. Gifford SM, Eliason JL, Clouse WD, et al. Early versus delayed restoration of flow with a temporary vascular shunt reduces circulating markers of injury in a porcine model. *J Trauma* 2009;67(2):259-265.
125. Woodward EB, Clouse WD, Eliason JL, et al. Penetrating femoropopliteal injury during modern warfare: experience of the Balad Vascular Registry. *J Vasc Surg* 2008;47(6):1259-1264; discussion 1264-1265.
126. Gifford SM, Aidinian G, Clouse WD, et al. Effect of temporary shunting on extremity vascular injury: an outcome analysis from the Global War on Terror vascular injury initiative. *J Vasc Surg* 2009;50(3):549-555.
127. Fox CJ, Gillespie DL, O'Donnell SD, et al. Contemporary management of wartime vascular trauma. *J Vasc Surg* 2005;41(4):638-644.
128. US Department of Defense (US DoD). Vascular Injuries. In: *Emergency War Surgery, Third United States Revision*. Washington, DC: Department of the Army, Office of the Surgeon General, Borden Institute; 2004. p. 27.1-27.9.
129. Dawson DL, Putnam AT, Light JT, et al. Temporary arterial shunts to maintain limb perfusion after arterial injury: an animal study. *J Trauma* 1999;47(1):64-71.
130. Quan RW, Gillespie DL, Stuart RP, et al. The effect of vein repair on the risk of venous thromboembolic events: a review of more than 100 traumatic military venous injuries. *J Vasc Surg* 2008;47(3):571-577.
131. Kragh JF Jr, Walters TJ, Baer DG, et al. Survival with emergency tourniquet use to stop bleeding in major limb trauma. *Ann Surg* 2009;249(1):1-7.
132. Kragh JF Jr, Walters TJ, Baer DG, et al. Practical use of emergency tourniquets to stop bleeding in major limb trauma. *J Trauma* 2008;64(2 Suppl):S38-49; discussion S49-50.
133. Perry MO. Vascular trauma. *Adv Surg* 1995;28:59-70.
134. Thal ER. Vascular injuries of the extremities. In: Rutherford RB, editor. *Vascular surgery*. 4th ed. Philadelphia, PA: WB Saunders; 1995. p. 713-735.

135. Perry MO, Bongard F. Vascular trauma. In: Moore WS. Vascular surgery a comprehensive review. 6th Ed. WB Saunders; 2002. p. 648-666.
136. Joint Theater Trauma System (JTTS) Clinical Practice Guideline. Vascular injury. 2008 Nov 07 [cited 2010 May 26]. Available from: URL: <http://www.usaisr.amedd.army.mil/cpgs.html>.
137. Dalal SA, Burgess AR, Siegel JH, et al. Pelvic fracture in multiple trauma: classification by mechanism is key to pattern of organ injury, resuscitative requirements and outcome. *J Trauma* 1989;29(7):981-1000; discussion 1000-1002.
138. Burgess AR, Eastridge BJ, Young JW, et al. Pelvic ring disruptions: effective classification system and treatment protocols. *J Trauma* 1990;30(7):848-856.
139. Eastridge BJ, Starr A, Minei JP, et al. The importance of fracture pattern in guiding therapeutic decision-making in patients with hemorrhagic shock and pelvic ring disruptions. *J Trauma* 2002;53(3):446-450; discussion 450-451.
140. Papakostidis C, Giannoudis PV. Pelvic ring injuries with haemodynamic instability: efficacy of pelvic packing, a systematic review. *Injury* 2009;40(Suppl 4):S53-61.
141. Brandes S, Borrelli JJ Jr. Pelvic fracture and associated urologic injuries. *World J Surg* 2001;25(12):1578-1587.
142. Lowe MA, Mason JT, Luna GK, et al. Risk factors for urethral injuries in men with traumatic pelvic fractures. *J Urol* 1988;140(3):506-507.
143. Faringer PD, Mullins RJ, Feliciano PD, et al. Selective fecal diversion in complex open pelvic fractures from blunt trauma. *Arch Surg* 1994;129(9):958-963; discussion 963-964.
144. Ham SJ, van Walsum AD, Vierhout PA. Predictive value of the hip flexion test for fractures of the pelvis. *Injury* 1996;27(8):543-544.
145. Resnik CS, Stackhouse DJ, Shanmuganathan K, et al. Diagnosis of pelvic fractures in patients with acute pelvic trauma: efficacy of plain radiographs. *AJR Am J Roentgenol* 1992;158(1):109-112.
146. Falchi M, Rollandi GA. CT of pelvic fractures. *Eur J Radiol* 2004;50(1):96-105.
147. Theumann NH, Verdon JP, Mouhsine E, et al. Traumatic injuries: imaging of pelvic fractures. *Eur Radiol* 2002;12(6):1312-1330.
148. Cerva DS Jr, Mirvis SE, Shanmuganathan K, et al. Detection of bleeding in patients with major pelvic fractures: value of contrast-enhanced CT. *AJR Am J Roentgenol* 1996;166(1):131-135.
149. Velmahos GC, Chahwan S, Hanks SE, et al. Angiographic embolization of bilateral internal iliac arteries to control life-threatening hemorrhage after blunt trauma to the pelvis. *Am Surg* 2000;66(9):858-862.

150. Velmahos GC, Toutouzas KG, Vassiliu P, et al. A prospective study on the safety and efficacy of angiographic embolization for pelvic and visceral injuries. *J Trauma* 2002;53(2):303-308.
151. Agolini SF, Shah K, Jaffe J, et al. Arterial embolization is a rapid and effective technique for controlling pelvic fracture hemorrhage. *J Trauma* 1997;43(3):395-399.
152. Bottlang M, Simpson T, Sigg J, et al. Noninvasive reduction of open-book pelvic fractures by circumferential compression. *J Orthop Trauma* 2002;16(6):367-373.
153. Rommens PM, Hofmann A, Hessmann MH. Management of acute hemorrhage in pelvic trauma: an overview. *Eur J Trauma Emerg Surg* 2010;2:91-99.
154. Eastridge BJ. Butt binder. *J Trauma* 2007;62(6 Suppl):S32.
155. Simpson T, Krieg JC, Heuer F, et al. Stabilization of pelvic ring disruptions with a circumferential sheet. *J Trauma* 2002;52(1):158-161.
156. Tucker MC, Nork SE, Simonian PT, et al. Simple anterior pelvic external fixation. *J Trauma* 2000;49(6):989-994.
157. Cothren CC, Osborn PM, Moore EE, et al. Preperitoneal pelvic packing for hemodynamically unstable pelvic fractures: a paradigm shift. *J Trauma* 2007;62(4):834-839; discussion 839-842.
158. Osborn PM, Smith WR, Moore EE, et al. Direct retroperitoneal pelvic packing versus pelvic angiography: a comparison of two management protocols for haemodynamically unstable pelvic fractures. *Injury* 2009;40(1):54-60. Epub 2008.
159. Grotz MR, Allami MK, Harwood P, et al. Open pelvic fractures: epidemiology, current concepts of management and outcome. *Injury* 2005;36(1):1-13.
160. Gerhardt RT, Matthews JM, Sullivan SG. The effect of systemic antibiotic prophylaxis and wound irrigation on penetrating combat wounds in a return-to-duty population. *Prehosp Emerg Care* 2009;13(4):500-504.
161. Venn SN, Greenwell TJ, Mundy AR. Pelvic fracture injuries of the female urethra. *BJU International* 1999;83(6):626-630.
162. Thomae KR, Kilambi NK, Poole GV. Method of urinary diversion in nonurethral traumatic bladder injuries: retrospective analysis of 70 cases. *Am Surg* 1998;64(1):77-80.
163. Volpe MA, Pachter EM, Scalea TM, et al. Is there a difference in outcome when treating traumatic intraperitoneal bladder rupture with or without a suprapubic tube? *J Urol* 1999;161(4):1103-1105.
164. Corriere JN Jr, Sandler CM. Management of the ruptured bladder: seven years of experience with 111 cases. *J Trauma* 1986;26(9):830-833.

165. Cass AS, Luxenberg M. Features of 164 bladder ruptures. *J Urol* 1987;138(4):743-745.
166. Corriere JN Jr, Sandler CM. Mechanisms of injury, patterns of extravasation and management of extraperitoneal bladder rupture due to blunt trauma. *J Urol* 1988;139(1):43-44.
167. Cass AS, Luxenberg M. Management of extraperitoneal ruptures of bladder caused by external trauma. *Urology* 1989;33(3):179-183.
168. Morehouse DD, Mackinnon KJ. Management of prostatomembranous urethral disruption: 13-year experience. *J Urol* 1980;123(2):173-174.
169. Follis HW, Koch MO, McDougal WS. Immediate management of prostatomembranous urethral disruptions. *J Urol* 1992;147(5):1259-1262.
170. Herschorn S, Thijssen A, Radomski SB. The value of immediate or early catheterization of the traumatized posterior urethra. *J Urol* 1992;148(5):1428-1431.
171. Kotkin L, Koch MO. Impotence and incontinence after immediate realignment of posterior urethral trauma: result of injury or management? *J Urol* 1996;155(5):1600-1603.
172. Elliott DS, Barrett DM. Long-term followup and evaluation of primary realignment of posterior urethral disruptions. *J Urol* 1997;157(3):814-816.
173. Koraitim MM. Pelvic fracture urethral injuries: evaluation of various methods of management. *J Urol* 1996;156(4):1288-1291.
174. Moudoni, SM, Patard JJ, Manunta A, et al. Early endoscopic realignment of post-traumatic posterior urethral disruption. *Urology* 2001;57(4):628-632.
175. Chapple C, Barbagli G, Jordan G, et al. Consensus statement on urethral trauma. *BJU Int* 2004;93(9):1195-1202.
176. Brandes SB, Buckman RF, Chelsky MJ, et al. External genitalia gunshot wounds: a ten-year experience with fifty-six cases. *J Trauma* 1995;39(2):266-271; discussion 271-272.
177. Cline KJ, Mata JA, Venable DD, et al. Penetrating trauma to the male external genitalia. *J Trauma* 1998;44(3):492-494.
178. Yap SA, DeLair SM, Ellison LM. Novel technique for testicular salvage after combat-related genitourinary injury. *Urology* 2006;68(4):890.e11-12.

