

# EXTREMITY INJURY

## *Chapter 9*

---

### **Contributing Authors**

John F. Kragh, Jr., MD, COL, MC, US Army

Jess M. Kirby, MD, MAJ, MC, US Army

James R. Ficke, MD, COL, MC, US Army

All figures and tables included in this chapter have been used with permission from Pelagique, LLC, the UCLA Center for International Medicine, and/or the authors, unless otherwise noted.

Use of imagery from the Defense Imagery Management Operations Center (DIMOC) does not imply or constitute Department of Defense (DOD) endorsement of this company, its products, or services.

**Disclaimer**

The opinions and views expressed herein belong solely to those of the authors. They are not nor should they be implied as being endorsed by the United States Uniformed Services University of the Health Sciences, Department of the Army, Department of the Navy, Department of the Air Force, Department of Defense, or any other branch of the federal government.

# Table of Contents

<b>Introduction.....</b>	<b>397</b>
<b>Burden of Extremity Injury.....</b>	<b>398</b>
<b>Extremity Injury-Associated Mortality .....</b>	<b>400</b>
<b>Emergency Tourniquet Application .....</b>	<b>403</b>
<b>Limb Compartment Syndrome.....</b>	<b>405</b>
<i>Introduction .....</i>	<i>406</i>
<i>Definition, Mechanisms, and Risk.....</i>	<i>406</i>
<i>Clinical Findings.....</i>	<i>407</i>
<i>Diagnosis.....</i>	<i>408</i>
<i>Treatment .....</i>	<i>409</i>
Fasciotomy Techniques .....	412
<i>Lower Leg Fasciotomy.....</i>	<i>412</i>
<i>Thigh Fasciotomy .....</i>	<i>413</i>
<i>Upper Arm Fasciotomy.....</i>	<i>413</i>
<i>Forearm Fasciotomy .....</i>	<i>413</i>
<i>Hand Compartment Fasciotomy.....</i>	<i>413</i>
<i>Conclusions.....</i>	<i>413</i>
<b>Traumatic Limb Amputations .....</b>	<b>415</b>
<i>Introduction .....</i>	<i>415</i>
<i>Initial Assessment .....</i>	<i>415</i>
<i>Initial Resuscitation .....</i>	<i>417</i>
Primary (Completion) Amputation .....	417
Wound Debridement .....	417
Fasciotomy .....	419
Surgical Amputation and Wound Care .....	420
Delayed Amputation .....	420
<i>Rehabilitation .....</i>	<i>422</i>
<b>Combat Casualty Wound Care.....</b>	<b>422</b>
<i>Introduction .....</i>	<i>423</i>
<i>Extremity Resuscitation and Wound Management .....</i>	<i>423</i>
<i>Special Wounds.....</i>	<i>424</i>
Vascular Injury.....	424
Muscle, Tendon, and Ligament .....	424
Open Joint Injury.....	425
Nerve Repair.....	426
<b>War Wound Closure.....</b>	<b>426</b>
<i>Introduction .....</i>	<i>427</i>

<i>Timing of Wound Closure .....</i>	<b>427</b>
<i>Wound Closure Techniques.....</i>	<b>427</b>
Wound Coverage.....	430
<b>Preventing War Wound Infections .....</b>	<b>431</b>
<i>Wound Debridement and Irrigation .....</i>	<b>431</b>
Introduction .....	431
Wound Flora .....	431
Wound Irrigation .....	432
<i>Timing of Irrigation .....</i>	<i>432</i>
<i>Volume of Irrigation.....</i>	<i>432</i>
<i>Irrigants and Additives .....</i>	<i>432</i>
<i>Irrigation Devices.....</i>	<i>432</i>
Wet-to-Dry Dressing Debridement.....	433
Surgical Wound Debridement .....	434
<i>Assessing Muscle Viability .....</i>	<i>437</i>
<i>Massive Wounds (Upper Thigh and Buttock).....</i>	<i>437</i>
<i>Negative-Pressure Wound Dressings .....</i>	<b>438</b>
<i>Antibiotic Impregnated Pellets and Cement Bead Therapy.....</i>	<b>439</b>
<i>Antibiotics and Tetanus Immunization.....</i>	<b>439</b>
Prophylaxis .....	440
<b>Fracture Management .....</b>	<b>441</b>
<i>Introduction .....</i>	<b>441</b>
<i>Initial Fracture Wound Management .....</i>	<b>443</b>
<i>Initial Fracture Stabilization.....</i>	<b>443</b>
<i>Open Fracture Management .....</i>	<b>444</b>
<i>External Fixation of Extremity Fractures.....</i>	<b>445</b>
Upper Extremity Fracture Fixation .....	447
Lower Extremity Fracture Fixation.....	448
Femur Fracture Fixation .....	449
Pelvic Fracture Fixation.....	450
<i>Open Pelvic Trauma.....</i>	<i>452</i>
Associated Injuries .....	453
<i>Genitourinary Complications .....</i>	<i>453</i>
<i>Hip Dislocations.....</i>	<i>453</i>
<i>Acetabular Fractures.....</i>	<i>454</i>
<b>Summary.....</b>	<b>455</b>
<b>References .....</b>	<b>456</b>
<b>Appendices .....</b>	<b>469</b>

## Introduction

Combat casualty care (CCC) poses unique challenges. “Special experience is required to handle war injuries” and a good trauma surgeon is not necessarily a good war surgeon.<sup>1</sup> The goal of this chapter is to translate lessons learned during Operation Enduring Freedom (OEF) and Operation Iraqi Freedom (OIF) into a useful guide for managing combat casualties with extremity injuries.

- A majority (54 percent to 82 percent) of casualties at far-forward hospitals have extremity injuries.<sup>2,3</sup>
- The severity of limb injury encountered during CCC is far greater than that encountered in civilian care (Fig. 1).
- General surgeons often need to perform orthopaedic procedures such as complex wound debridement, external fixation of fractures, and fasciotomy for compartment syndrome.
- Extremity injury care underscores one of the most obvious differences between military and civilian scope of practice for nonorthopaedic CCC providers.

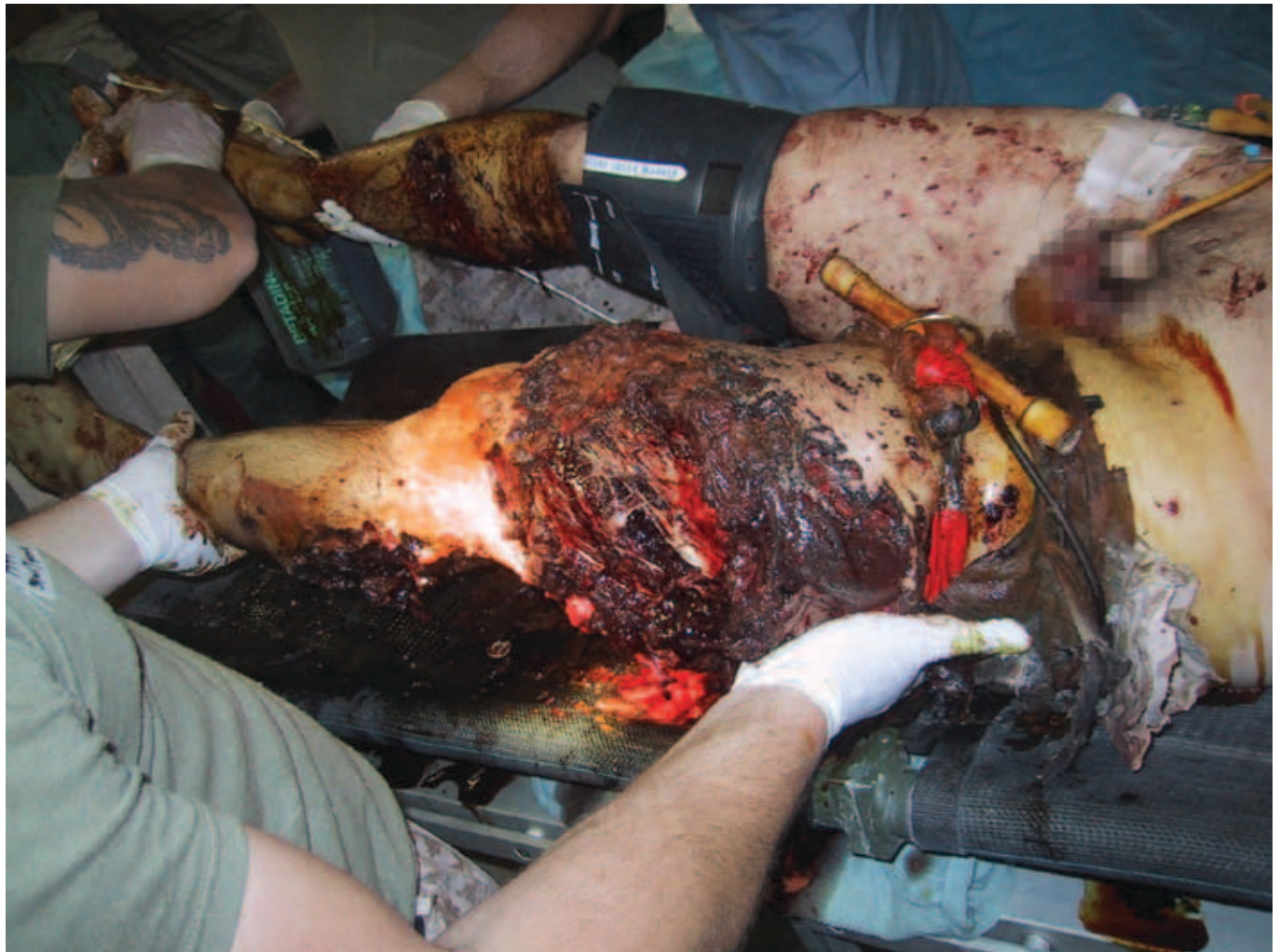

Figure 1. *The severity of limb injury encountered during CCC is far greater than that encountered in civilian care. Image courtesy of Harold Bohman, MD, CAPT, MC, US Navy.*

## Burden of Extremity Injury

Extremity injuries in battle casualties are common, disabling, and costly.<sup>2,4,5</sup> Much of war surgery is orthopaedic related. Extremity injuries were noted in 54 percent of casualties from OEF and OIF.<sup>2</sup> Furthermore, the casualties with extremity injuries consume the most care at the first hospital as evidenced by operating room time used, proportion of surgeries performed, and number of occupied beds.<sup>3</sup> Data collected from 2003 to 2006 in OIF indicate that extremity injuries have increased in severity (Fig. 2).<sup>6</sup> Despite the increase in injury severity, more casualties with more severe limb injuries are surviving and undergoing rehabilitation in large part due to improved CCC.

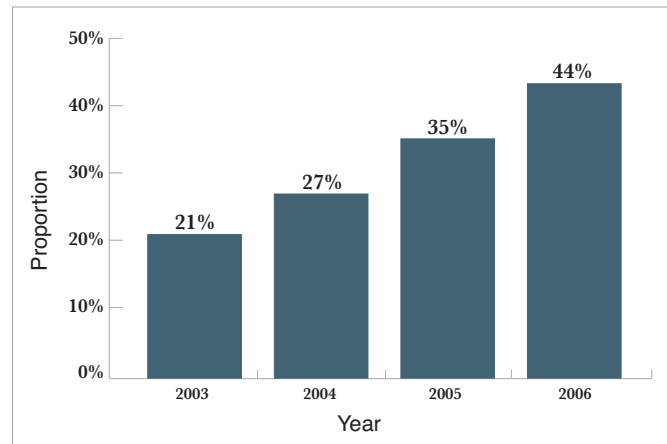


Figure 2. Annual proportion of US casualties with severe limb injuries during OEF and OIF.

Extremity injuries were noted in 54 percent of casualties from OEF and OIF.

Extremities are particularly vulnerable to combat-specific injury mechanisms like parachuting and fast-rope injuries, which are similar to falls from height.<sup>7,8,9,10</sup> The proportion of casualties with major limb trauma has doubled during the course of the OIF (from 21 percent to 44 percent).<sup>11</sup> In OEF and OIF, battlefield casualties with limb injuries consume about 65 percent of inpatient care, cause the greatest number of disabled soldiers, and result in the greatest projected disability costs.<sup>5</sup>

Extremity injury is of great importance as casualties can be saved with proper care and, conversely, endangered with inappropriate care (Fig. 3). The scope of practice for most careproviders expands when one goes to war. In the words of Sir Robert Jones who was knighted for his CCC in World War I, “the War has taught the orthopaedic surgeon that he has to be more of a general surgeon; it has taught the general surgeon that he should be more of an orthopaedist.”<sup>12</sup>

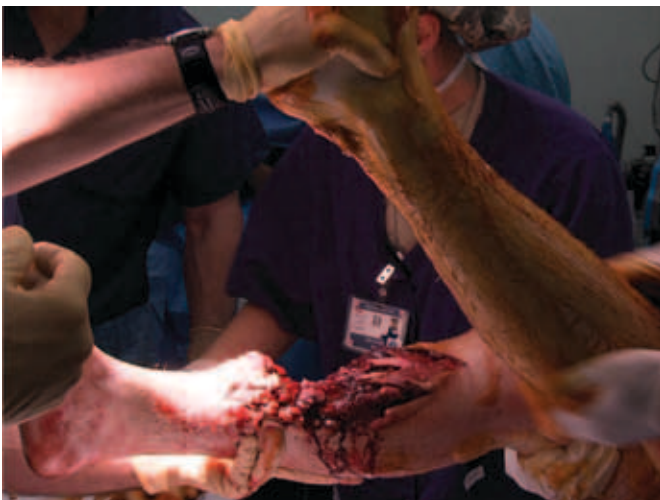
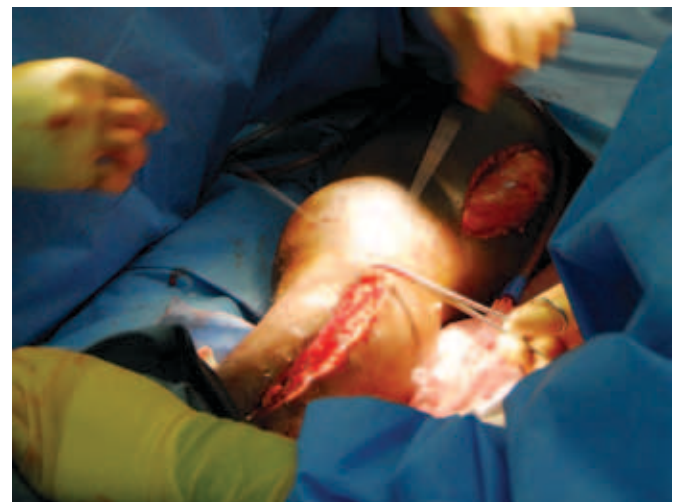
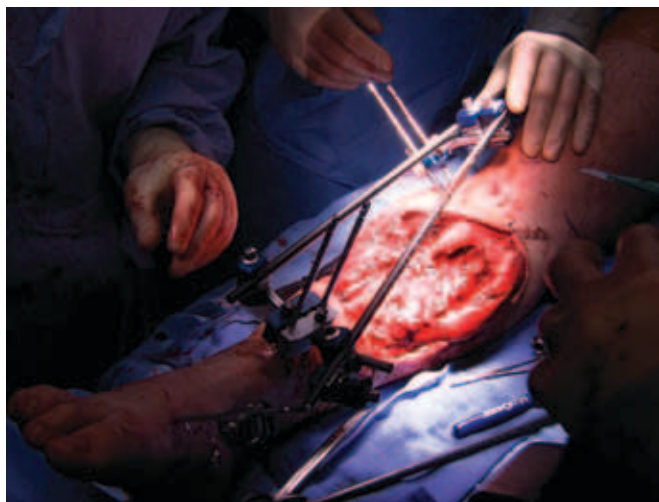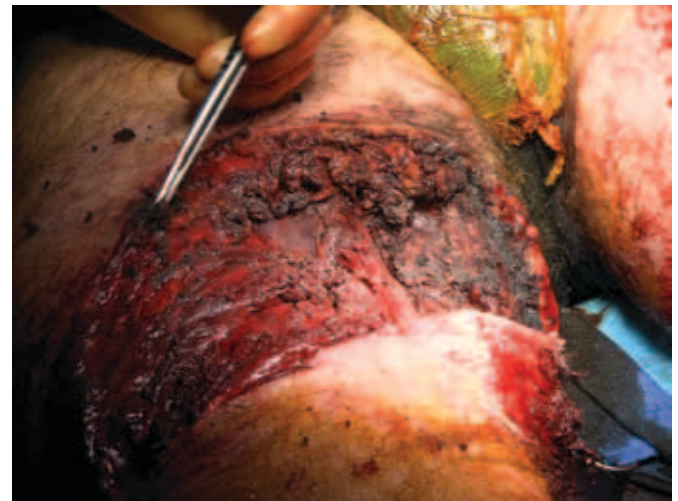Figure 3. Nonorthopaedists are often responsible for providing limb-saving interventions and care.

Extremity injury care is a prime example of this expanded scope of practice, as nonorthopaedists are often responsible for providing limb-saving interventions and care. Orthopaedic workload at times necessitates nonorthopaedic trained surgeons to perform extremity procedures such as: (1) complex wound debridement; (2) external fixation of fractures; and (3) fasciotomy for compartment syndrome (Fig. 4). These procedures are technically challenging, and if performed late or not at all, they are associated with increased mortality and morbidity rates.<sup>13,14</sup> Other critical interventions include applying extremity tourniquets and managing traumatic amputations.



Figure 4. General surgeons often need to perform orthopaedic procedures such as: (Top Right) complex wound debridement, (Bottom Left) external fixation of fractures, and (Bottom Right) fasciotomy for compartment syndrome. Fasciotomy image courtesy of Defense Imagery Management Operations Center (DIMOC).



General surgeons often need to perform orthopaedic procedures such as complex wound debridement, external fixation of fractures, and fasciotomy for compartment syndrome.

2						
3	2949	1358	GSW BACK	X	X	X
4						
5	2945	1358	GSW CHEST	X	X	X
6			GSW ARM	X	X	X
7		1358	SYNCOPE			
8	2946	1358	GSW: BRANK	X		
9	2944	1358	BLE INJ.	X	X	X ORTHO
10	2947		BLE INJ.	X	X	ORTH
08	2942	1358	BURNS R ARM		X	

Figure 5. White board demonstrating numerous combat casualties with multiple injuries. Image courtesy of the Borden Institute, Office of The Surgeon General, Washington, DC.

Combat casualties with multiple injuries can rapidly overwhelm orthopaedic service capacity (Fig. 5). Orthopaedists should anticipate this challenge and be prepared to help manage trauma system resources according to a preexisting protocol. Delegating cases, training colleagues, extending care through ancillary careproviders, and delegating nonorthopaedic tasks (e.g., casualty triage) to others will maximize available orthopaedic resources. In the setting of multiple casualties, the scope of practice for orthopaedists widens to include burn care, escharotomies, assisting in damage control surgery and resuscitation, and soft-tissue repairs, flaps, and reconstructions.

## Extremity Injury-Associated Mortality

A common preventable cause of battlefield death is limb hemorrhage.

- Casualty fatality rates have remained at an all-time low, while injury severity has increased because of lifesaving care such as emergency tourniquet use and improved patient resuscitation.
- A persistent, difficult to manage cause of death is limb hemorrhage too proximal for tourniquet or direct pressure control.
- United States (US) military hospital casualty death rates (casualties who died of wounds received in action, after arrival at a hospital) are 5 percent despite high injury severity.
- The orthopaedist is considered the subject matter expert on musculoskeletal injuries, tourniquet use, and proximal limb hemorrhage.

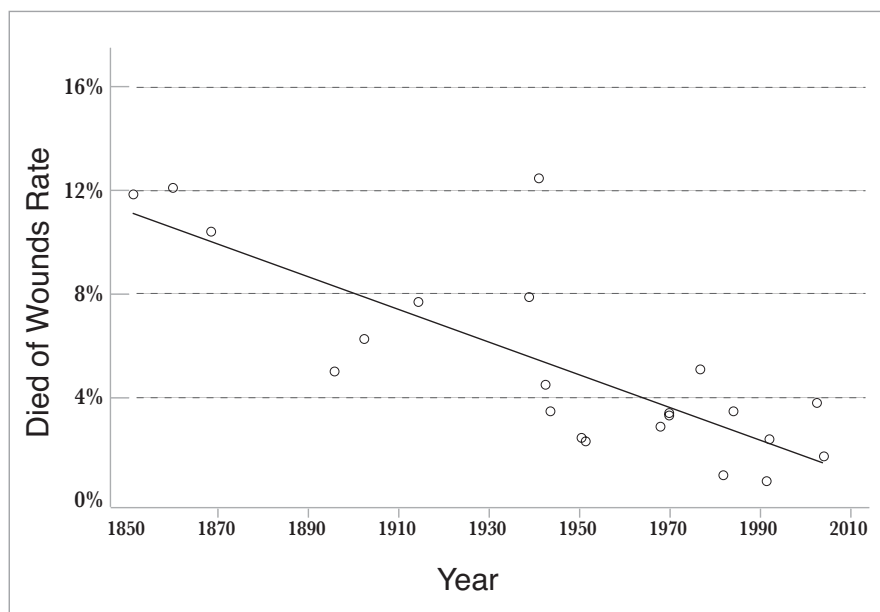


Figure 6. Rates over time of casualties who died of wounds.

Battlefield survival is at an all-time high for US casualties during OEF and OIF. Casualty fatality rates have remained at an all-time low while the injury severity has increased because of lifesaving care such as improved body armor, emergency tourniquet use, and improved patient resuscitation.<sup>15,16,17,18</sup> Orthopaedic trauma was the main cause of death in about 7 percent of casualties who were killed in action before arrival at a hospital in recent wars (e.g., Somalia, Vietnam), and the most common mechanism of death in this cohort was exsanguination.<sup>19,20,21,22</sup> Those casualties who died of wounds received in action after arrival at a hospital died of a myriad of traumatic sequelae. These included exsanguination, shock, and sepsis.<sup>20</sup> The rate of those who died of wounds, usually above 10 percent prior to 1900, has decreased with treatment advancements. As of 2009, the rate of those who died of wounds is about 5 percent (Fig. 6).<sup>23,24,25,26</sup>

Varying definitions of combat casualties who died of wounds make historical comparisons between individual wars difficult. Casualty statistics come predominantly from the war victors of modern nations, so there is a reporting bias. Although died of wounds is a phrase with a commonly accepted innate



meaning, its operational definition is very specific and less appreciated. Died of wounds received in hostile action is a specific casualty category; it excludes victims of a terrorist activity and includes those who die of wounds or other injuries received in action after having reached a medical treatment facility. The died of wounds rate generally goes up when prehospital care is optimized, as the casualties arriving alive at the first hospital generally are more severely injured than if prehospital care is suboptimal. If prehospital care is suboptimal, the killed in action rate generally goes up, and the died of wounds rate goes down.<sup>27</sup>

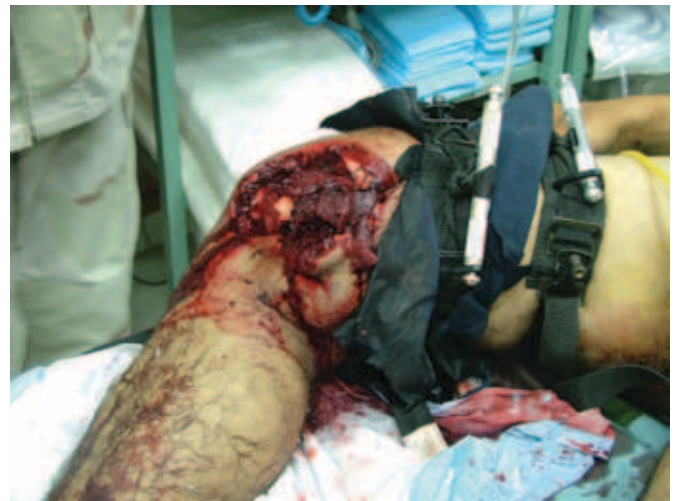

Figure 7. Battlefield tourniquets applied for limb hemorrhage control are a lifesaving intervention. If one tourniquet is ineffective, side-by-side (in sequence longitudinally) dual tourniquet use may be effective. Image courtesy of the Borden Institute, Office of The Surgeon General, Washington, DC.

Battlefield tourniquet use has been shown to be a lifesaving intervention when tourniquets are applied for limb exsanguination (Fig. 7).<sup>15,28</sup> The proportion of casualties dying from isolated limb exsanguination has dropped from 7 percent to 2 percent during the course of OEF and OIF. This decrease in mortality is likely due to improved resuscitation, better battlefield bandages, and more frequent use of tourniquets in the prehospital setting.<sup>6,15,17</sup>

The incidence of combat casualties suffering extremity wounds that arrive alive at CCC facilities has not changed much over time. Improved survival to hospital discharge is likely the result of resuscitation improvements, more rapid evacuation, body armor, and early forward surgery.<sup>29,30</sup> The proportion of survivors with extremity wounds increases when body armor is used compared to when it is not used. The greater lethality of head and torso war wounds results in casualties killed in action, disproportionate to casualties with isolated limb injury. The proportion of casualties arriving alive at the hospital with extremity injuries is 54 percent in OEF and OIF.<sup>2</sup> This is similar to the average projected body surface area for the extremities (61 percent) vulnerable to penetrating trauma in adult males proposed by Burns and Zuckerman.<sup>4,30</sup> Prolonged evacuation times due to tactical situations or other reasons generally increase the rates of those killed in action and generally decrease the rates of those who died of wounds in a delayed fashion. Shorter evacuation times usually reverse the aforementioned trends.<sup>25,29</sup> Recent medical advancements and body armor may have saved preferentially more torso-wounded casualties.<sup>29</sup>

The proportion of casualties dying from isolated limb exsanguination has dropped from 7 percent to 2 percent during the course of OEF and OIF. This decrease in mortality is likely due to improved resuscitation, better battlefield bandages, and more frequent use of tourniquets in the prehospital setting.

Case fatality rates for limb trauma patients admitted to hospitals have changed dramatically in the last century.<sup>31</sup> For example, case fatality rates for femur fractures have dropped from 80 percent in early World War I to less than 1 percent recently because of such advancements as the use of the Thomas splint before arrival at a hospital, intramedullary nailing, and early mobilization rather than bed rest and traction.<sup>25,32</sup> Gas gangrene, tetanus infections, and wound sepsis, common in World War I, are uncommon in OEF and OIF because of improved surgical debridement, wound irrigation, tetanus immunization, and antibiotic advancements.<sup>6,25</sup>

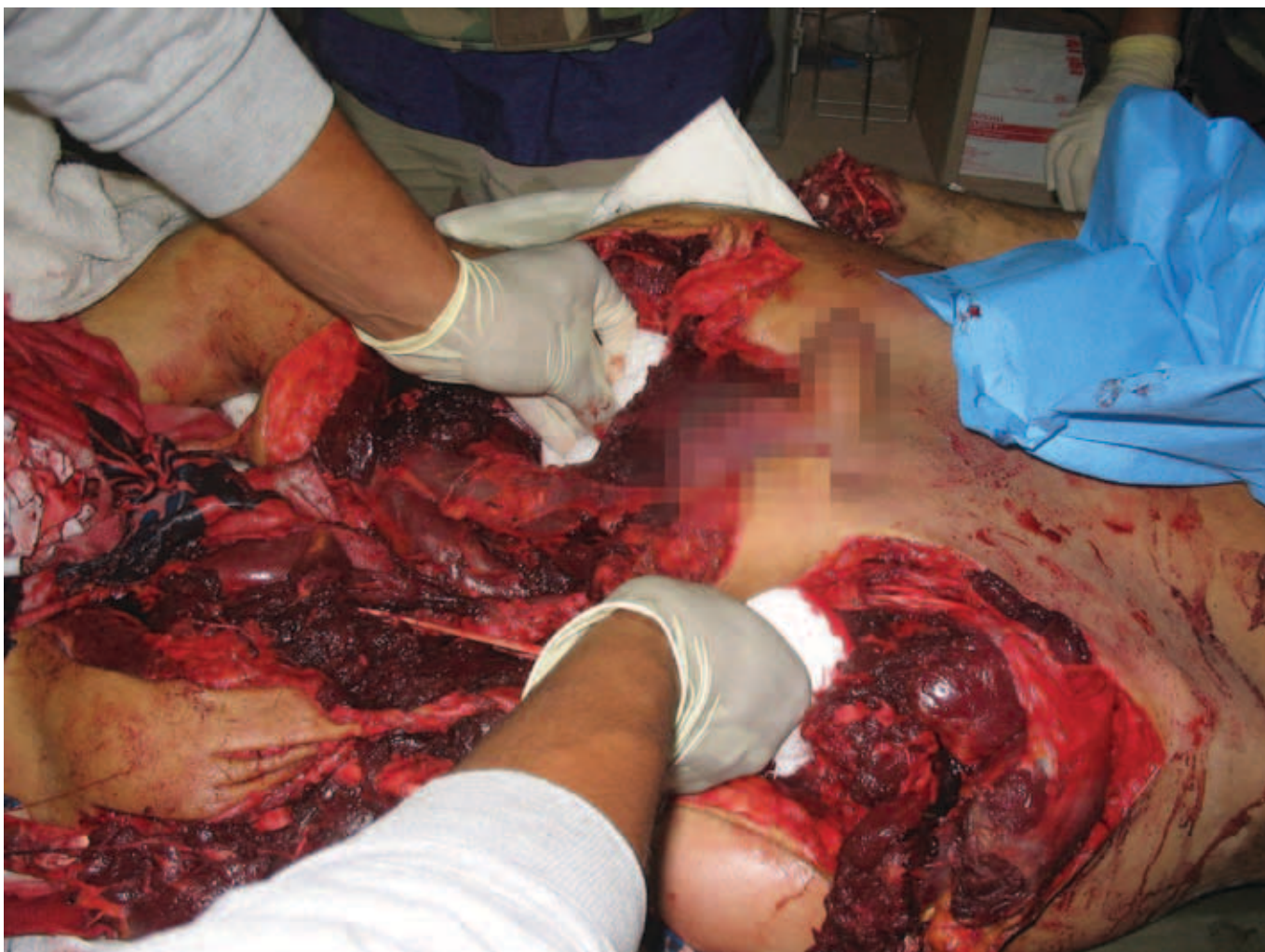

Figure 8. *Combat casualty mortality is predominantly related to vascular trauma and hemorrhage. Note pressure being applied to bilateral transected femoral arteries in this casualty. Image courtesy of the Borden Institute, Office of The Surgeon General, Washington, DC.*

Combat casualty mortality is predominantly related to vascular trauma and hemorrhage for those killed in action and those who died of wounds.<sup>6,25</sup> Observational data indicate that the type of tissue injured (e.g., artery, vein, or muscle), location (proximal versus distal) of the wound, and the mass of tissue wounded are associated with trauma outcomes such as death and survival.<sup>25,33</sup> For example, pelvic vessel disruption has had intermediate lethality between femoral and thoracoabdominal vessel disruption.<sup>25</sup> Proximal traumatic amputations are more lethal than distal amputations, and traumatic amputations of the lower limbs are more lethal than those of the upper limbs.<sup>25</sup> Multiple traumatic amputations are more lethal than single amputations.<sup>20</sup> These findings all converge on the idea that for combat casualties, the larger vessels bleed more, and greater tissue loss is associated with greater blood loss and higher mortality (Fig. 8).

Observational data indicate that the type of tissue injured (e.g., artery, vein, or muscle), location of the wound (proximal versus distal), and the mass of tissue wounded are associated with trauma outcomes such as death and survival.

Hemorrhage control (in general) and tourniquet use (in particular) have been associated with improved combat casualty survival.<sup>15,34,35</sup> Emboli and intravascular clots, including deep venous thrombosis,

pulmonary embolism, air embolus, and missile emboli, are uncommon but potentially preventable causes of extremity injury-associated death.<sup>20</sup> Multiple organ failure and sepsis are additional causes of death that are potentially preventable.<sup>6,20,25</sup>

Since the majority of the combat casualties suffer extremity trauma, orthopaedists are a cornerstone of CCC. Orthopaedists should prepare to train, educate, and extend the scope of practice of other CCC providers and ancillary staff regarding orthopaedic trauma. The orthopaedist is considered the subject matter expert on musculoskeletal injuries, tourniquet use, and proximal limb hemorrhage control.

## Emergency Tourniquet Application

Tourniquet use is probably the single most obvious difference in practice between combat and civilian casualty care.<sup>35</sup>

- The objective of emergency tourniquet use is to extinguish the distal pulse, thereby controlling bleeding distal to the site of tourniquet application.
- Tourniquets provide maximal benefit the earlier they are applied following difficult to control extremity hemorrhage.
- Improvised (windlass) tourniquets should be applied only when scientifically designed tourniquets are absent. A windlass is a lever that can be wound to tighten a tourniquet.
- Tourniquets work better when applied distally (forearms and calves) than when applied more proximally (upper arms or thighs).
- Remove clothing and other underlying materials prior to tourniquet application (when possible) to ensure a tight and secure tourniquet fit.
- Remove the clothing surrounding a tourniquet to enable identification of all surrounding wounds and injuries.
- Do not apply tourniquets directly over joints as compression of vascular structures and bleeding control is limited by overlying bone.
- If one tourniquet is ineffective, side-by-side (in sequence longitudinally) dual tourniquet use may be effective.

The current indication for emergency tourniquet use in combat is any compressible limb wound that the first responder assesses as possibly lethal.<sup>36</sup> Tourniquet use for this indication has demonstrated favorable results following optimization of tourniquet design, training, doctrine, casualty evacuation, and tourniquet research.<sup>15,28</sup> The goals of emergency tourniquet use are to control bleeding and to extinguish the distal pulse. Timing and speed of application are vital because tourniquet placement before shock onset saves about 20-fold more casualties than placement after shock onset (96 percent survival with use before onset of shock versus 4 percent survival after onset of shock). Early prehospital tourniquet application saves about 11 percent more lives than delayed in-hospital use.<sup>15</sup> Tourniquet use in combat is recommended before casualty extraction or transport.<sup>36</sup>

Tourniquets provide maximal benefit the earlier they are applied for difficult to control extremity hemorrhage. Tourniquet placement before the onset of shock is associated with 96 percent survival versus 4 percent survival after the onset of shock.



How tourniquets are applied has direct patient survival implications. Loose, misplaced, unattended, and broken devices have been associated with loss of hemorrhage control and death.<sup>15,35</sup> Materials under a tourniquet should be removed at the first opportunity to ensure optimal tourniquet constriction.<sup>36</sup> Periodic reassessment of tourniquets and casualties is vital. For example, a thigh tourniquet can loosen during patient transport or manipulation and thus permit rebleeding, especially when there is clothing or gear between the tourniquet and the skin.<sup>36</sup> A previously tight thigh tourniquet can loosen after exsanguination from non-extremity bleeding (e.g., chest, abdomen, or pelvis injuries). A significant loss of total body blood volume (e.g., 3.75 liters) will diminish the thigh circumference (volume) under and proximal to the tourniquet and will cause tourniquet loosening. Hence serial evaluations and tourniquet retightening are vital, when indicated.<sup>36</sup> However, reassessment should not include loosening and reapplication until surgeons are prepared to directly address the source of hemorrhage.

The objective of emergency tourniquet use is to extinguish the distal pulse, thereby controlling bleeding, distal to the site of tourniquet application.

Clothing about a tourniquet should be removed at the first opportunity (when the tactical situation permits) to allow detection of all wounds. Undetected wounds are associated with uncontrolled hemorrhage and death.<sup>36</sup> Surveys are cursory when the applier and the casualty are under gunfire. Hastily performed casualty examinations often miss injuries; hence, casualties should be routinely reexamined at each level of care. Scientifically designed, laboratory tested, and clinically validated tourniquets should be used whenever possible.<sup>36,37</sup> The Combat Application Tourniquet (C-A-T®) is the most effective prehospital tourniquet (of tourniquets that have undergone clinical trials), and the Emergency & Military Tourniquet (EMT) is the most effective emergency department tourniquet.<sup>36</sup> Tourniquet effectiveness was defined by stopping visible bleeding and elimination of a palpable pulse (Fig. 9). Improvised windlass tourniquets should only be used when well-designed and clinically validated tourniquets are unavailable. A windlass is a lever that can be wound to tighten a tourniquet.



Figure 9. The indication for emergency tourniquet use in combat is any compressible limb wound that the first responder assesses as potentially lethal. (Left) The Combat Application Tourniquet® is effective in a prehospital setting. (Right) The Emergency & Military Tourniquet is effective in an emergency department setting. Images courtesy of North American Rescue, LLC and Delfi Medical Innovations, Inc.

Improvised (windlass) tourniquets should be applied only when scientifically designed tourniquets are unavailable.

Tourniquet use over the distal segment of Hunter's canal near the knee should be avoided because prominent bones and tendons risk ineffectiveness. Tourniquets work well, provided they are applied proximal to wounds. They work better on the forearm or calf area and need not be reserved for the thigh or upper arm as is sometimes recommended for control of distal limb hemorrhage.<sup>36</sup> A common misconception is that a tourniquet has a lower effectiveness on two-boned segments (forearm and lower leg) than on one-boned segments (upper arm and thigh). A tourniquet actually has higher, rather than lower, effectiveness on two-boned limb segments.<sup>36</sup> The main determinant of effectiveness in well-designed tourniquets is the ratio of device width-to-limb circumference.<sup>36,38</sup> If one tourniquet is ineffective, then side-by-side (in sequence longitudinally) use can extinguish the distal pulse and stop bleeding, as such use widens the compressed area.

If one tourniquet is ineffective, side-by-side (in sequence longitudinally) dual tourniquet use may be effective.

Misconceptions regarding tourniquets are rampant and take time and effort to correct.<sup>36,38,39,40</sup> Tourniquet education, training, and doctrine are vital and should be refined based on clinical evidence. Orthopaedists are looked to for tourniquet advice because they commonly use tourniquets during their day-to-day surgical practice. Orthopaedists are often asked to educate CCC providers on how and when tourniquets should be applied and how to detect and manage tourniquet-related problems. Orthopaedists may even be asked to build and steward tourniquet programs (i.e., find, order, store, test, clean, and fix devices, educate users, and document adverse events).<sup>15,36</sup>

Combat Application Tourniquet (C-A-T®): Application Steps (see Appendix 1)

- (1) Route band around injured limb
- (2) Pass band through the outside slit
- (3) Pull band tight
- (4) Twist windlass rod until bleeding has stopped and distal pulse is extinguished
- (5) Lock the rod with the clip
- (6) Secure the rod with the strap
- (7) Record time tourniquet was applied

## Limb Compartment Syndrome

- Compartment syndrome continues to cause significant morbidity in OEF and OIF.
- Over-resuscitation with crystalloids can cause compartment syndrome.
- Compartment syndrome is a clinical diagnosis.
- Pressure manometry-based diagnosis of compartment syndrome in combat settings is unreliable.
- Lethal mistakes include delayed or limited fasciotomy skin incisions.
- Fasciotomy is not indicated in patients with prolonged compartment syndromes (warm ischemia duration exceeding 12 hours).



## Introduction

Compartment syndrome is a significant cause of combat-related morbidity in OEF and OIF and is highly varied in its presentation.<sup>11</sup> For US military casualties with limb injury in OEF and OIF, the incidence of compartment syndromes at or before arrival at Landstuhl Regional Medical Center, Germany, is 15 percent (Kragh, in press).<sup>11</sup> Combat casualty careproviders must often manage multiple cases of compartment syndrome prior to mastering the subtleties of diagnosis, treatment, and developing the ability to identify injured limbs at risk for developing the condition.<sup>13</sup>

Compartment syndrome continues to cause significant morbidity in OEF and OIF, with an incidence of 15 percent at or before arrival at Landstuhl Regional Medical Center, Germany.

## Definition, Mechanisms, and Risk

Compartment syndrome is defined as an increased interstitial pressure within an enclosed osteofascial space (compartment) that reduces capillary blood perfusion below a level necessary for tissue viability.<sup>41</sup> As with all ischemia-reperfusion syndromes, duration of ischemia affects severity. Two basic mechanisms that cause compartment syndrome are an increase in the volume of tissue within an enclosed space and a decrease in the size of the enclosed space.

The compartment syndrome is common with injuries such as fractures that have severe swelling or bleeding.<sup>41</sup> Interestingly, open fractures have a higher rate of compartment syndrome than closed fractures despite the fascial rents seen with open fractures (Fig. 10). This is likely due to the higher injury force seen with open fractures resulting in greater tissue trauma, swelling, and bleeding.<sup>41</sup> The occurrence of compartment syndrome in a fractured limb has recently been associated with slower subsequent fracture healing rates.<sup>42</sup> The interstitial pressure of limbs also plays an important role in the mobilization of interstitial fluids into the intravascular space in response to distant hemorrhage and the tamponade of local intracompartmental hemorrhage.

The list of causes or risk factors for compartment syndrome is long and diverse (Appendix 2).<sup>41</sup> In combat casualties, more than one contributing factor is often present. Current data indicate that the most obvious determinant of fasciotomy frequency in OEF and OIF is the injury severity of the limb wound, based on the Abbreviated Injury Scale (AIS) of the most severe extremity wound.<sup>11</sup> Limb interstitial tissue pressures increase with resuscitation.<sup>41</sup> Hence, care must be taken to avoid excessive administration of crystalloid fluids that can worsen compartment syndrome. The overall injury severity score (ISS), frequency of tourniquet use, shock, and hypoperfusion also confer compartment syndrome risk.<sup>11</sup>

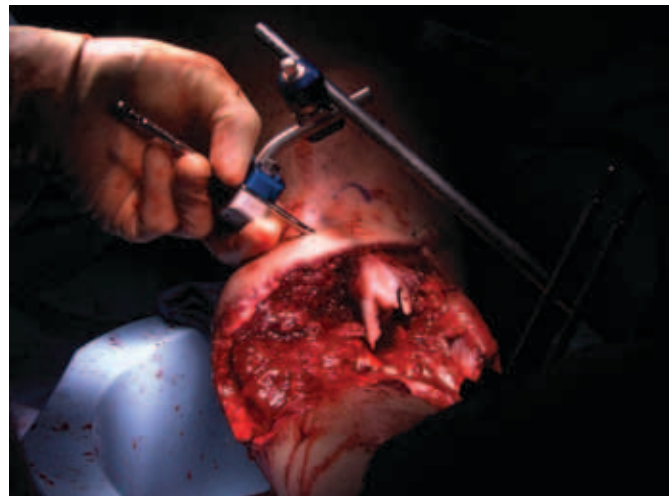


Figure 10. Open fractures have a higher rate of compartment syndrome than closed fractures despite the fascial rents seen with open fractures.

Over-resuscitation with crystalloids can cause compartment syndrome.

## ***Clinical Findings***

The classic findings seen with acute limb ischemia (i.e., pain, pallor, paresthesias, pulselessness, and poikilothermia) are not clinically reliable for the diagnosis of compartment syndrome and often manifest only in the late stages of compartment syndrome.<sup>41</sup> The finding of distal limb pulselessness is due to compression of arteries within the compartment. Civilian literature reports that pulselessness is a late clinical finding in compartment syndrome.<sup>41</sup> The authors' experiences in OIF revealed similar findings. Pulselessness is rarely seen, and it is usually a late finding when it is documented. In an alert and cooperative patient, compartment syndrome is manifest by pain out of proportion to the physical injury observed. The pain is typically worse with passive stretch of the muscles within the ischemic compartment. This pain on passive stretch is a sensitive indicator of compartment syndrome as it occurs early in its course; however, it is not specific.<sup>43,44</sup> While a palpably tense compartment is a specific clinical finding, it is not highly sensitive.<sup>45</sup> Sensory symptoms such as paresthesias are often an early indicator of nerve ischemia.<sup>46</sup>

Compartment syndrome is a clinical diagnosis. Clinicians must weigh the mechanism of injury and suggestive clinical findings, including pain with passive stretch, palpable tenseness of the affected compartment, and neurovascular examination to arrive at the diagnosis.

The time of onset of compartment syndrome is often hours following injury, but it can occasionally present within minutes of injury.<sup>47</sup> The authors have seen florid compartment syndrome cases in OIF that presented within 15 to 45 minutes of injury with pulselessness that was rapidly reversed following fasciotomy.<sup>47</sup> Clinical findings in casualties with compartment syndromes can be classified as early and late. Early findings such as a palpably tense compartment, pain out of proportion to the injury, and pain with passive stretch of involved muscles are due to the elevated hydrostatic pressure within the fascial compartment.<sup>41</sup> Late findings of paresthesias and paralysis are due to the duration of tissue ischemia, particularly of nerves and muscle, respectively. Permanent nerve palsy is uncommon with compartment syndrome. The etiology of extremity weakness may be difficult to differentiate clinically from myopathy of ischemia-reperfusion, which is common and associated with the duration of ischemia.<sup>41</sup> The pressure gradient applied to the nerve (such as with a tourniquet) deforms the nerve at the point of maximal gradient (e.g., at the tourniquet edge) and is the cause of the nerve palsy. Nerve palsy clinically resolves slower than nerve ischemia but usually completely resolves.<sup>36</sup> Nerve ischemia is zonal, not focal, and is rarely severe in the emergency setting. It is associated with prolonged ischemia time.<sup>36</sup> Muscle is the tissue most sensitive to the duration of ischemia, the nerve is less so.

The rate of limb swelling is greatest early after injury, as tissue compartments are more pliable. Limbs typically reach maximum swelling 36 to 48 hours following injury.<sup>48</sup> Resolution of limb swelling occurs over a similar duration.<sup>49</sup> Comorbidities such as hemorrhagic shock and treatments (e.g., tourniquets and resuscitation) may alter swelling timelines, such that maximal swelling occurs up to five days following injury. This can result in discordant total body fluid intake and output measurements.<sup>49</sup> This means that compartment syndrome can be absent early at a forward treatment facility, yet occur from one to four days later during evacuation to rearward hospitals.<sup>13</sup> Furthermore, even if a fasciotomy is performed at a forward hospital, continued swelling can cause recurrent compartment syndrome if the release was not complete. This occurrence is associated with increased amputation and mortality rates.<sup>13</sup> The degree of swelling is also associated with the degree of injury and the degree of over-resuscitation, particularly with fluids more dilute than plasma.<sup>13,49</sup>

Recurrent compartment syndrome can be seen with incomplete release of compartments and is associated with increased amputation and mortality rates.

Prevention and identification of compartment syndrome are difficult. Historically, under-resuscitation was associated with acute renal failure. Subsequently, over-resuscitation with excessive fluids was linked to excessive limb edema and compartment syndromes, even in uninjured limbs.<sup>50,51</sup> Over-resuscitation leading to limb compartment syndrome is analogous to over-resuscitation leading to abdominal compartment syndrome.<sup>50,52</sup> Modern resuscitation has evolved towards physiologically-based targets (e.g., controlled hypotension with adequate perfusion), rather than simply replacing the estimated volume of blood loss with crystalloid fluids. Over-resuscitation has become less common recently.<sup>16,53</sup>

## Diagnosis

The diagnosis of compartment syndrome in war is based on clinical findings. Clinicians must weigh the mechanism of injury (e.g., blast) and suggestive clinical findings, including pain with passive stretch, palpable tenseness of the affected compartment, and neurovascular examination to arrive at the diagnosis. Common laboratory tests suggestive (but not diagnostic) of late or missed compartment syndrome, include elevated serum levels of creatinine kinase and urine myoglobinuria.<sup>41</sup> Due to limited sensitivity and specificity of clinical and laboratory findings, the diagnosis of compartment syndrome in the civilian sector is highly dependent on measuring tissue compartment pressures.<sup>54</sup> It is common civilian practice to measure compartment pressure before and after fasciotomy to confirm both the diagnosis and the efficacy of fascial release.<sup>54</sup> The accuracy of manometric-based diagnosis of compartment syndrome is unreliable in combat settings, and its use is not recommended.<sup>47</sup> Limb tissues such as muscle compartments are not incompressible matter (such as water) and do not transmit pressures fully or immediately like incompressible fluids. Time and distance attenuate high pressures within limb tissues. Failure to measure tissue pressure in proximity (e.g., within five centimeters) to the zone of peak pressure may result in a serious underestimation of the maximum compartment pressure.<sup>55</sup>

Manometric-based diagnosis of compartment syndrome in combat settings is unreliable and not recommended.

Even the methods and pressure threshold used for diagnosis are controversial. Pressures are indirect indicators of ischemia, and the amplitude of the pressure does not account for the ischemic duration, individual tolerance of ischemia, variations of anatomic compartments, and location of measurement versus pathology, such as fracture site.<sup>54</sup> No consensus exists on whether the pressure threshold within the compartment should be 30 or 45 mm Hg (4 to 6 kilopascals) or whether the difference between the intracompartmental pressure from the blood pressure such as the diastolic blood pressure (delta pressure) should be 30 or 40 mm Hg (4 to 5.33 kilopascals).<sup>54</sup> There is

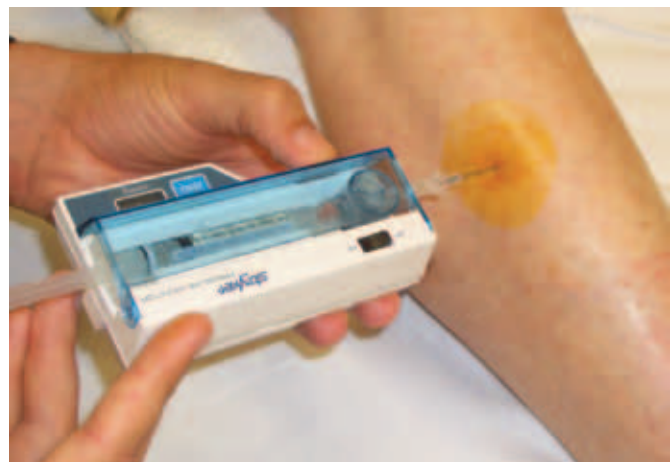

Figure 11. *Manometric-based diagnosis of compartment syndrome in combat settings is unreliable.*

even a lack of consensus regarding the type of catheters (slit, wick, and ultrafiltration) that should be used to measure compartmental pressures (Fig. 11).<sup>43</sup>

Observation and serial clinical examination of patients with limb trauma and equivocal compartment syndrome clinical findings are common in civilian settings. In such cases, recent interventions (e.g., aggressive fluid resuscitation) combined with mechanism of injury and evolving physical findings, such as a palpably tense compartment, can facilitate early diagnosis. In the mentally impaired (e.g., sedated, intubated, or unconscious) casualty, diagnosis of compartment syndrome is difficult because the clinical examination is less sensitive. Similarly, in combat settings, serial examinations may be impossible or unreliable because patients are often evacuated long distances under austere conditions. In such scenarios, prophylactic fasciotomies are recommended prior to transport based on clinical findings, extent of soft-tissue injury, anticipated resuscitation, and potential ischemia time.<sup>56</sup> Circular casts, which are common in civilian settings, are usually avoided in war, since evacuation over distances and time without close monitoring permit the onset of compartment syndrome without detection or treatment.<sup>13,57</sup>

Delayed attempts at therapeutic fasciotomies are suboptimal and are associated with increased morbidity and mortality. Certain clinical findings – wounds with extensive soft-tissue injury, anticipated lengthy resuscitation, and potential extended ischemia time – should prompt prophylactic fasciotomies prior to evacuation of patients.

Failure to detect compartment syndrome early risks rhabdomyolysis, renal failure, Volkmann's ischemic contracture (ischemic muscle necrosis), and permanent limb dysfunction.<sup>41</sup> Delayed attempts at therapeutic fasciotomies are suboptimal and are associated with increased morbidity and mortality.<sup>13</sup>

## ***Treatment***

The definitive treatment for acute compartment syndrome is therapeutic fasciotomy. When compartment syndrome is risked or is impending during the lag time from injury to syndrome onset, the fasciotomy is termed prophylactic.<sup>47</sup>

Evidence indicates a delayed fasciotomy is not indicated for casualties with a prolonged compartment syndrome (i.e., warm ischemia duration greater than 12 hours).<sup>14,58</sup> Fasciotomy in this subset of patients will increase infection rates and will decrease survival.<sup>47</sup> An algorithm for clinical decision making on compartment syndrome management in a combat setting is provided in Figure 1 within Appendix 2.

Fasciotomy is not indicated for casualties with a prolonged compartment syndrome (i.e., warm ischemia duration greater than 12 hours).

Temporizing measures such as removing circumferential dressings or casts, removing sutures from tightly bound closures, and placing the affected limb at the level of the heart to balance inflow and venous return do no harm but are inadequate to treat an established compartment syndrome. In a casualty, marked elevation or dependence of the injured limb relative to the heart can increase risk of compartment syndrome, especially if the casualty is at risk for or is in hemorrhagic shock.<sup>41</sup> Extremity elevation is contraindicated because it decreases arterial blood flow and the arteriovenous pressure gradient and thus worsens the ischemia.<sup>59</sup>



Marked elevation or depression of the injured limb relative to the heart can increase the risk of compartment syndrome.

The sequelae of neglected or delayed treatment of compartment syndrome are ischemic contractures, nerve injury (due to nerve ischemia), potential amputation, systemic effects of myonecrosis, and death.<sup>13,54</sup> The morbidity risk and sequelae of compartment syndrome and fasciotomy are outlined in detail in Table 1.

MORBIDITY RISK AND SEQUELAE OF COMPARTMENT SYNDROME AND FASCIOTOMY	
Potential Morbidity: Compartment Syndrome and Early Fasciotomy	Skin scar, scaly skin, ulceration, tethered tendons
	Postoperative arterial or graft thrombosis, thromboembolic disease wound infection, nonhealing fasciotomy wounds
	Limb swelling or chronic edema, shape change of limb, muscle hernia
	Pain, paresis or paralysis, paresthesia
	Coverage challenge: primary closure, delayed primary closure, skin graft, flap
	Possible repair of arterial injury worsening ischemia-reperfusion injury
Potential Sequelae List: Compartment Syndrome with Late or Incomplete Fasciotomy	Mortality, sepsis, multiple organ failure, acute kidney failure
	Myonecrosis, myoglobinemia, myoglobinuria, or rhabdomyolysis
	Paresis or paralysis
	Stiffness or contracture
	Limb amputation, tissue loss (e.g., muscle debridement)

Table 1. *Morbidity risk and sequelae of compartment syndrome and fasciotomy.*

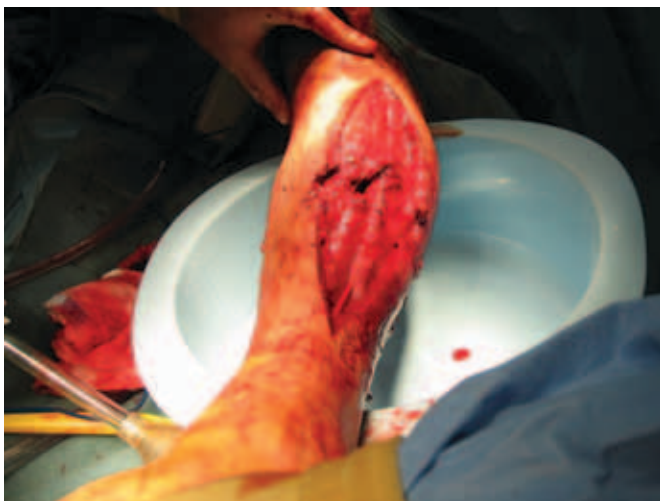


Figure 12. *The fasciotomy skin incision should be long, approximating the proximal to distal length of the compartment to be released. Image courtesy of the Borden Institute, Office of The Surgeon General, Washington, DC.*

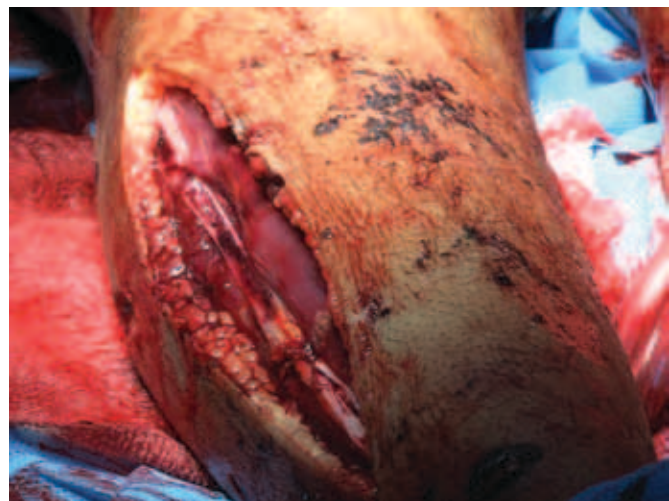

Figure 13. *Limited fasciotomy skin incisions, as seen above, should be avoided.*



## FASCIOTOMY SURGICAL STEPS (LEG AS AN EXAMPLE)

1. Initiate surgical positioning (supine); palpate bony landmarks and septum between anterior and lateral compartments.
2. Plan and mark incisions for dermatomies; do not use one-incision technique; use two-incision technique.
3. Make a medial skin incision: longitudinal posterior to tibia margin; avoid saphenous vein and nerve; from proximal tibia near the pes anserinus to the proximal ankle flexor retinaculum; do not use short skin incisions.
4. Make a lateral skin incision: near the septum between the anterior and the lateral compartments; avoid the superficial peroneal nerve from the proximal tibia margin near iliotibial band insertion on Gerdy's tubercle to the proximal ankle extensor retinaculum; do not use short skin incisions.
5. Expose the lateral leg fascia for a visual and palpable check of bony landmarks and septum between the anterior and the lateral compartments.
6. Divide the lateral fascia transversely at the septum to confirm entry into both the anterior and the lateral compartments. Extend this fasciotomy anterior and posterior enough for confirmation; use instrument or finger to confirm entry into both compartments.
7. Divide the lateral leg fascia longitudinally from the transverse fasciotomy; do this both proximally and distally for both the anterior and the lateral compartments.
8. Anterior compartment fasciotomy goes from the proximal tibia margin near the iliotibial band insertion on Gerdy's tubercle to the proximal ankle extensor retinaculum. Partially release one-quarter inch of the retinaculum; do not use short fascia incisions.
9. Superficial medial fasciotomy releases the posterior superficial compartment and goes from the proximal tibia margin near the pes to the proximal ankle flexor retinaculum. Partially release one-quarter inch of the retinaculum; do not use short fascia incisions.
10. Deep medial fasciotomy releases the deep posterior compartment and goes along the posterior medial tibia margin. Release the medial soleus margin from the tibia; check especially deep and proximal.
11. Check muscle bulge after fasciotomy; palpably confirm the adequacy of all releases.

Table 2. *Fasciotomy surgical steps using the leg as an example.*

## Fasciotomy Techniques

Extremity fasciotomy can be performed as an emergent bedside procedure but is preferably undertaken in the operative suite where anesthesia, sterile conditions, adequate lighting, and appropriate equipment are readily available (Table 2). Skin incisions (dermotomies) provide nearly no compartment release in and of themselves. The fasciotomy skin incision should be long because fasciotomy will need to span the length of the compartment itself.<sup>54</sup> The skin incision approximates the proximal to distal length of the compartment to be released (Figs. 12 and 13). Long skin incisions permit proper palpation and inspection of the compartment pressure and fascial release. Fasciotomies in civilian settings are often shorter because injury severities and compartment syndromes are less severe than in military settings and because reassessments are easier. A detailed outline of compartment names and corresponding main muscle groups and diagnostic and procedural codes used for CCC documentation are provided in Table 4 within Appendix 2. An operative note template for dictation, surgical planning, and data collection is provided in Table 5 within Appendix 2.

Limited fasciotomy skin incisions should be avoided. Skin incisions should be long, as a fasciotomy will need to span the length of the compartment itself.

### ***Lower Leg Fasciotomy***

For the lower extremities, the common compartments that need release are in the lower leg (calf) and thigh. The four compartments of the lower leg consist of the anterior, lateral, superficial posterior, and deep posterior compartments. These compartments are typically released with longitudinal medial and lateral incisions (two skin incisions) (Fig. 14). One skin incision versus two skin incisions risks incomplete

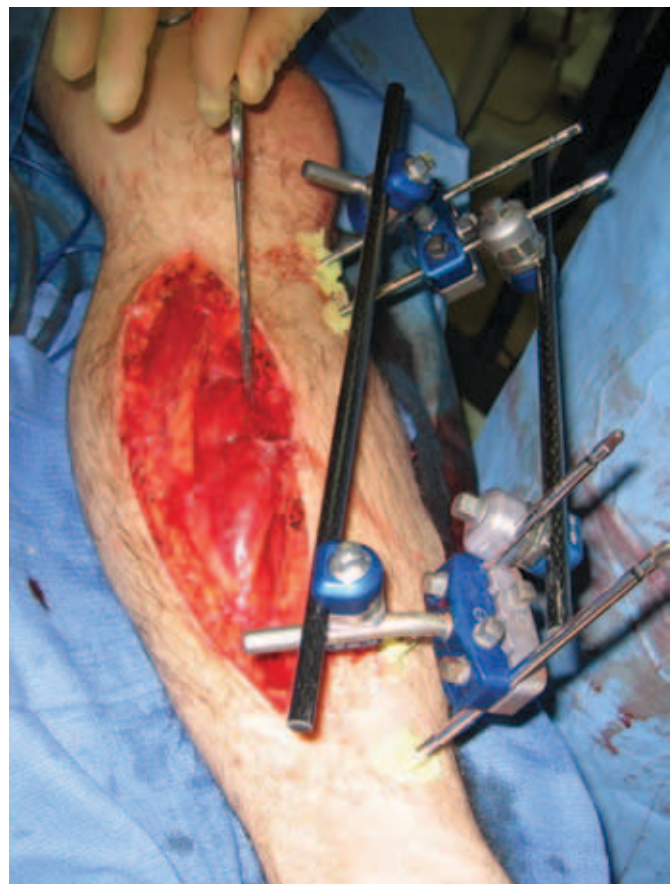
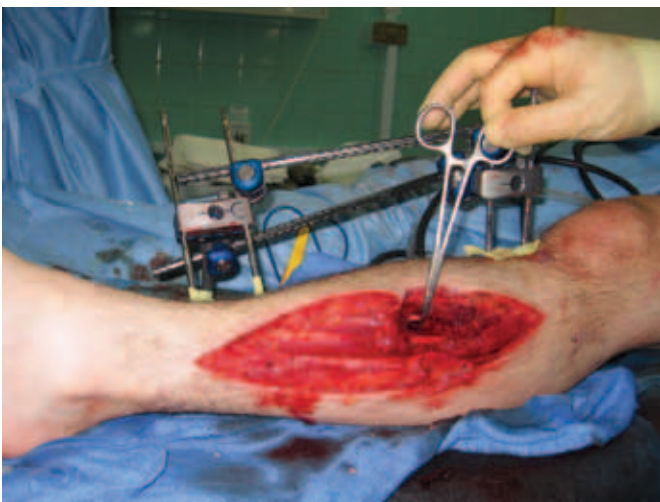

Figure 14. *The four compartments of the lower leg are typically released with longitudinal lateral and medial skin incisions as demonstrated in the adjacent images. Images courtesy of the Borden Institute, Office of The Surgeon General, Washington, DC.*

fascial release since it is associated with both an inadequate inspection and inadequate palpation of muscles and fascia; this includes an inadequate check of the completeness of the release. The lower leg compartments are the ones most commonly released late, and should be released earlier in such cases prior to swelling reaching its maximum at the index surgery.<sup>13</sup> The anterior leg compartment fasciotomy in war can include a partial (five millimeter) release of the proximal portion of extensor tendon retinaculum near the ankle. This should ensure that the distal extent of the fasciotomy is sufficiently complete.

A double-skin incision technique should be used to release the four compartments of the lower leg in combat casualties.

### ***Thigh Fasciotomy***

The thigh has three large compartments (anterior, posterior, and adductor), which are released with longitudinal medial and lateral incisions. The lateral thigh incision, used to access both the anterior and the posterior thigh compartments, can be extended to release the hip abductor muscles, tensor fascia lata, and gluteal muscles (Fig. 15).<sup>41</sup>

### ***Upper Arm Fasciotomy***

The upper arm contains three compartments: one anterior, one posterior, and one for the deltoid muscle. These compartments are typically approached with medial and lateral skin incisions, and the lateral incision may also be extended to include release of the deltoid compartment.<sup>41</sup>

### ***Forearm Fasciotomy***

In the forearm, the three compartments are dorsal, volar, and mobile wad muscles. The forearm fascial release is typically through one volar skin incision and one dorsal skin incision. The volar skin incision provides access to the mobile wad, superficial, and deep volar musculature and may be extended distally for the carpal tunnel release. The dorsal skin incision is used to release the contents of the dorsal forearm compartment. Individual forearm muscle epimysium, the layer of connective tissue that ensheaths an entire muscle, may be as robust as the superficial fascia of the forearm resulting in elevated pressures within individual muscle belly sheaths. Thus, each muscle belly, especially volar, should be inspected for possible release (epimysiotomy) in addition to release of the forearm fascia (Fig. 16).<sup>41</sup>

### ***Hand Compartment Fasciotomy***

Hand compartments can be released through five skin incisions: two dorsally-based incisions over the index and ring finger metacarpals; one radial incision over the thenar muscles; one ulnar incision over the hypothenar muscles; and the final skin incision for the carpal tunnel release (Fig. 17).<sup>41</sup> Carpal tunnel release is commonly performed too late. The carpal tunnel should be released at the index surgery before swelling has reached its maximum.<sup>13</sup>

## ***Conclusions***

Short skin incisions and incomplete fasciotomies risk mortality and morbidity.<sup>13</sup> Long skin incisions should be made to ensure adequate exposure of the deepest portion of the wound.<sup>60</sup> A single skin incision of the lower leg for a four-compartment fasciotomy may work well in civilian care, but it has not worked well in war. A double-skin incision technique should be used in combat casualties. Orthopaedists serve patients well if they make themselves widely available for consultation regarding combat casualties at risk for compartment syndrome.



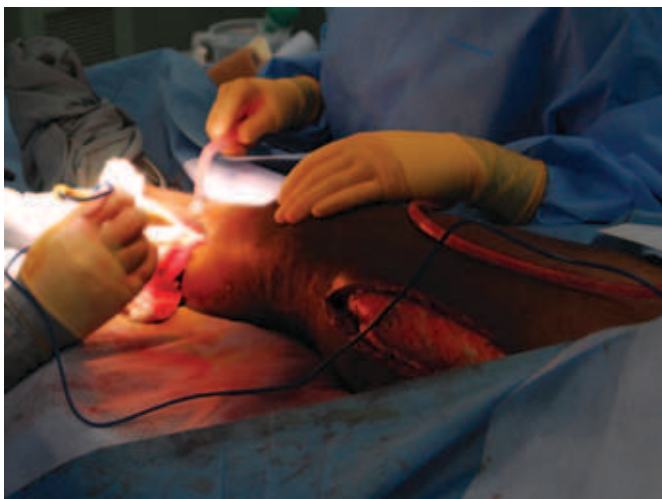

Figure 15. The lateral thigh incision can be used to access the anterior and posterior thigh compartments and can be extended to release the hip abductor muscles, tensor fascia lata, and gluteal muscles. Image courtesy of Defense Imagery Management Operations Center (DIMOC).

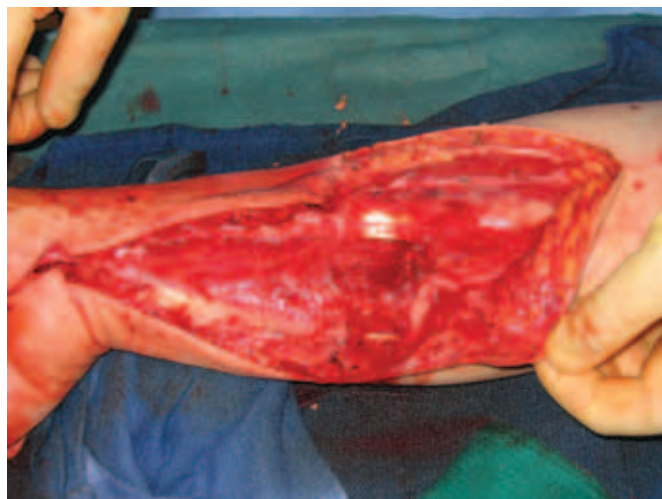

Figure 16. Volar forearm debridement and fasciotomy. Each muscle belly should be inspected for possible release (epimysiotomy) in addition to release of the forearm fascia. Image courtesy of the Borden Institute, Office of The Surgeon General, Washington, DC.

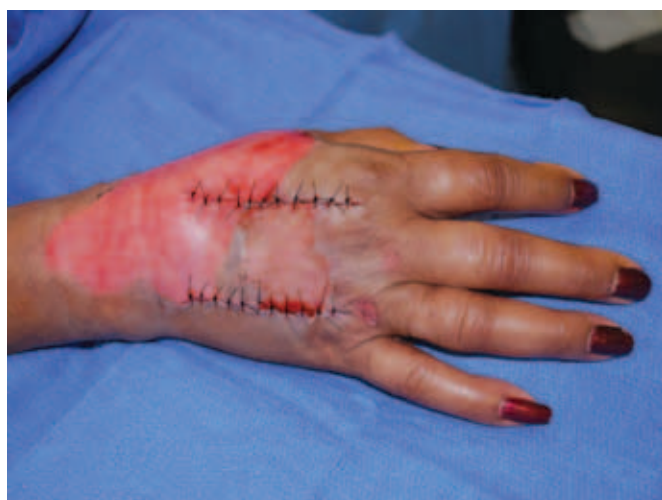
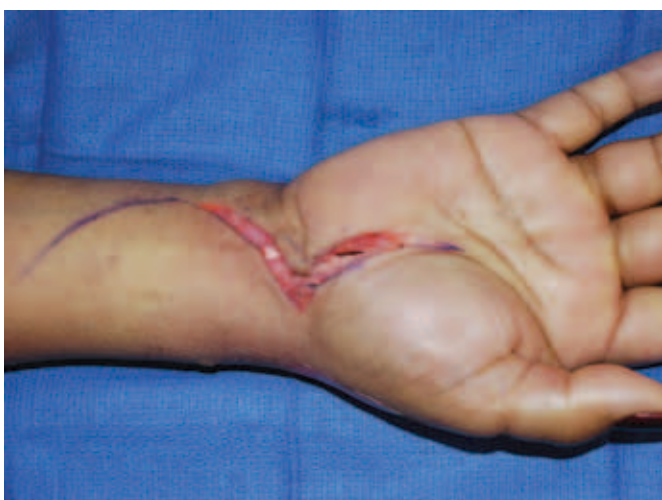
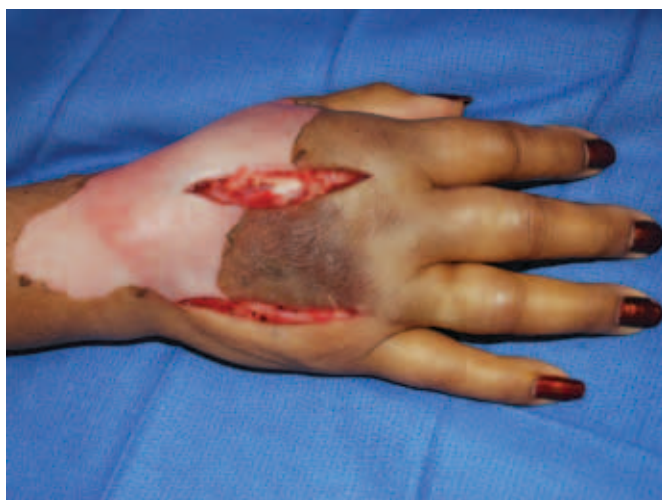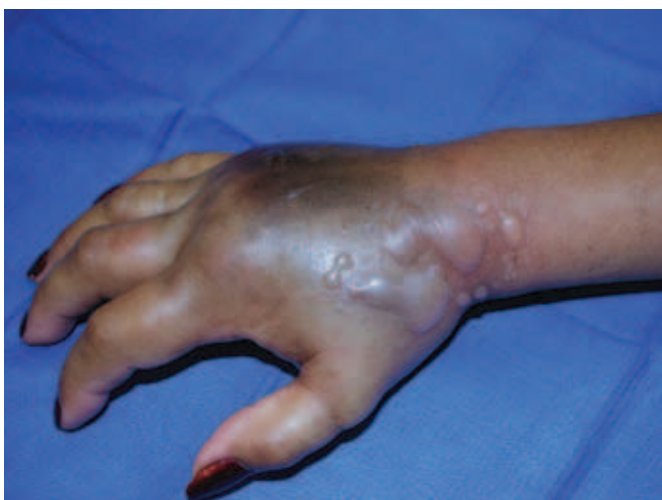Figure 17. (Middle Left) Hand compartment syndrome. (Middle Right) Dorsal skin incisions. (Bottom Left) Carpal tunnel release. (Bottom Right) Skin closure at 96 hours. Images courtesy of Rady Rahban, MD.

## Traumatic Limb Amputations

- Blast injury is a common cause of traumatic limb amputation.
- Traumatic limb amputations may be multiple and can result in lethal hemorrhage.
- Careproviders should provide immediate lifesaving interventions and avoid becoming distracted by visually disturbing limb amputations.
- The distal segments of amputated limbs should be checked for viable autologous vein graft sources before disposal.
- Traumatic fasciotomies are not a substitute for the purposeful and complete surgical release of compartment fascia.
- The preservation of vital tissues achieved through atypical delayed surgical amputations may result in better functional outcomes than limb shortening in order to get a conventional wound closure.

### Introduction

The term amputation can refer to an injury, an emergent procedure, a delayed procedure in planned staged care, a delayed procedure for treatment or prevention of a complication, an elective procedure perhaps for limb dysfunction, or an outcome. Thus, the context of usage for the term amputation should be made explicitly clear in medical communications and records by the provider and coder (Appendix 3). Care notes are often written with indelible markers on adhesive tape applied to the casualty in order to get important information to rearward hospitals when records are otherwise at risk of being lost (Fig. 18).

Historically, most major limb amputations in combat settings were injuries as the result of extensive limb trauma, a surgery for consequence of severe infection, or a surgery for irreparable major arterial injury.<sup>61,62,63</sup> The percentage of limbs lost because of major vascular trauma and severe infection had decreased in modern warfare. However, the greater use of explosive weapons in OEF and OIF has resulted in a steady number of limbs lost because of massive blast injuries.<sup>64</sup> Traumatic limb amputation accounts for 7.4 percent of major limb injuries in OEF and OIF; it was 8.3 percent in the Vietnam War.<sup>61,64</sup>

Blast injury is a common cause of traumatic limb amputation; traumatic limb amputation accounts for 7.4 percent of major limb injuries in OEF and OIF.

Limb salvage can occur when war surgeons use damage control vascular surgery principles and a team approach to injury triage and patient resuscitation.<sup>65,66,67</sup> It is important to note that surgical amputation (when indicated) should not be considered a failure of care, but rather, a key step of maximizing limb function. After debridement of all nonviable tissues, a reconstructive mindset and approach by careproviders are critical. A second operation to check the wound for possible debridement should be routinely planned 24 to 48 hours after the initial debridement, depending on the amount of initial tissue destruction and wound contamination. A fracture proximal to a traumatic amputation should be stabilized and is not an indication for more proximal amputation since successful fixation can help retain a longer and possibly more functional residual limb. The principle is to retain the maximum number of options for definitive care.<sup>63</sup>

### Initial Assessment

The closer the limb is to the explosion, the higher the likelihood of amputation. Casualties closer to



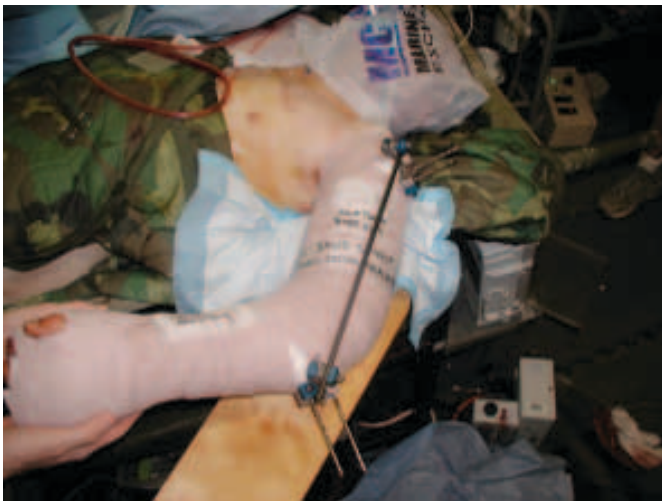

Figure 18. *Improvised patient information communication strategy. Patient information is written directly onto the dressing of a patient emerging from surgery. Image courtesy of Harold Bohman, MD, CAPT, MC, US Navy.*

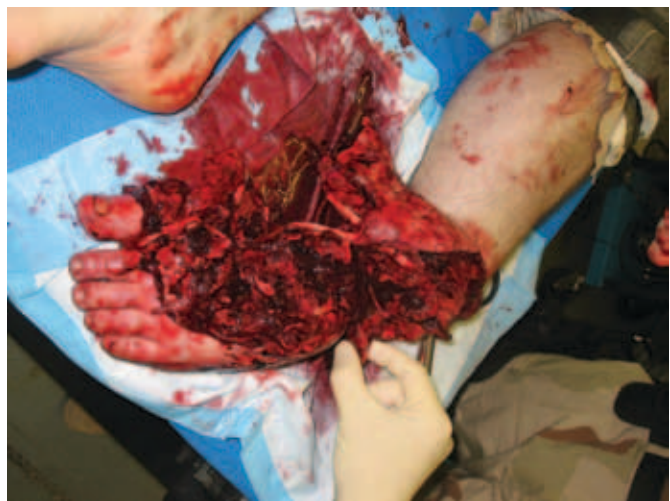

Figure 19. *Although traumatic limb amputations are devastating injuries, patient morbidity and mortality can be minimized with appropriate management. Image courtesy of the Borden Institute, Office of The Surgeon General, Washington, DC.*

explosions may have multiple amputations. The amputation site generally correlates with lesion severity as in the Abbreviated Injury Scale (AIS); more proximal lesions are more severe and lethal. Traumatic limb amputations are visually very disturbing, even to seasoned careproviders and can distract CCC providers from delivering optimal patient care (Fig. 19). Traumatic limb amputations are devastating injuries; however, if appropriately managed, patient morbidity and mortality can be minimized.<sup>15,63</sup>

The initial therapeutic approach to the patient with a traumatic amputation should follow the same protocol as with all combat casualties. The emphasis should be placed on identifying and treating immediately life-threatening conditions first. Once immediate life-threats are mitigated, further evaluation of a traumatic limb amputation is warranted. The zone of injury may be wide and not limited to the direct penetrating portion of the explosion, as the blunt effects may be proximal to the open wound. The degree of wound contamination can be severe.

Traumatic limb amputations may be multiple and can result in lethal hemorrhage. Careproviders should provide immediate lifesaving interventions and avoid becoming distracted by visually disturbing limb amputations.

Severe limb injuries, like subtotal traumatic amputations and mangled limbs, have been evaluated using a scale and assigned a score in order to help assess treatment options, such as the likelihood of successful limb salvage. Such efforts have been limited in their ability to predict outcomes or dictate care.<sup>68</sup> Similarly, the prognostic value of the insensate foot in association with limb salvage or surgical amputation has been evaluated. Researchers concluded that the insensate foot at presentation is neither prognostic of long-term plantar sensory status nor functional outcome, and should not be a component of a limb-salvage decision algorithm.<sup>69</sup> Two small case series have described how the technique of shortening and angulation of extremities with significant soft-tissue and bone loss can facilitate soft-tissue coverage.<sup>70,71</sup> Delayed gradual distraction of the shortened extremities is performed with a hinged circular external fixator. Further studies of this promising technique are required.

## Initial Resuscitation

Massive extremity hemorrhage is often an immediate life-threat in patients with traumatic proximal limb amputations.<sup>36</sup> An appropriately applied tourniquet on the residual proximal limb can be a first-line lifesaving intervention in such patients.<sup>15</sup> Proximal surgical control of the vascular structures can control distal sources of hemorrhage. Following the control of active limb hemorrhage, the patient can be evaluated for other life-threatening conditions followed by resuscitation of the casualty and the residual limb. Tactical situations such as extraction of casualties entrapped within vehicles (under enemy fire) may present unusual circumstances for prehospital surgical amputation. The amputated limb should accompany the casualty and should be assessed as a possible source of autologous vein graft harvesting.<sup>66</sup> Ideally, only the treating surgeon should discard the distal limb in order to ensure its therapeutic value to patient care has been fully assessed.

An amputated limb should be assessed as a possible source of autologous vein graft harvesting and discarded only after its therapeutic value to patient care has been fully considered.

## Primary (Completion) Amputation

In traumatic limb amputations, the nonviable distal portion is often attached to the proximal portion by a small skin bridge or a few intact tendons that span a segment of lost tissue. Transecting such bridging tissue is called a primary or completion amputation (Fig. 20). Primary amputation is indicated if the limb cannot be reconstructed or salvaged. This procedure is occasionally done in the emergency department, but it is typically performed during the first visit to the operating room. Other indications for primary (completion) amputation include: (1) ischemic limbs with irreparable vascular injury; (2) hemorrhage control refractory to other means; and (3) enabling lifesaving resuscitation in a patient whose injury physiologic burden (e.g., ongoing shock, hypothermia, acidosis, coagulopathy, or infection) will not permit limb salvage.<sup>63</sup> The latter exemplifies when limb-salvage techniques are beyond the physiologic capacity of the patient.<sup>65</sup>

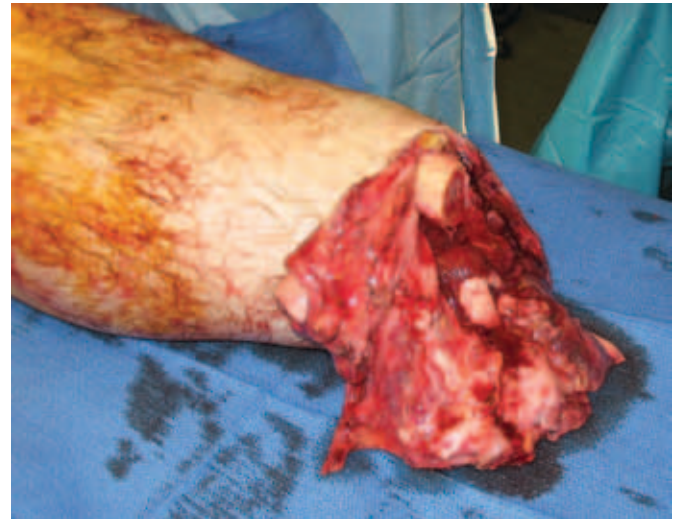

Figure 20. *Primary amputation is indicated if a limb cannot be reconstructed or salvaged. Image courtesy of the Borden Institute, Office of The Surgeon General, Washington, DC.*

Primary amputation is indicated if a limb cannot be reconstructed or salvaged. Primary amputation indications include ischemic limbs with irreparable vascular injury, hemorrhage control refractory to other means, or when limb salvage is beyond the physiologic capacity of the patient.

## Wound Debridement

Successful debridement depends on the surgeon's capacity to assess tissue for viability and the ability of the surgeon to remove contaminants.<sup>72</sup> Wounds associated with traumatic limb amputation are often grossly

contaminated and contain nonviable tissue in need of surgical debridement and copious irrigation (Fig. 21). During surgical debridement, all viable and uncontaminated tissues, however random in nature, should be retained with the hope of preserving maximal limb length and function.<sup>73</sup> Retention of maximum nerve length, especially in the upper extremity, has value since targeted reinnervation is possible later.<sup>74</sup> Therefore, in the initial surgery, resection of nerves should not be routinely performed.

During surgical debridement for completion amputation, all viable and uncontaminated tissues should be retained with the hope of preserving maximal limb length and function.

Certain types of wound contaminants may require special care. Oil-laden wounds may require soap or an additive that may safely aid in the removal of what is not water-soluble. Unfortunately, there is little data to determine best practices. White phosphorus is a chemical that is in some munitions used for illumination. White phosphorus is actually a yellow, waxy chemical that ignites spontaneously when exposed to air.<sup>75</sup> It is used as a filling for various projectiles, as a smoke-producing agent, and has an incendiary effect. White phosphorous smoking wounds can be covered in saline, but this only temporarily staves off recombustion. There is a thermal component to the injury when there is combustion as it is an exothermic process. Most of the cutaneous injury resulting from white phosphorus burns is due to the

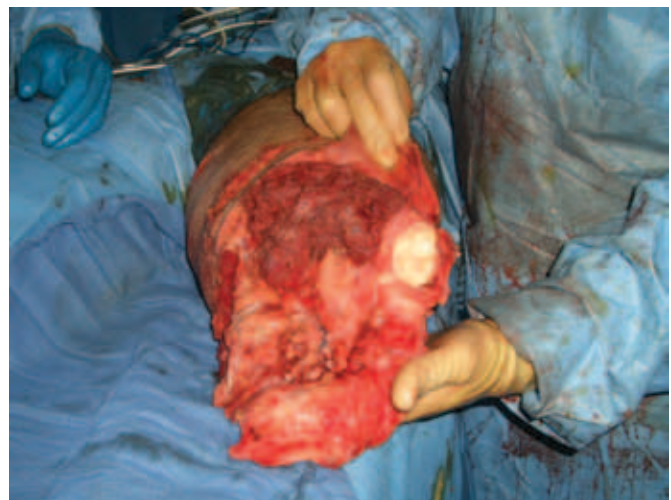
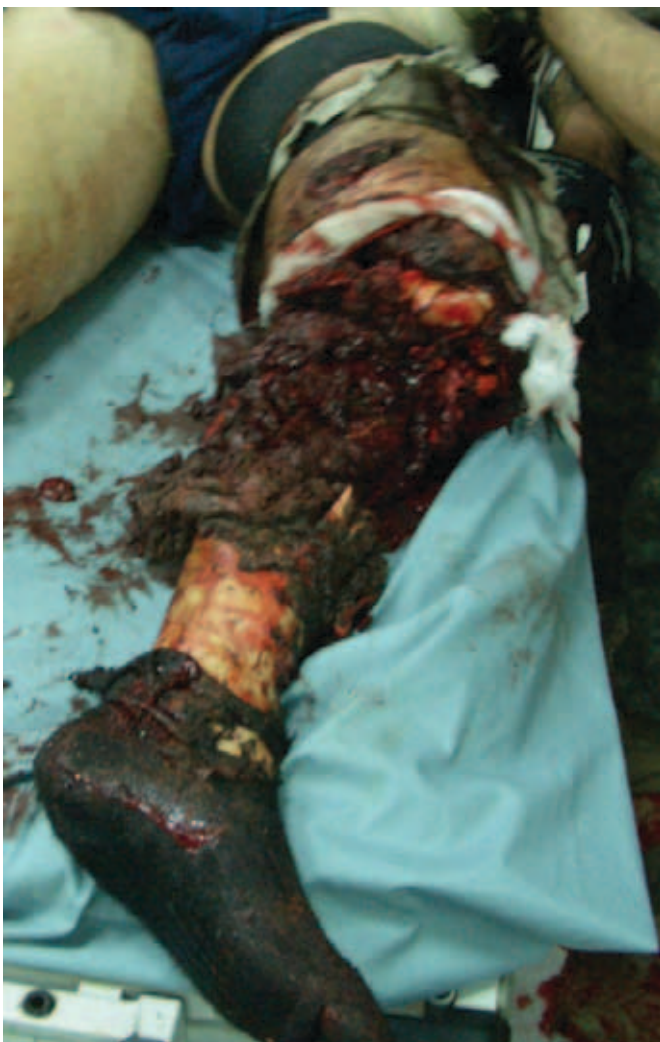

Figure 21. (Left) Wounds associated with traumatic limb amputation are often grossly contaminated and contain nonviable tissue in need of surgical debridement and copious irrigation. (Above) During surgical debridement, all viable tissues should be retained with the hope of preserving maximal limb length and function. Images courtesy of Glenn J. Kerr, MD, MAJ, MC, US Army.



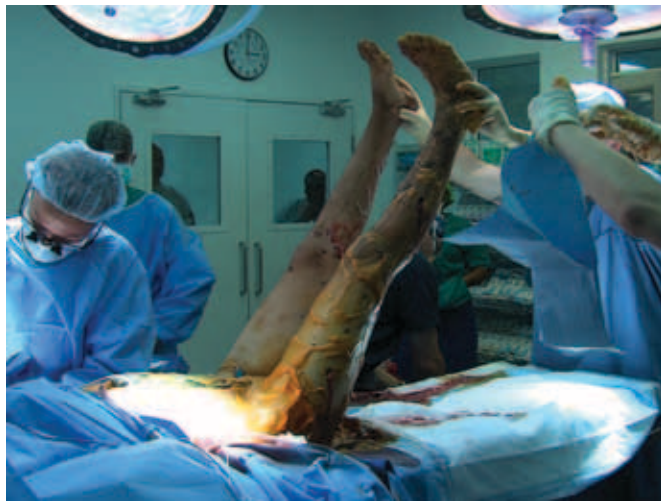

Figure 22. Surgical limb preparation should be quite proximal because the zone of injury or planes of traumatic dissection may be more proximal than suspected on physical examination.

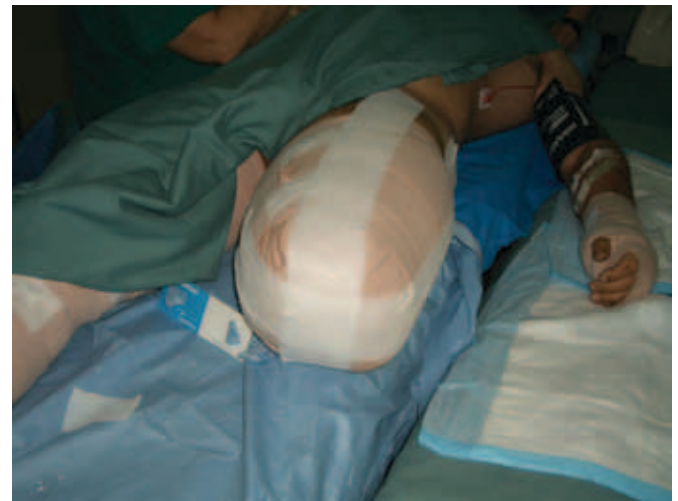

Figure 23. Combat extremity wounds should not be closed primarily. This residual proximal limb wound was dressed with bulky dry dressings. Image courtesy of Glenn J. Kerr, MD, MAJ, MC, US Army

ignition of clothing and is treated as a conventional burn. Copper sulfate was once recommended for aid in locating the white phosphorus during debridement, but this is no longer recommended as copper sulfate use is associated with fatal hemolysis.<sup>75</sup> If copper sulfate solutions are used, they should be washed away immediately and not used as a wet dressing. White phosphorus-injured patients should be dressed with saline-soaked dressings to prevent reignition of the phosphorus by contact with the air.<sup>76</sup> Members of the US Army Burn Center have patented a gel for use in treatment of white phosphorus wounds, but there is little data regarding its use in a combat setting.

### Fasciotomy

Fasciotomy is often necessary in limbs with traumatic amputations. It would be a mistake to think that surgical fasciotomies are not necessary following traumatic amputations. While traumatic limb amputations create fascial disruptions, these traumatic fasciotomies (disruptions) do not adequately reduce intracompartmental pressures and do not equate to a surgical fasciotomy. Traumatic fasciotomies are not a substitute for the purposeful and complete surgical release of compartment pressures.<sup>41</sup> The injury proximal to

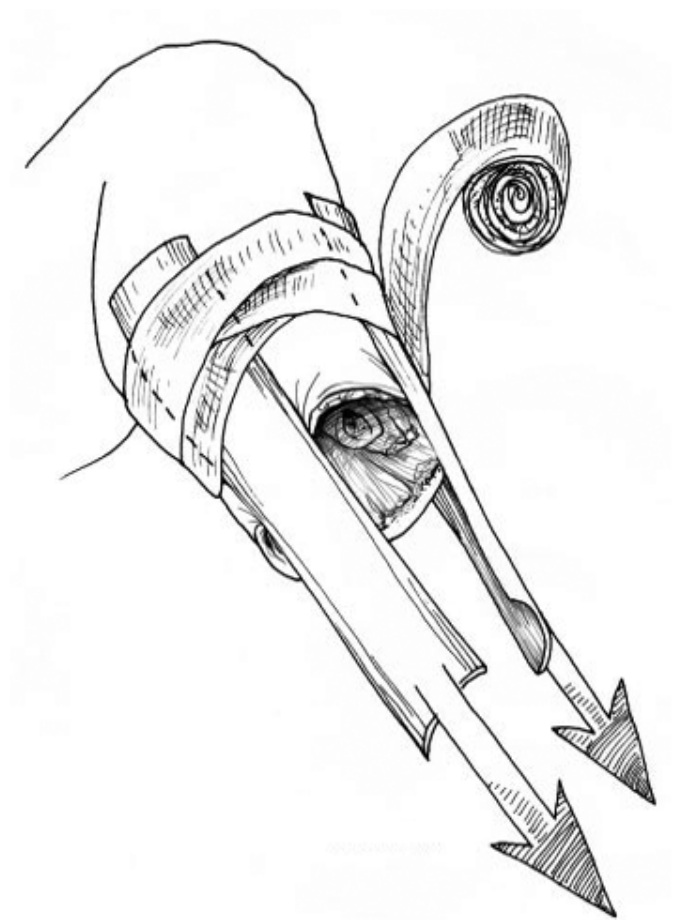


Figure 24. Skin traction remains an option to preserve limb length if there is a planned four (or more) day interval between surgeries. Image courtesy of the Borden Institute, Office of The Surgeon General, Washington, DC. Illustrator: Jessica Shull.

the amputation may also warrant fascial release. The fascial compartments of the residual proximal limb should be examined and fasciotomies performed if necessary for treatment or prevention of compartment syndrome.

Traumatic fasciotomies are not a substitute for the purposeful and complete surgical release of compartments.

### Surgical Amputation and Wound Care

Surgical limb preparation should be very proximal (sometimes more proximal than the groin or axilla) because the zone of injury or planes of traumatic dissection are more proximal than suspected on physical examination (Fig. 22). Proximal control of arteries may require access to the pelvis, abdomen, or chest. Use of a tourniquet during the surgery is common to help with hemorrhage control. Ligation of distal major artery and vein injuries is indicated to avoid rebleeding after resuscitation, transport, limb mobilization, or dressing changes. Traumatic nerve stumps have gentle traction applied and are sharply transected proximal to the zone of injury and proximal enough so that the nerve retracts under soft-tissue. Large nerves, such as the sciatic nerve, may require ligation if the vessels within them bleed. Failure to ligate such nerves may risk rebleeding.

Combat extremity wounds are not closed primarily. The skin can often be loosely approximated with a few sutures to keep some skin tension and coverage while allowing drainage from the open wounds during transport (Fig. 23). Skin traction remains an option to preserve limb length if there is a planned four or more day interval between surgeries. Skin traction technique and postoperative management are described well in the Emergency War Surgery Manual (Figs. 24 and 25).<sup>63</sup> The residual proximal limb should be dressed with bulky dry dressings. While data are limited to anecdotal reports by war surgeons, negative-pressure wound therapy appears best avoided at the initial surgery for wounds at risk for rebleeding. Negative-pressure wound dressings can be considered after the casualty and wounds are stable without bleeding for 48 hours (following initial resuscitation) (Fig. 26).

### Delayed Amputation

Indications for delayed limb amputation may include complications like refractory wound sepsis, failed

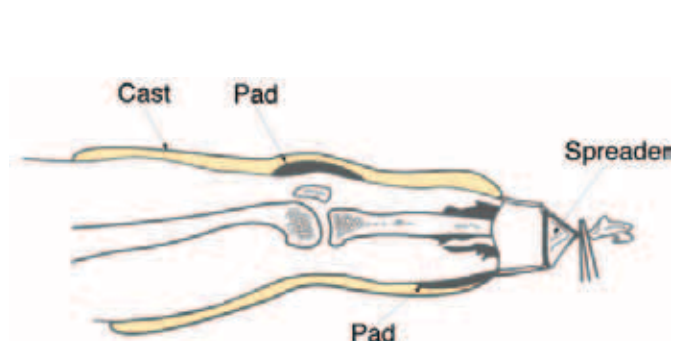


Figure 25. A bivalved transportation cast (prior to patient transport) allows for continuous traction. Image courtesy of the Borden Institute, Office of The Surgeon General, Washington, DC. Illustrator: Jessica Shull.

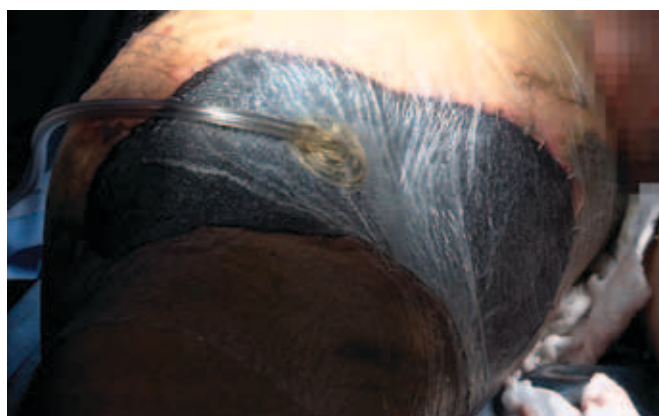


Figure 26. Negative-pressure wound dressings can be considered after the casualty is stable and wounds are without bleeding for 48 hours following initial resuscitation.



flap coverage or limb salvage (due to vascular or musculoskeletal causes), and selective amputation to optimize limb function (e.g., relieve pain or prosthetic fitting).<sup>77</sup> Selective amputation is performed when the distal salvaged limb function is less than that with a prosthetic. This decision is typically deferred to the definitive treatment facility after discussion with the casualty. Standard, conventional amputation levels were developed mostly from patients with diabetic vasculopathies. These standard civilian-based practices do not apply to most combat casualties. Positive outcomes have been documented for amputees undergoing delayed surgical amputations of atypical configurations (level and flaps).<sup>77</sup> Atypical surgical amputations do not employ standard or traditional levels of bony cuts, standard (textbook) skin incisions, or typical musculofascial flaps to cover the cut bone and conform to conventional prosthetic fittings.<sup>77</sup>

Initial efforts to maximally salvage viable tissue following atypical limb amputations enable broader future treatment options for the distal limb. Thus, preservation of viable tissues appears to result in better outcomes than limb shortening in order to get a typical wound closure.<sup>77</sup> Open guillotine amputations have fallen out of favor and are only performed based on the specific margins of tissue loss or necrosis.<sup>77</sup> The US Army recommends performing atypical amputations so that rearward care can optimize outcomes.<sup>78</sup> Tissue viability is used to determine the extent of debridement. The initial surgery is performed without regard for the likely subsequent amputation level.

The preservation of vital tissues achieved through atypical delayed surgical amputations may result in better functional outcomes than limb shortening performed in order to get a conventional wound closure.

Atypical stump flaps (sometimes called flaps of opportunity) can be used in later surgeries to close the wound when it is ready for closure (Fig. 27). Such flaps are not fashioned during the initial surgery. For example, short (as little as one- to two-centimeter stumps) and even incomplete transtibial stumps can help avoid problems with through-the-knee amputations like the retraction of tendons or skin that may force more proximal amputation later for definitive wound closure.

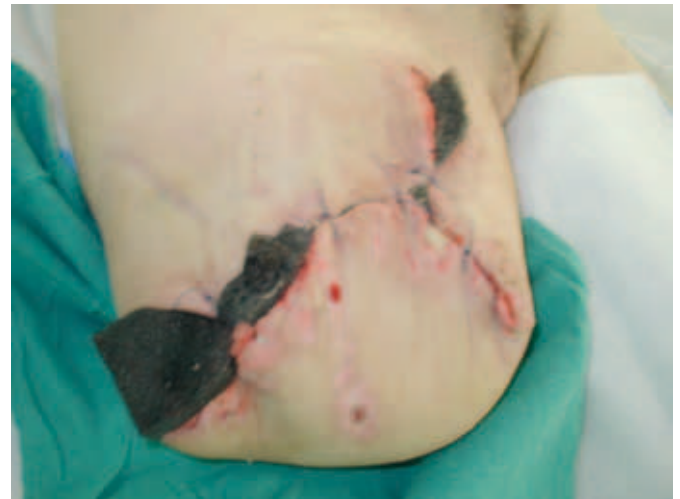
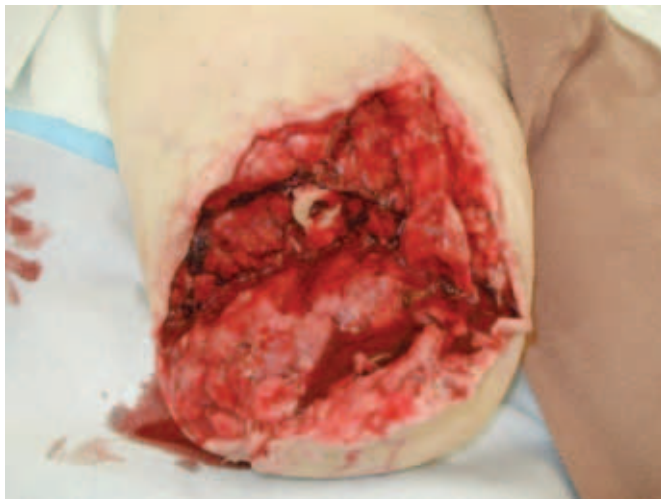
Figure 27. *Atypical stump flaps (sometimes called flaps of opportunity) can be used in later surgeries to close the wound when it is ready for closure. Images courtesy of Robert R. Granville, MD, COL, MC, US Army.*

## Rehabilitation

Rehabilitation services at specialized amputee centers have been documented to result in improved outcomes.<sup>79</sup> Besides the surgical reconstruction of residual limbs (flaps, bone grafting, amputation revision), casualties undergo a comprehensive evaluation and treatment plan for a broad spectrum of issues like traumatic brain injury, tympanic membrane rupture, and psychological and social screening. Currently in the US military, a physiatrist is often the leader of the rehabilitation team. Each casualty is routinely assigned a case manager for coordination of the myriad of medical and administrative issues they will face. Casualties are sent to the most appropriate facility based on injury severity. Rehabilitative care may be provided at a small base and hospital (simple injuries) or may occur at a tertiary medical center (complex injuries). One tertiary care center is San Antonio Military Medical Center (formerly Brooke Army Medical Center), which is a Level I trauma center with a burn center and a rehabilitative and amputee center called the Center for the Intrepid.<sup>80,81,82</sup> In summary, refinements in traumatic amputation care, amputation surgery, and aftercare have led to improved patient outcomes.<sup>83,84</sup>

## Combat Casualty Wound Care

- The management of combat wounds differs from civilian wound care.
- Combat wounds differ in degree and number from wounds occurring in the civilian sector.
- Combat wounds evolve more rapidly than civilian wounds and require more frequent reevaluation following injury.
- Initial postoperative dressings on blast injuries should routinely be dry, bulky dressings.

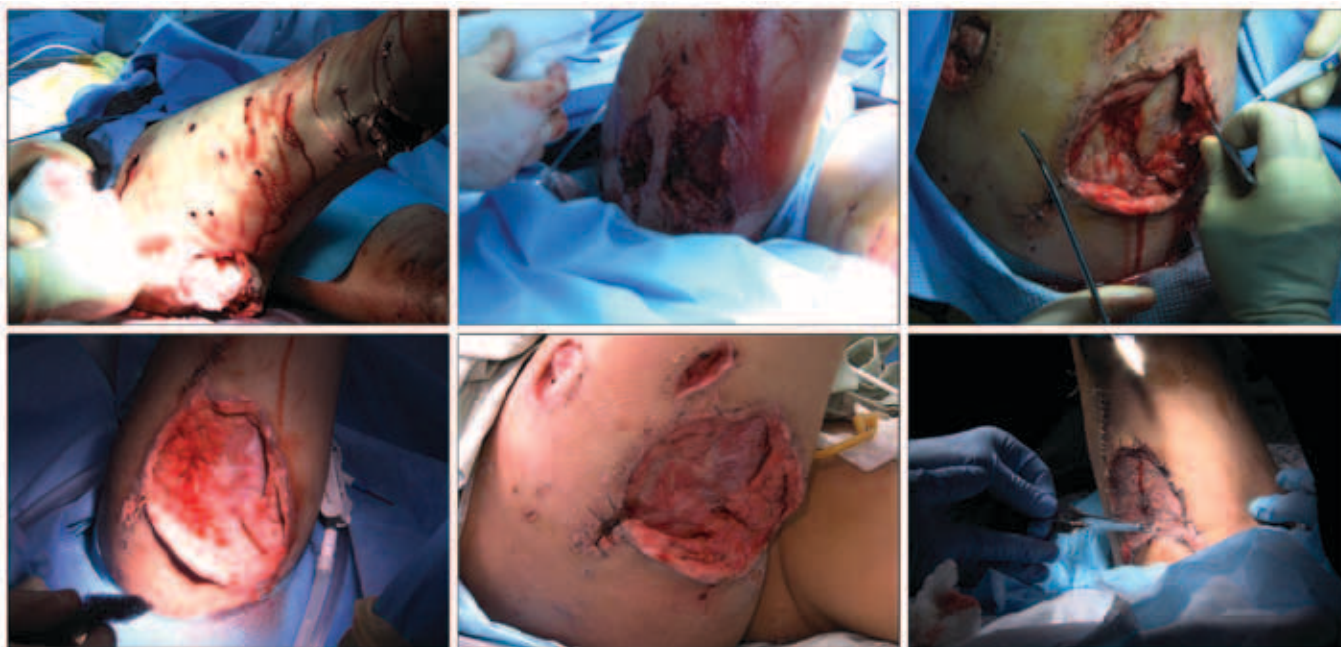

Figure 28. *Combat wounds evolve more rapidly than civilian wounds and require more frequent reevaluation following injury. Over time, bleeding and swelling ensue and resolve, while tissues can become devitalized and revitalized. This sequence of images shows the initial wound on day one (Top Left) and evolution (Left to Right) of the wound in response to multiple debridements over a two-week timeframe (Bottom Right).*

## Introduction

War wounds are often the result of higher-energy mechanisms than those in civilian sector. As such, combat wound size, severity, and lethality are often greater.<sup>56</sup> Combat-associated wounds evolve in the hours to days following the initial injury. What one careprovider sees at the point-of-injury often differs substantially from what is seen at the forward hospital (hours later) and then the rearward hospitals (days later) (Fig. 28). Over time, bleeding and swelling ensue and resolve while tissues can become devitalized and revitalized. Wound edema typically peaks at one to two days following the initial injury.<sup>48,56</sup> However, the consequences of initial treatments (e.g., tourniquet ischemia reperfusion and resuscitation fluid edema) may delay the timing of maximal edema to five days.<sup>56</sup> Both the magnitude of tissue edema and the variability of the time lag from initial injury to maximal edema can be startling to careproviders who have minimal CCC experience.<sup>13</sup>

Combat wounds evolve more rapidly than civilian wounds and require more frequent reevaluation following injury.

## Extremity Resuscitation and Wound Management

Following injury (battle conditions permitting), initial wound treatment involves covering of wounds with sterile dry dressing bandages and splinting of bony injuries to prevent further injury.<sup>85</sup> Combat casualty care providers should address obvious life-threatening priorities first. The life-over-limb principle always applies. Uncontrolled limb wound hemorrhage is often identified as an immediate priority. Hemorrhage control options include: (1) manual direct pressure over the wound or proximal pressure points; (2) limb elevation; (3) hemostatic dressings; and (4) extremity tourniquet application. Tourniquets, a hemorrhage control adjunct to damage control resuscitation, provide maximal benefit the earlier they are applied following difficult to control extremity wound hemorrhage.<sup>15</sup>

Once the patient has been evacuated from the point-of-injury to the next echelon of care, the combat casualty should be reassessed. Immediate life-threats need to be addressed, including the control of any persisting wound hemorrhage. Subsequent to addressing immediate life-threats, limb wound management should consist of neurovascular examination of the limb, wound inspection, and wound irrigation with the goal of removing gross contamination.<sup>85</sup> If limb salvage is an option, limb perfusion must be optimized

### CARE OF A COMBAT LIMB WOUND

- Control hemorrhage; tourniquets are temporary adjuncts
- Prevent or treat shock, hypothermia, and coagulopathy
- Immobilize limb fractures and joint dislocations to minimize further injury
- Limit wound contamination to reduce infection risk
- Debride wounds by removing devitalized tissue, while maximally retaining viable tissue
- Keep wounds clean by repeated irrigation and debridement
- Cover wounds to reduce infection risk
- Prevent deep venous thrombosis and emboli
- Provide reconstructive care to maximize casualty and limb function
- Provide limb care within comprehensive rehabilitation

Table 3. *Key steps in the care of a combat limb wound.*

and further injury must be prevented. Immediate priorities include: (1) diagnosis and treatment of vascular injury and compartment syndrome; (2) shunting, vein grafting, or primary repair of arterial injuries; (3) immobilization of unstable bony injuries; and (4) prevention of wound infection. A summary of key steps in the care of combat limb wounds is provided in Table 3.

## Special Wounds

### Vascular Injury

The optimal management of extremity vascular injuries sustained in war requires collaboration between orthopaedists, general surgeons, and vascular surgeons. The process may involve temporizing vascular shunts, definitive repairs, or vascular reconstructions (Fig. 29).<sup>86</sup> The challenge of emergently addressing extremity vascular injury repair can tax a trauma system's personnel, supplies, and operative resources.<sup>87</sup> Ideally the regional trauma system serves to direct available resources towards providing optimal care. Optimal management of these complex injuries requires up-front planning, coordination of care, and frequent process improvements.

Vascular injuries may be treated with temporizing vascular shunts or limited vascular procedures at Level II facilities, whereas definitive repairs or vascular reconstructions can be provided at Level III facilities.

Currently in the US military, Forward Surgical Teams can perfuse limbs with shunts or perform limited vascular procedures. Most Combat Support Hospitals (Level III facilities) provide extensive limb revascularization capacity. The scope of practice for orthopaedic surgeons and general surgeons in war broadens and demands that they perform more vascular procedures than they would otherwise perform in more controlled environments. Damage control principles should be applied to the care of acute wartime vascular injuries with emphasis on the effective correction of physiologic shock.<sup>65,66</sup> To this end, surgical time must be limited to essential resuscitative procedures, with the goal of returning to the operating room after physiologic parameters are restored and stabilized. A detailed discussion of vascular injury repair is provided in the Damage Control Surgery chapter.

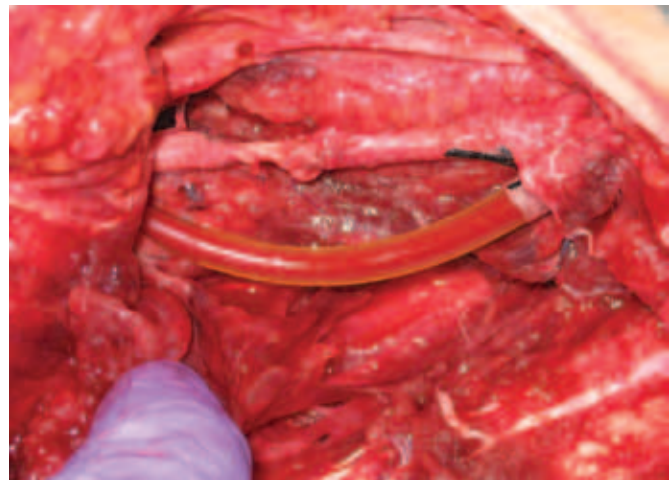


Figure 29. *Temporizing vascular shunt placed in the brachial artery at a Level II facility. Image courtesy of the Borden Institute, Office of The Surgeon General, Washington, DC.*

### Muscle, Tendon, and Ligament

Skeletal muscle repair is an uncommon surgical task in early CCC, but it is sometimes needed after the first debridement and surgery. Complete disruption or transection of a muscle belly or tendon can lead to morbidity without surgical repair. Hence, if no agonist muscle exists (or is too small), surgical repair may be indicated for improved future muscle strength, patient satisfaction, or cosmetic results.<sup>88</sup> Also,



the need to cover underlying tissues such as nerve, tendon, or bone may also prompt surgical repair of muscle transections. Recent advancements in skeletal muscle repair have emphasized epimysium-based suturing.<sup>89,90,91,92,93</sup> Crushed limbs or those entrapped and ischemic for prolonged times pose management difficulties. A delayed fasciotomy (greater than 12 hours following injury) may increase sepsis and mortality rates compared to conservative care.<sup>14</sup>

Ligament repair can be done early, but not necessarily at the first surgery, for complete disruption of major ligaments leading to joint instability. Large ligaments with joint instability may be repaired end-to-end, oversewn, reinforced, or reinserted anatomically into their bony origins with nonabsorbable suture when the wound is clean. In the setting of gross wound contamination, a knee-bridging external fixator and serial surgical debridements prior to primary ligament repair or reconstruction are indicated. Serial assessment of joint stability and stiffness over time can help guide follow-on care.

Blood vessels, tendons, nerves, bone, and open joint spaces should be covered throughout care, at least temporarily by loose apposition of the surrounding tissue or skin so that the delicate tissues do not dry out. This drying (with resultant stiffness) risk is greatest in exposed segments of immobilized open joints.<sup>94</sup> However, good results with motion of open joints can be attained if the joint is mechanically stable.<sup>94</sup> All other soft-tissue wounds should be left open so that drainage may occur.

Blood vessels, tendons, nerves, bone, and open joint spaces should be covered by loose apposition of the surrounding tissue or skin, so that the delicate tissues do not desiccate. All other soft-tissue wounds should be left open so that drainage may occur.

### Open Joint Injury

A penetrating wound near a joint such as the knee may cause a traumatic arthrotomy, a communication between the wound and joint space where foreign matter or bacterial contamination may remain in the joint and lead to septic arthritis (Fig. 30). Retained foreign matter or contamination in diarthrodial (freely moveable) joints is an indication for early surgical debridement and irrigation of the joint space and wound.

If a traumatic arthrotomy is suspected, a saline load test can be performed to help ascertain if the wound communicates with the joint space. A saline load test is the needle administration of sterile normal saline into the joint space through an uncontaminated route through the skin and soft-tissues. Enough saline is injected into the joint space to cause visible leakage if traumatic arthrotomy is present. The leakage may be seen in the wound if there is enough saline and limited blood and other obscuring factors. The saline load test is positive if the leakage is detected and negative if not detected. The saline load test has limitations in clinical practice. In a study, false positive clinical results occurred in 39 percent and false negative results in

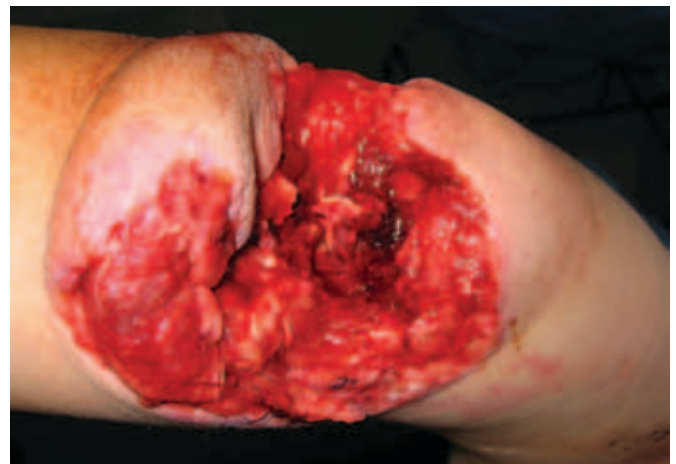

Figure 30. Traumatic arthrotomy with extensive soft-tissue and bone injuries of the elbow due to a gunshot wound. Image courtesy of the Borden Institute, Office of The Surgeon General, Washington, DC.

43 percent of casualties; there were no complications from the use of the test.<sup>95</sup> In several studies using the saline load test to evaluate small lacerations around the knee, saline loads of less than 145 to 194 milliliters were of questionable sensitivity. The authors concluded small volume saline load tests should not be used to rule out open knee injuries.<sup>96,97</sup> The injection of methylene blue has traditionally been used as an alternative agent for detecting open joint injuries. The performance characteristics of intraarticular injection of methylene blue for detecting open joint injuries remain poorly defined. Of note, the use of high-dose intravenous methylene blue as a diagnostic agent (for alternative procedures) has been linked to a variety of neuropsychiatric adverse side effects.<sup>98,99,100,101</sup> These rare cases were possibly associated with concomitant patient use of medications affecting serotonin metabolism.

If doubt exists as to whether a wound communicates with a major joint space, the principle of exploration of the traumatic wound, followed by debridement and irrigation, should be practiced.

## Nerve Repair

Penetrating war trauma with associated peripheral nerve injury is uncommon.<sup>4</sup> When such injuries occur, they can be severe, require complicated care, and result in persistent disability.<sup>102,103</sup> Historically, advances in nerve repair, grafting, tendon transfers, and rehabilitation have been developed in part through CCC.<sup>103</sup>

The 1988 edition of the Emergency War Surgery Manual provides a detailed discussion of the management of peripheral nerve injury.<sup>104</sup> It details arteriovenous fistulas, clots and contusions, missile fragments, and causalgia associated with nerve injury. The 2004 edition of the Emergency War Surgery Manual discourages primary repair of peripheral nerve injuries in war wounds and advocates for prevention of desiccation by soft-tissue coverage of the nerve.<sup>105</sup> Specifically, debridement of nerve is not indicated except for grossly destroyed areas of the nerve and trimming frayed edges.<sup>105</sup> Recent advancements in the field of targeted reinnervation in the setting of upper extremity amputations have led to the goal of limiting initial nerve debridement to just the nonviable portions and preserving nerve length so that reinnervation, if chosen, is assisted with longer nerve stumps.<sup>74</sup> Surgeon experience is needed for the surgical repair of peripheral nerves. Loupe magnification is recommended for surgeons, and fascicular and epineurial repair appears prudent in most simple cases. The tagging of nerve with a fine, monofilament, nonabsorbable suture (e.g., 6-0 nylon) is not mandatory but can assist in identifying nerves during later surgeries.

Primary repair of nerve injuries should not be performed in combat settings. Initial objectives include judicious debriding of nonviable neural tissue and avoiding desiccation by ensuring adequate soft-tissue coverage of wounds. Definitive nerve repair can be accomplished at rearward facilities following patient evacuation.

## War Wound Closure

- Extremity combat wounds should not be closed primarily.
- Cover bone, tendons, nerves, vessels, or joints with loosely apposed skin to prevent desiccation of underlying tissue and minimize risk of wound contamination.
- Wound closure decreases nosocomial infections, but closure too early risks wound infections associated with devitalized tissue.
- Zig-zag use of suture or vessel loops can provide wide wounds with some tension in order to aid in closure.

## ***Introduction***

No extremity wound sustained during combat should be closed primarily at the first debridement because the risk of infection from residual contamination is very high.<sup>105</sup> The one exception is closing soft-tissues over open joint injuries following thorough joint washout and wound debridement in an operating room. Definitive closure of combat wounds can be done in several ways: (1) delayed primary closure; (2) negative-pressure wound dressings; (3) skin grafting; (4) local or free tissue transfer; and (5) healing by secondary intention. One or a combination of the above methods may be selected based on the nature and location of the wound, material available, and skill of the careprovider and treating facility resources.<sup>106</sup> From non-US casualties treated in a Combat Support Hospital in Iraq, gram-negative bacteria were the most commonly isolated pathogens.<sup>107</sup> Cultures of respiratory fluid yielded positive results earlier than cultures of wound or blood samples and potentially serve as an earlier marker of future infections. Continued aggressive infection control for all casualties is needed.<sup>107</sup>

With the exception of open joint injuries, no extremity wound sustained during combat should be closed primarily.

## ***Timing of Wound Closure***

While primary closure of wounds within the strict controls of mature civilian trauma centers has shown good results, primary closure of war wounds is deemed inappropriate by experts in CCC.<sup>108,109,110</sup> Preparation of a wound for closure requires clinical judgment and is based upon: (1) the appearance of the tissue (i.e., clean, granulating, healthy tissue versus foul smelling and purulent tissue); (2) the absence of active infection; and (3) the ability to achieve a tension-free closure.

Classically, war wounds are not closed primarily since the wounds are often severe and contaminated. Occasionally the US Army has had to mandate delayed closure guidelines, such as in World War II.<sup>111</sup> Part of the problem is that the surgeon cannot see all types of contamination such as bacteria or fine particulate matter.<sup>72</sup> Another problem is that the wound core may include obviously nonviable tissue but there is a surrounding zone of tissue that may be devitalized but not dead, such that there is limited perfusion, a so-called zone of stasis that may evolve and swell over time.<sup>72</sup> The surrounding zone of stasis may be susceptible to over-resuscitation or may be responsive to negative-pressure therapies that may reduce swelling locally.<sup>72</sup>

Timing of wound closure is dependent upon the appearance of the tissue, absence of infection, and ability to achieve a tension-free closure.

## ***Wound Closure Techniques***

Delayed primary closure of war wounds can be effectively performed after planned, staged wound debridements.<sup>56</sup> The stapling of a zig-zag pattern of suture or vessel loops across wide wounds with some tension can aid in closure by keeping the skin from passively retracting further (Fig. 31). Mild drainage and granulation can occur before closure. Such suture patterns can be periodically retightened by pulling on the suture and adding a staple in incremental closure, perhaps avoiding an operative visit.

Early in OEF and OIF, CCC providers became familiar with negative-pressure wound dressing devices,

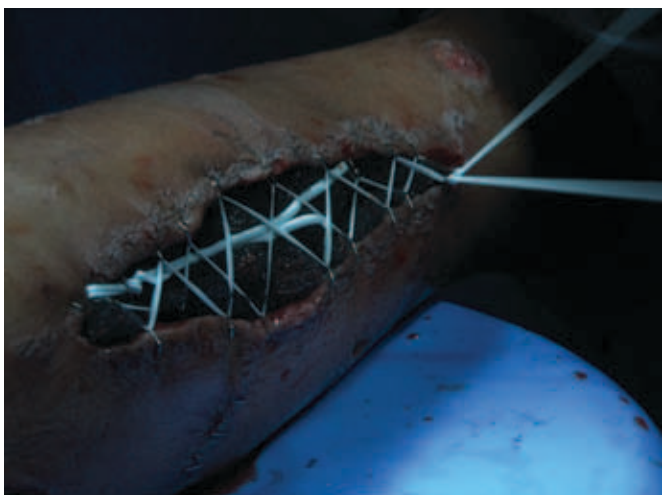


Figure 31. (Top Left) *The stapling of a zig-zag pattern of suture or vessel loops across wide wounds can aid in closure by keeping the skin from passively retracting further. Such patterns may be periodically retightened through increased tension.*

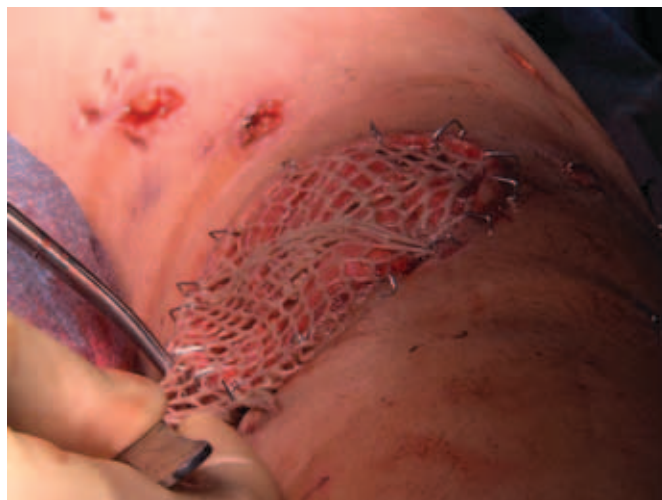

Figure 32. (Top Right) *In areas of skin loss with adequate muscle or granulation tissue coverage, a skin graft may be the treatment selected to cover the wound.*

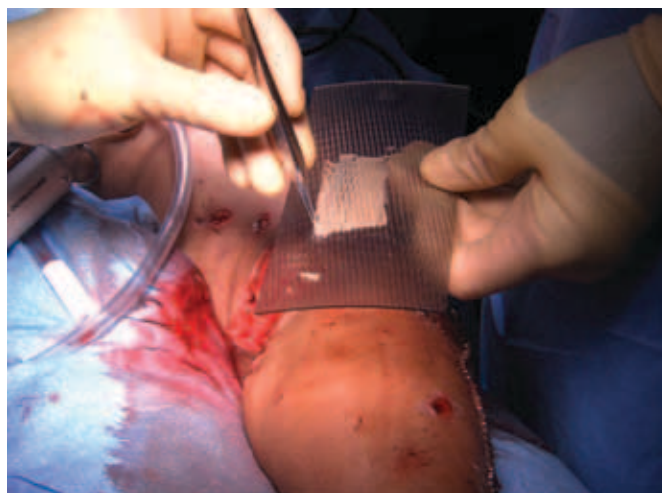

Figure 33. (Bottom Right) *Meshing of the skin allows for greater graft coverage, improved conformity of the graft, and drainage of serous fluid.*

as did civilian careproviders in the US. As familiarity and positive clinical outcomes became common, more frequent use ensued for a wider spectrum of wounds.<sup>56</sup> In areas of skin loss with adequate muscle or granulation tissue coverage, a skin graft may be the treatment selected to cover the wound. Most commonly, a meshed split-thickness (0.015 inch) graft is used over the exposed soft-tissues.<sup>56</sup> Meshing the graft allows for more area coverage per donor site harvested, but more highly meshed grafts will contract more as they heal and are less cosmetically acceptable (Fig. 32).<sup>56</sup> Full-thickness skin grafting is considered for areas such as the palms of the hand where contracture of the graft is undesirable (Fig. 33). The skin graft may also be used in combination with delayed primary closure of a wound to first make the area needing a skin graft smaller. After serial debridements, the wound edges are approximated primarily, and then a skin graft is used to cover areas that cannot be closed because of tissue loss.

Local rotational tissue transfer (local flaps) can be a reliable way to achieve wound closure in areas lacking muscle or granulation tissue coverage (Fig. 34).<sup>56</sup> Common reliable rotational flaps in the lower extremity include the medial and lateral gastrocnemius flaps, soleus flap, and the reverse sural artery flap (Fig. 35).<sup>56</sup> In the upper extremity, the radial forearm flap is reliable.<sup>56</sup> Free tissue transfer or flaps are options as well, but it must be remembered that the zone of injury in war wounds is often larger than the open wound itself.<sup>56</sup> This makes flap anastomosis within the zone of injury complicated.<sup>106,110,112</sup>



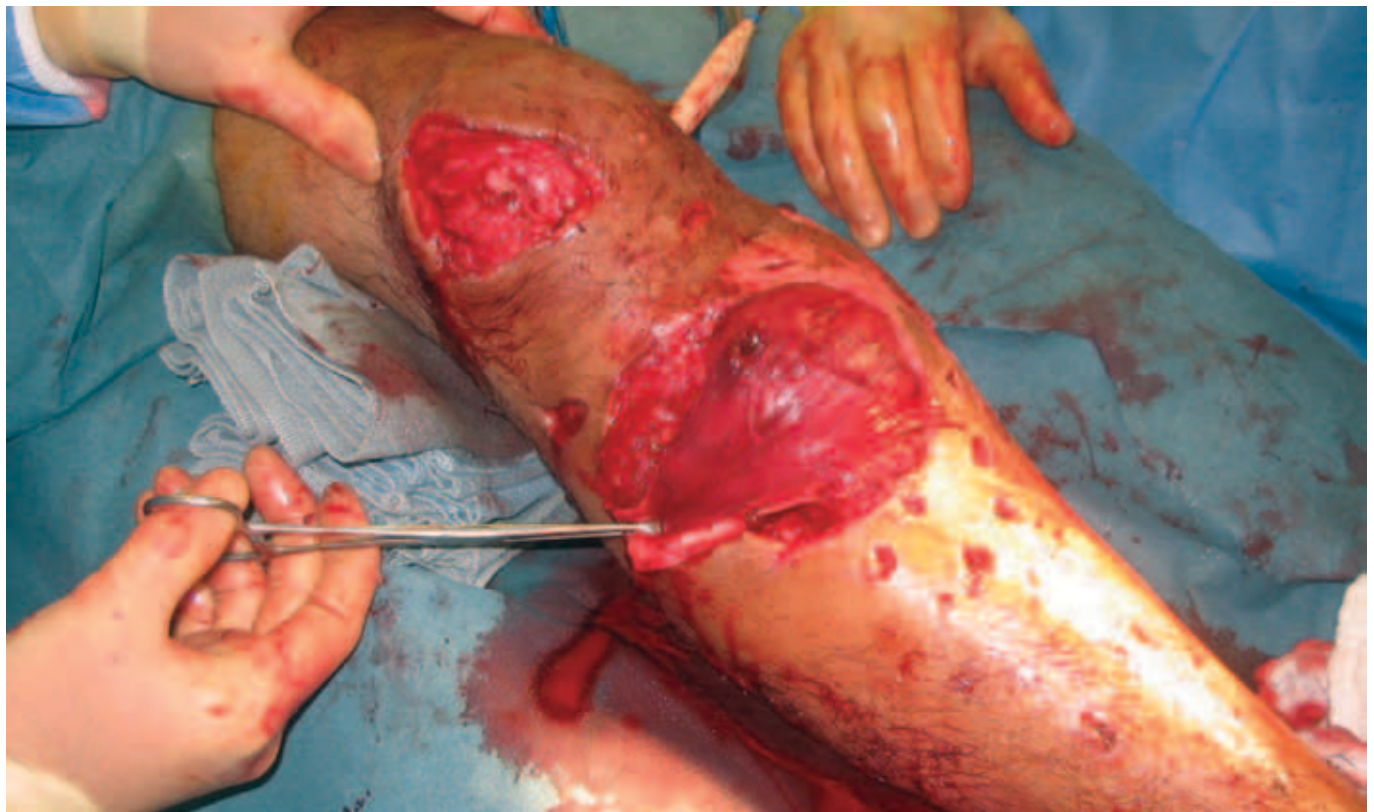
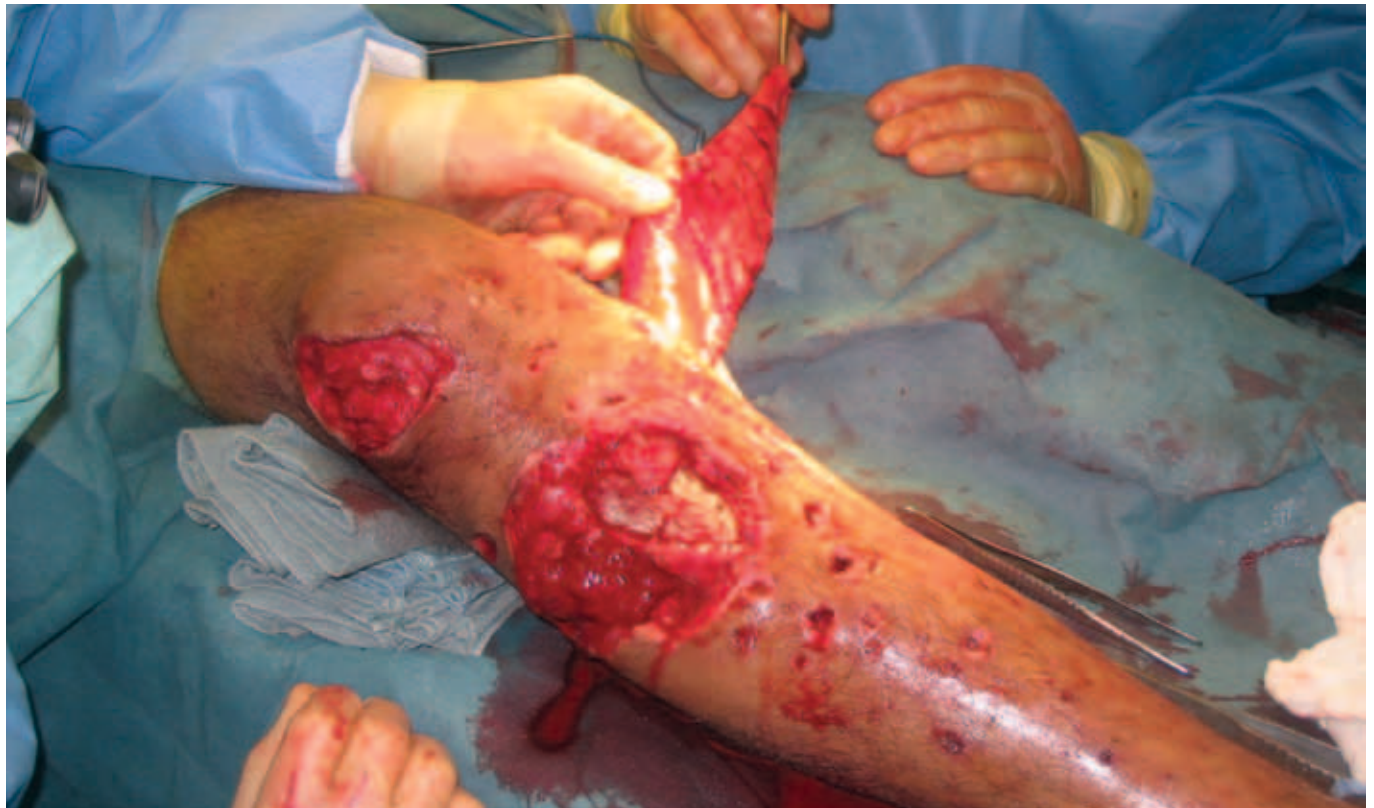
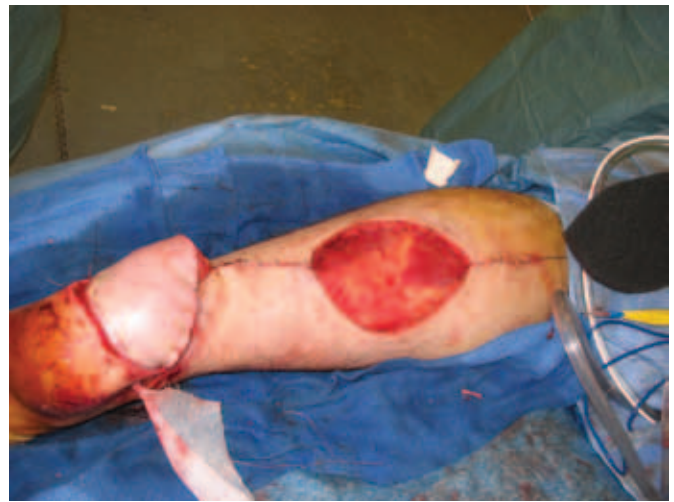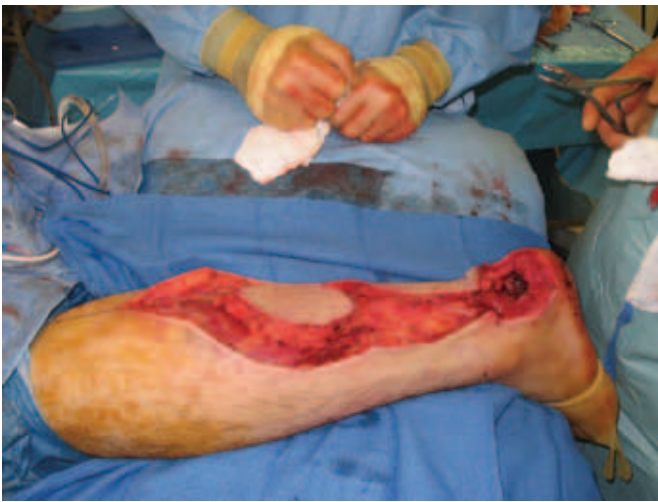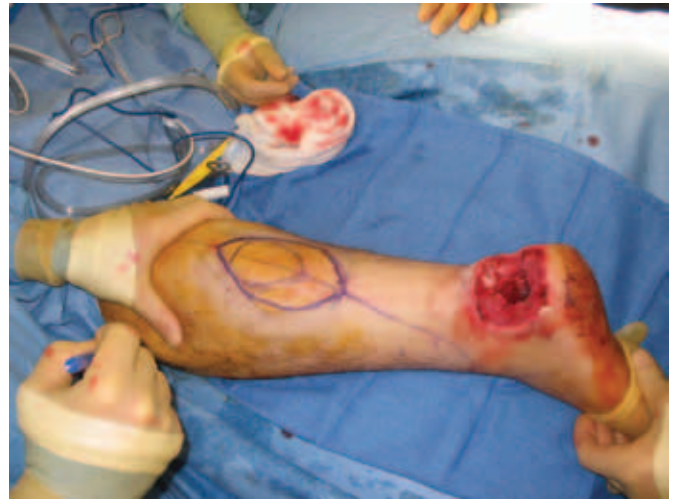Figure 34. *Gastrocnemius muscle flap: (Top) A large anterior leg wound with exposed tibia due to fragmentation injury. (Bottom) The gastrocnemius was exposed, divided, and passed through a subcutaneous tunnel to cover the defect. Images courtesy of the Borden Institute, Office of The Surgeon General, Washington, DC, and Michael Shaun Machen, MD, COL, MC, US Army.*

Figure 35. Sural nerve flap: (Right) Fragmentation injury to the heel of the foot with exposed bone. (Bottom Left) A segment of skin, subcutaneous fat, and fascia are fashioned at the midcalf. (Bottom Right) A flap is rotated and sutured into place. Images coaaurytesy of the Borden Institute, Office of The Surgeon General, Washington, DC, and Michael Shaun Machen, MD, COL, MC, US Army.



Definitive closure of combat wounds can be achieved through delayed primary closure, negative-pressure wound dressings, skin grafting, local or free tissue transfer, or healing by secondary intention.

## Wound Coverage

The timing of wound coverage is complex. As previously noted, war wounds and their management differ significantly from wounds seen in the civilian sector. Early coverage of war wounds is often associated with inadequate wound debridement and increased infection rates, while delayed coverage is also associated with increased nosocomial infection rates.<sup>110</sup> More studies need to be done to define optimal wound coverage practices and minimize complications such as nonunion, flap failure, and infection.<sup>110</sup>

Early coverage of war wounds is often associated with inadequate wound debridement and increased infection rates, while delayed coverage is associated with increased nosocomial infection rates.



# Preventing War Wound Infections

## Wound Debridement and Irrigation

- All war wounds should be considered dirty and contaminated.
- Thorough wound debridement and irrigation are the main defenses against combat wound infection.
- Recent evidence shows that high-pressure pulsatile lavage traumatizes wounds and complicates healing.
- Copious low-pressure irrigation balances the need for contaminant removal with maintaining structural integrity of viable tissues.

## Introduction

Although the sepsis rate in trauma is roughly 0.75 percent, the mortality of such cases is about 4 percent.<sup>113</sup> As such, the prevention of infection is an important imperative in trauma systems.<sup>85</sup> After casualty evacuation from the point-of-injury to a safe area, the CCC provider can evaluate the wound and manually remove or irrigate away gross contamination. Initial wound irrigation is sometimes performed in the prehospital setting before reapplication of a wound dressing.<sup>114</sup> The nonoperative debridement and irrigation of wounds as a bedside procedure can be done in the emergency department. The process typically consists of superficial wound inspection with lavage or irrigation of blood, debris, and loose bone fragments. Irrigation is often done at the first inspection of the wound to limit emergency department dressing changes. The promptness of the initial wound irrigation may have a slight effect on decreasing infection risk, but studies supporting this conclusion are limited.<sup>115</sup> All but the smallest and most superficial of war wounds should undergo such irrigation. Wound infections tend to increase hospital length of stay, cost of care, and complication rates.<sup>107,113,114</sup>

## Wound Flora

The bacteria within a war wound are often thought to contaminate the wound at the time of injury or soon thereafter.<sup>113,114</sup> The natural history of such wound flora is not clearly known, but there are seasonal and geographic variations.<sup>113,114</sup> The flora change over time and this likely occurs as a result of host, injury, treatment, and yet undefined reasons.<sup>113,114</sup> Early wound flora is a mix of gram-positive and gram-negative bacteria including anaerobes.<sup>116</sup> By day five, *Pseudomonas aeruginosa* is commonly noted.<sup>116</sup> Later-stage flora includes gram-negative bacteria such as *Pseudomonas aeruginosa*, *Klebsiella pneumonia*, and *Proteus* spp.<sup>116</sup>

Early in OEF, the extremity infection rate was reported as 3.8 percent (two of 52 casualties) but another report noted 77 percent (27 of 35) of deep cultures of tibia fractures were positive, and five went on to amputation with four associated with ongoing infections.<sup>116,117,118</sup> According to a review by Yun (from 2003 and 2006) there were 2,854 OEF or OIF admissions to Brooke Army Medical Center; 664 (23 percent) patients were admitted to the orthopaedic service with approximately 13 percent developing osteomyelitis. A total of 25 percent of these patients developed recurrent osteomyelitis.<sup>116,119</sup> Gram-negative bacterial pathogens were primarily responsible for the initial infections. Of those who had subsequent recurrent infections, initial gram-negative pathogens were typically eradicated and the subsequent infections were the result of gram-positive infections, primarily staphylococcus species. Murray et al. pointed out that the latter-stage infections were the result of nosocomial infections and were not present at the time of initial injury.<sup>116</sup>

## Wound Irrigation

Wound irrigation and debridement are the most common of all surgical procedures in war hospitals, particularly for limb wounds. The sheer number of these cases taxes the system, surgeons, and perioperative services.<sup>3</sup> The volume of such cases leads to familiarity but also breeds complacency. The skill, diligence, and experience needed to do these procedures optimally are paramount to reducing infections.

### *Timing of Irrigation*

Early irrigation in contaminated wound model experiments has resulted in superior bacterial removal than when delayed irrigation is used.<sup>115</sup> Clinical evidence supports early irrigation within six to eight hours of injury.<sup>116</sup> The optimal time to repeat irrigation is unclear. Given that bacteria counts rebound in wound models within 48 hours, performing serial wound irrigation every two days is a reasonable choice.<sup>113,114,115,116,120,121</sup>

Clinical evidence supports early irrigation of wounds within eight hours of injury.

### *Volume of Irrigation*

Copious initial wound irrigation should be performed to minimize bacterial contamination, which will decrease subsequent wound infection rates.<sup>77</sup> The actual amount of fluid required is debatable, but ideally enough is used so that any gross material is removed and the wound grossly appears clean.<sup>85</sup> Current US military (Joint Trauma Theater System) wound irrigation guidelines recommend nine liters or more of sterile saline be used for large traumatic wounds, six liters or more for moderate-size wounds, and three liters as a minimum for small traumatic wounds.<sup>77,122</sup> These are ideal amounts, and the amount and type of irrigant may be constrained by actual supplies and resources. Recent evidence indicates that the irrigant volume decreases bacterial load in an approximation of a natural logarithmic decay. A point of diminishing returns occurs near nine liters for average-size wounds.<sup>77,121</sup>

### *Irrigants and Additives*

Traditionally, the preferred wound irrigant has been sterile saline or sterile water.<sup>77</sup> Recent studies have demonstrated that potable (drinking) water may also be used.<sup>85,123</sup> Appendix 4 provides the Joint Trauma Theater System (JTTS) Clinical Practice Guidelines (CPG) for Irrigation in War Wounds recommended by the United States Army Central Command. Additives (e.g., antibiotics, surfactants, soaps, or antiseptics) to irrigants have been used with the intent of decreasing local bacterial contamination.<sup>122</sup> Many of these additives are potentially cytotoxic to the cells of the wound.<sup>109</sup> There is no evidence to suggest additives to standard wound irrigants are more beneficial than irrigants without additives. Wound irrigant additive use for war wounds is not recommended.<sup>77,121,122</sup> The optimal irrigant temperature is unclear, but casualty hypothermia should be avoided, so warm irrigants should be chosen as indicated.

There is no evidence to suggest additional benefit to supplementing standard wound irrigation solutions with chemical additives.

### *Irrigation Devices*

High-pressure lavage devices should be avoided because they can cause further tissue injury and push contamination deeper between tissue planes.<sup>77,122</sup> Copious low-pressure irrigation balances the need for contaminant removal while protecting wounded tissues (Appendix 4).<sup>115,120,122,123</sup> Low-pressure pulsatile



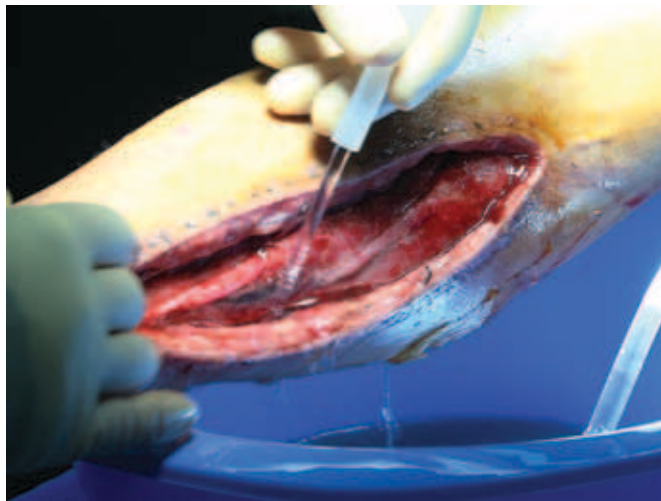


Figure 36. (Top Left) *Copious low-pressure wound irrigation should be performed to minimize bacterial contamination. High-pressure lavage should be avoided.*

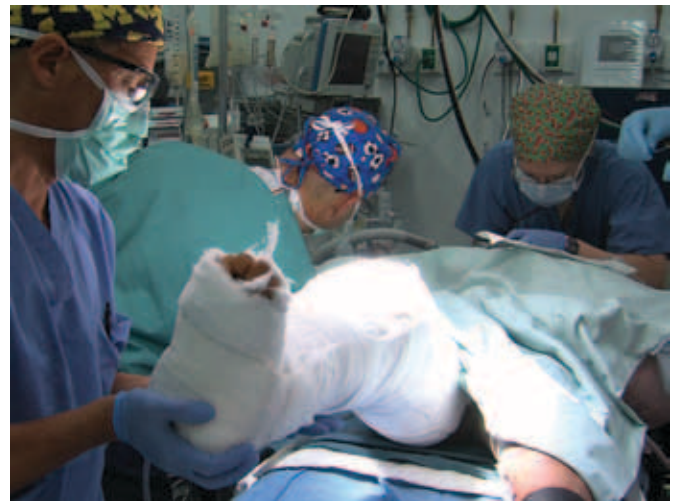

Figure 37. (Top Right) *Initial postoperative dressings of blast injuries should be bulky dry dressings, which will allow absorption of the copious amounts of wound drainage.*



Figure 38. (Bottom Right) *Plaster casts must be bivalved and the cast padding cut down to the skin to prevent excessive pressure on the enclosed limb. Image courtesy of Defense Imagery Management Operations Center (DIMOC).*

lavage, gravity-fed irrigation, and manual bulb-syringe irrigation are currently all techniques successfully used in CCC (Fig. 36).<sup>77,12,</sup>

High-pressure lavage devices should be avoided because they can further tissue injury and drive contaminants deeper between tissue planes.

### Wet-to-Dry Dressing Debridement

Initial postoperative dressings on blast injuries should be dry, bulky dressings, which will be able to absorb the copious amounts of wound drainage seen early in this injury pattern (Fig. 37).<sup>56,77</sup> As the wound begins to drain less, a wet-to-dry debridement dressing change schedule can be started, if superficial debridement is desired. The use of wet-to-dry dressings is a debridement technique in which dry dressings are removed two or three times daily and replaced with damp, sterile ones. As the damp dressing dries, local tissue adheres. When this dressing is removed, it also removes the superficial wound serous drainage and provides a small amount of superficial debridement.<sup>56,77</sup>

Initial postoperative dressings on blast injuries should be bulky dry dressings.

Reevaluation of wounds should occur frequently since wounds evolve with time. Dressing wounds tightly with gauze may prohibit drainage and risk infection.<sup>60</sup> Initial postoperative limb dressings should be made with the injury severity in mind. Severe injuries can swell so much that dry, bulky dressings are needed to permit swelling while absorbing copious serous wound drainage.

When plaster casts are applied for the immobilization of fractures, two lateral longitudinal half-inch segments should be removed from the cast's entire length (bivalving) and the circular dressings cut down to the skin (Fig. 38). This procedure prevents undue pressure on the enclosed limb when swelling occurs.<sup>41</sup> The military air evacuation system in OEF and OIF prohibits casts that are not split (bivalved) in this manner because of the risk of limb swelling during aeromedical transport.<sup>57</sup>

Circumferential plaster casts should be bivalved to prevent excessive pressure on the enclosed limb.

### Surgical Wound Debridement

Following evacuation of the casualty to a facility with surgical capability, early and assertive surgical debridement of grossly contaminated and nonviable tissues is the first step in infection control.<sup>113,114,116</sup> Inadequate wound debridement has been cited as the most common cause of war wound infection.<sup>116</sup> War wound surgery involves careful exploration of all wounds (i.e., closed wounds, entry and exit wounds, missile tracks between entry and exit, and secondary missile tracks caused by fragmentation of the munitions after entering the body).<sup>60</sup>

Inadequate wound debridement has been cited as the most common cause of war wound infection. Fasciotomy is often integral to debridement.

A systematic approach to wound evaluation will help the surgeon avoid missing areas of a large wound. This involves: (1) starting by exploring the most superficial wound first; (2) debriding the skin and subcutaneous tissue; (3) then debriding muscle and fascia; (4) fasciotomy and hematoma removal; and (5) finishing deep wound debridement of periosteum and bone. Fasciotomy is often integral to debridement. Debridement's core meaning includes unbridling the wound, which includes removal of expanding hematomas and relieving compartment pressure. Diligent wound exploration is required to avoid iatrogenic injury to the traversing vessels and nerves within the wound. In the authors' experience a geographic approach to wound evaluation, dividing it into quadrants and addressing all pathology in each quadrant before moving to the next one, has been successful.

The broad spectrum of foreign matter found within war wounds is remarkable. Over time, CCC providers will document everything from blast injury victim bone fragments to palm dates and even insects within war wounds (Table 4). Of note, the anatomic location of a foreign body does not indicate what path it took to get there. For example, a casualty in OIF with a traumatic amputation above the left knee was found to have a large foreign body in his right chest on radiography (Fig. 39). The foreign body was initially thought to be something on the cassette he was lying upon, until a repeat chest radiograph reconfirmed its presence. An 18 x 2 x ¼ inch explosion-related fragment had entered his right lung via his abdomen from his knee wound. The missile track was confirmed surgically. It traversed the bladder, rectum, kidney, intestines, liver, diaphragm, and lung. Missile tracks following blast injuries are notoriously difficult to precisely and reliably identify.

## FOREIGN MATTER IDENTIFIED DURING DEBRIDEMENT

- Dirt, soil, mud, sand, rocks, road debris, dust, and compost
- Bullets, shrapnel, ordnance fragments, uniform bits, clothing, and equipment
- Other casualty items blasted into the wound, bones, clothing, boots, kit, and gear
- Animal matter such as insects, worms, carcass fragments, excrement, and leather
- Plant matter such as wood, grass, leaves, roots, and nuts
- Manmade items: glass, car or building parts, concrete, pipes, nails, batteries, nuts, bolts, screws, and metal can parts
- Water, sewage, water plants, and frog fragments
- Chemical matter, phosphorous, acids, liquids, and smoked or charred items

Table 4. *Foreign matter identified in explosion-related wounds.*

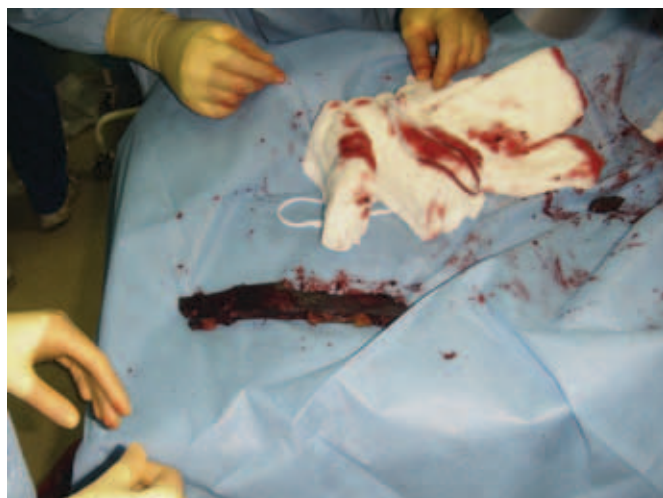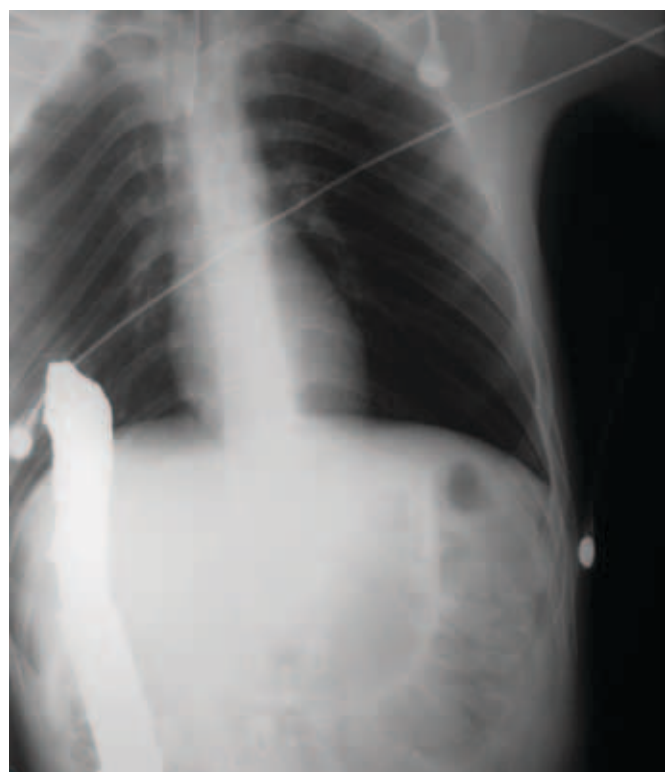

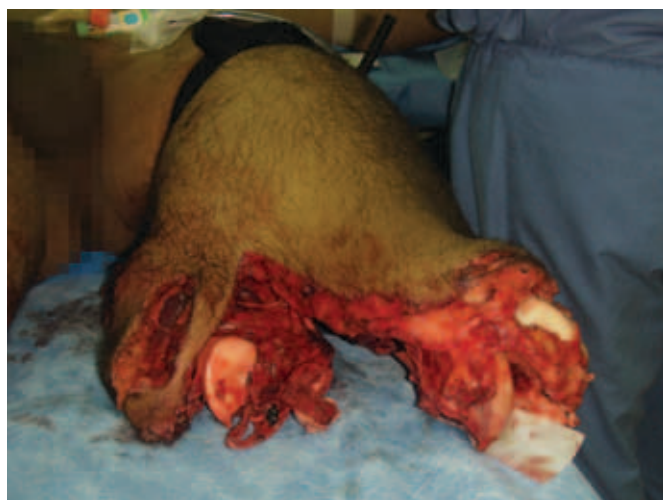
Figure 39. *Missile tracks following blast injuries are difficult to identify: (Top Left) Combat casualty with a traumatic amputation above the left knee. (Top Right) Foreign body noted on chest radiograph. (Bottom Left) Explosion-related fragment that had entered the chest cavity via the casualty's abdomen from the knee wound. Images courtesy of John B. Holcomb, MD, COL(Ret.), MC, US Army.*



Missile tracks following blast injuries are difficult to reliably identify. Large missile fragments in soft-tissue wounds are often removed, whereas small fragments are only removed if they are readily accessible.

Sharp surgical debridement of devitalized and grossly contaminated tissues is the primary surgical means of infection prevention.<sup>114,124</sup> However, the innate meaning of devitalized (that which is less than fully vital) is operationally problematic, as devitalized tissues range from bruised or edematous to blackened eschar. Muscle rigor, a feature of rigor mortis, is rarely seen in the living casualty.<sup>36,125</sup> Analyzing how effectively surgeons classify viable versus nonviable tissue during debridement efforts is rarely researched. Ensuring CCC providers new to war are adequately trained in this process is critical.<sup>60,126</sup>

Generous surgical extension of the wound in order to see the damaged tissues adequately (around the wound recesses) is important. This process enables complete inspection and removal of devitalized tissues and foreign material that may have traveled along or through fascial planes.<sup>60</sup> Such extension of traumatic wounds often includes longitudinal skin incisions and compartmental fasciotomy. Fascia is generously released.<sup>54</sup> Judicious excision of skin margins, often just a millimeter or two, will remove devitalized or grossly contaminated edges while maintaining as much cover as practical (Fig. 40). Grossly contaminated skin edges are often identified following irrigation and removal of dried blood. The skin edges' white fibrous strands are often covered with dark particulate debris such as sand. Contaminants tightly adhere to these fibers, which can be a millimeter or longer. These contaminated and difficult to clean fibrous strands are useless and risk infection.

There is little beyond expert opinion on which to base tissue fragment management recommendations.<sup>127</sup> Large missile fragments (shrapnel) in soft-tissue wounds are typically removed, whereas small fragments are removed only if they are easily accessible.<sup>60</sup> If iatrogenic trauma would result from the removal of smaller fragments, they are allowed to remain in place.<sup>60</sup> Shrapnel is a term used classically for fragments from preformed antipersonnel munitions, but is now commonly used by lay people to indicate metal fragments from explosive shells.

When wound tracks from entry-to-exit are long relative to their width, debris such as bone fragments and blood clots can be debrided without fully opening the wound. This can be accomplished by passing

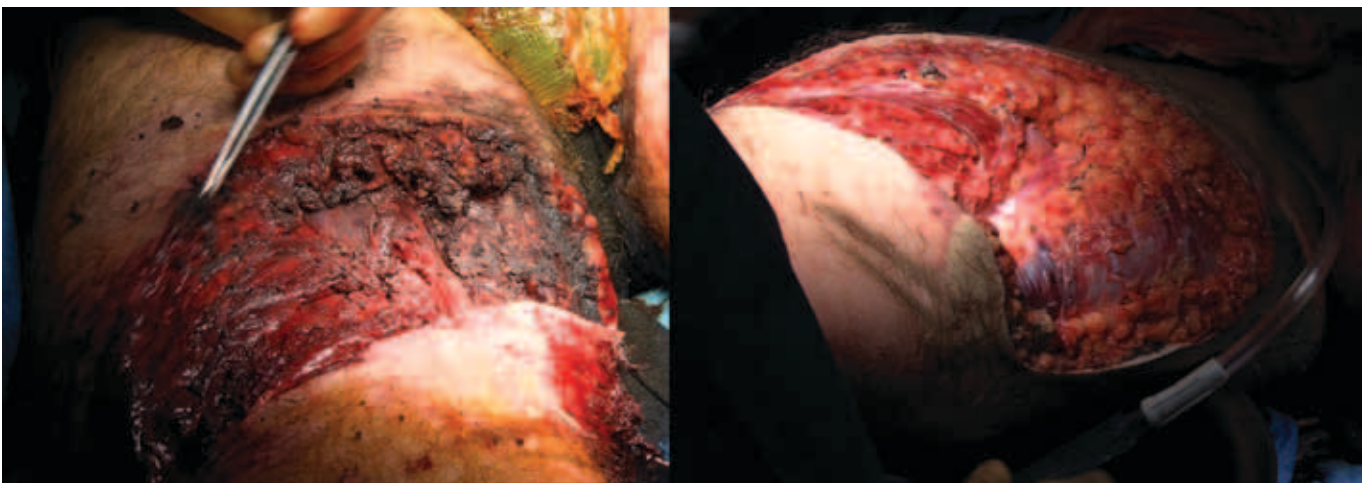


Figure 40. *Early and assertive surgical debridement of nonviable tissue is a critical step in infection control.*



a small but long surgical sponge across the track, often by a clamp, such that the wound floss can help pull the debris out the dependent opening. Similarly, the dependent opening can be used for drainage, and if the opening is not large enough for adequate drainage, then it can be enlarged. If the track is blind in that it has no exit, and the entry is not dependent, then a counterincision can be made in a dependent area. The dependent drainage by gravity is usually for the casualty in the supine position, and can simplify care while decreasing complications.

Wound drains are routinely placed by surgeons in war wounds with the intent of decreasing infection rates. While data are limited, existing studies suggest that open surgical drains are associated with more complications (e.g., infections) as compared to no drains or closed drains.<sup>128</sup> A Cochrane review of closed drains following orthopaedic surgery in a civilian patient population concluded there is insufficient evidence to support the routine use of closed suction drainage following orthopaedic surgery.<sup>129</sup> Further studies are required to better define the role of surgical drains for war wounds.

### ***Assessing Muscle Viability***

The most challenging and problematic tissue to debride in wounded limbs is skeletal muscle. Muscle, in particular, can be judged as living or dead roughly based on the four C's of muscle viability. These include (1) color (red versus pale or brown); (2) consistency (not waxy or stewed); (3) contractility (on being pinched with the tips of a forceps); and (4) capacity to bleed (capillary bleeding when cut).<sup>126</sup> Tissue discoloration or staining from surface hemorrhage on wound surfaces or small hemorrhages within tissue such as skeletal muscle should be differentiated from large hematomas, contamination, and tissue ischemia. Color is not as reliable as the other C's. Dead muscles can bleed from larger blood vessels within the skeletal muscle itself, so this capacity to bleed should be differentiated from the capacity to bleed from capillaries.<sup>14</sup> The former is a false positive indicator of viable tissue, while the latter is a true indicator of tissue viability. Muscle injury, particularly when large and associated with ischemia, can be associated with coagulopathy. Hence, careproviders must be aware that slow, venous oozing from cut muscle may also be a false positive indicator of tissue viability. Medications such as aspirin, nonsteroidal antiinflammatory drugs, and anticoagulants may accentuate such bleeding in casualties.<sup>130</sup>

Muscle viability can be assessed based on the four C's: color, consistency, contractility, and capacity to bleed.

### ***Massive Wounds (Upper Thigh and Buttock)***

Massive wounds of the upper thigh and buttock are problematic in two aspects; control of hemorrhage and determination of the amount of muscle to be excised (Fig. 41).<sup>36</sup> The wound may be too proximal for a tourniquet. Oozing may persist and may be associated with coagulopathy in need of correction.<sup>35,131</sup> Placement of an emergency tourniquet as proximal as possible, while still partially covering the wound, can be temporarily effective in hemorrhage control. However, this approach risks failing to extinguish the arterial pulse and may lead to complications (e.g., expanding hematomas and compartment syndrome).<sup>36</sup> Surgical preparation with the tourniquets in place, within the operative field, can maintain hemorrhage control and allow more time for surgical team preparation.<sup>15,36,65,66,67</sup> In large wounds of the buttock and upper thigh, repeat wound inspection on the second or third postoperative day are indicated. These repeat inspections during staged debridements and irrigations can ensure any remaining devitalized tissue is recognized sooner for further debridement.<sup>56</sup>

In large, complex wounds it is difficult to determine the amount of muscle to excise. Residual devitalized tissue in wounds risk infection. With high-energy mechanisms, damage along fascial planes and between muscle bundles occurs, which may further devitalize deep muscle as some muscle perfusion comes from adjacent planes. Surgeons digitally probing for debris or hematomas should be aware that the technique of using their fingers to circumferentially dissect around small muscles can damage vasculature structures. Muscles like the sartorius in the thigh can be inadvertently stripped of their segmental blood supply through circumferential digital dissection, resulting in muscle necrosis and infection. The intramuscular vascular patterns of muscles are poorly known.<sup>132</sup> After sharp debridement, copious low-pressure wound irrigation can be used to remove loose debris, missile fragments, and decrease wound surface bacterial contamination (Appendix 4).<sup>115,121,122,123</sup>

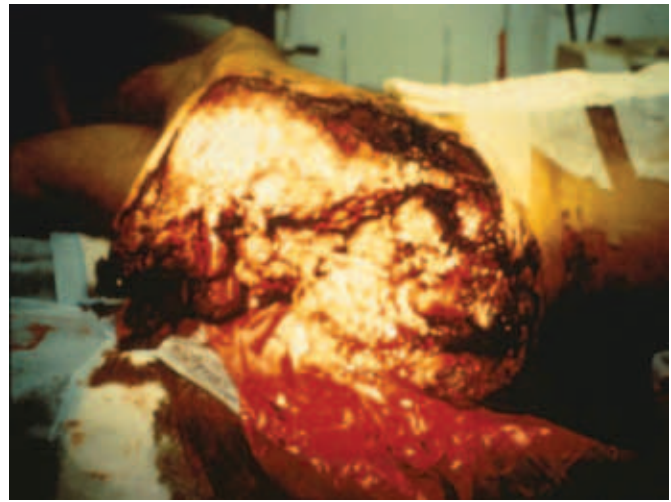

Figure 41. Hemorrhage from massive wounds of the upper thigh and buttock may be difficult to control, and determining the amount of muscle to debride is often difficult. Images courtesy of John B. Holcomb, MD, COL (Ret.), MC, US Army.

### **Negative-Pressure Wound Dressings**

- Negative-pressure wound dressings are commonly used in OEF and OIF.
- Appropriately applied and managed negative-pressure wound dressings result in improved wound healing rates.
- Placement of a negative-pressure dressing should occur only after thorough debridement of devitalized and contaminated tissues.
- A wound vacuum device is available and approved for aeromedical transport use in OEF and OIF.

Negative-pressure wound dressings have been used successfully in the treatment of war injuries.<sup>133,134</sup> The negative-pressure dressing provides a closed environment for the wound and resorbs the large amounts of serous fluids that drain from blast injuries.<sup>135</sup> This closed system may reduce hospital-acquired infections because these wounds are less prone to repeated inspection and manipulation.

Negative-pressure wound dressings are commonly used in OEF and OIF.

Inappropriate use of negative-pressure wound dressings has been associated with infectious complications. Placement of a negative-pressure dressing should occur only after thorough debridement of devitalized and contaminated tissues.<sup>56,133</sup> Use of the negative-pressure dressing overlying dead tissues can create a closed space. This closed space creates an ideal environment for abscess formation, which would lead to local and potential systemic infectious complications.<sup>56</sup> This closed wound environment provides the ideal media for bacterial growth if the vacuum device fails, or is left in place too long between debridements.<sup>136</sup> Loss of vacuum suction or tube blockage can have similar outcomes as device failure.<sup>134</sup> If suction is lost, the tube or dressing can be cut to allow drainage or the negative-pressure dressing can be replaced by dry

bulky dressings. As previously mentioned, based on anecdotal reports by war surgeons, negative-pressure wound therapy appears best avoided at the initial surgery for wounds at risk for rebleeding. Negative-pressure wound dressings can be considered after the casualty and wounds are stable without bleeding for 48 hours (following initial resuscitation).

Placement of a negative-pressure dressing should occur only after thorough debridement of devitalized and contaminated tissues. Negative-pressure dressings should be avoided in wounds at risk for rebleeding.

Negative-pressure wound therapy can facilitate the delayed closure of large traumatic wounds. It does so by decreasing the size of the wound over time. The device applies tension to the skin and removes third-space fluids. The device can be an adjunct in split-thickness skin grafting. During OEF and OIF, a wound vacuum device (The V.A.C. Freedom® Therapy System, Kinetic Concepts, Inc. or KCI, San Antonio, TX) was approved for aeromedical transport in OEF and OIF. The wound vacuum assisted closure or V.A.C., is a proprietary label for KCI's negative-pressure wound therapy system, a common one used currently in the US military. Devices have to be approved by the military for safe aircraft use prior to implementation during aeromedical transportation in casualty care.

### ***Antibiotic Impregnated Pellets and Cement Bead Therapy***

An adjunctive measure that can be used with or without the negative-pressure dressings is antibiotic-impregnated beads (Fig. 42). Such beads are usually made of polymethylmethacrylate, a type of bone cement, with a heat stable antibiotic additive such as tobramycin. The polymerization of the polymethylmethacrylate powder with the liquid catalyst is exothermic in forming the cement, so the antibiotic powder needs to be heat stable, or it will be inactivated in bead formation. Antibiotic bead pouch use reduces bacterial growth in an anaerobic environment.<sup>116</sup> Antibiotic beads may offer some benefit in the prevention of infection at the local site, but no data exists on their efficacy in war wounds or long-term effect on wound infection.<sup>116</sup>

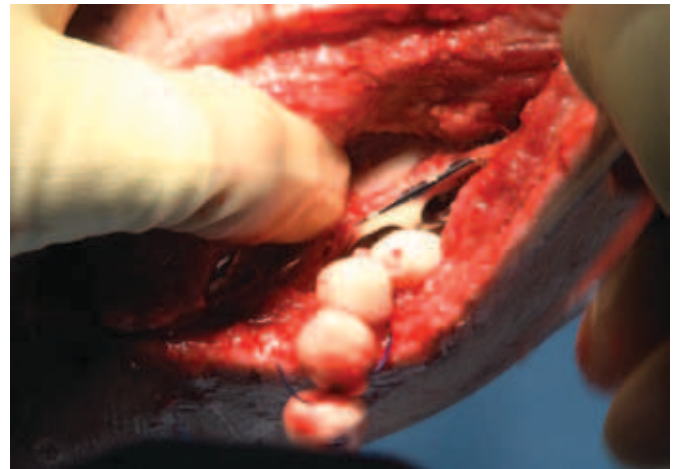


Figure 42. *Antibiotic beads may offer some benefit in the prevention of local infection, but definitive data are lacking on their efficacy in war wounds.*

Preparation of antibiotic bead pouches consumes valuable time and operative resources; ideally these should be prepared ahead of time.<sup>116</sup> Effective local antibiotic delivery can be obtained with both commercially available calcium sulfate pellets and with handmade polymethylmethacrylate beads.<sup>137</sup> Tobramycin-impregnated calcium sulfate pellets have been shown to effectively prevent infection in a contaminated wound model.<sup>138</sup>

### ***Antibiotics and Tetanus Immunization***

- Systemic antibiotic administration should occur within three hours of sustaining combat wounds.
- Antibiotic guidelines for routine combat wounds should be followed.

- Ensuring up-to-date tetanus immunization status following combat wounds is important to eliminating tetanus infections.
- The main risk for developing wound infection in casualties is the severity of the injury.

## Prophylaxis

Prevention of infection in war wounds is an important goal.<sup>139</sup> Injury severity and wound management practices are important determinants of subsequent infection.<sup>128</sup> The benefits and risks of current antibiotic wound prophylaxis practices to prevent infections in combat casualties have yet to be fully defined.<sup>85,140</sup> Early wound cleansing and surgical debridement, antibiotics, bony stabilization, and maintenance of infection control measures are essential to diminish or prevent infections.<sup>85</sup> Antibiotic prophylaxis or therapy is an adjunct to adequate surgical debridement of war wounds.<sup>116</sup> Prophylactic antibiotics have been associated with high rates of drug-resistant organisms.<sup>116</sup>

Initial care of combat wounds occurs at the point-of-injury, where a sterile bandage may be applied and oral antibiotic administered as prophylaxis.<sup>139</sup> Prophylactic antibiotics in tactical CCC settings have been recommended for all open wounds. If the evacuation time of the casualty is expected to be more than three hours, the use of oral antibiotics is recommended within three hours of injury.<sup>85</sup> Recommendations for initial antibiotic prophylaxis in OEF and OIF for open extremity wounds with oral antibiotics are moxifloxacin (400 milligrams orally, one single dose in the field) or as an alternative levofloxacin (500 milligrams orally, one single dose in the field), but empiric evidence is scant regarding effectiveness or outcomes.<sup>85</sup>

Prophylactic antibiotics in tactical CCC settings have been recommended for all open wounds and should be administered within three hours of sustaining combat wounds.

Antibiotic recommendations for OEF and OIF casualties with open fractures arriving at a treatment facility that possesses intravenous antibiotic supplies are one gram of cefazolin (also known as cephazolin) intravenously every eight hours for 72 hours. An alternative to cefazolin is clindamycin (900 milligrams intravenously every eight hours for 72 hours). The clindamycin dosing used in war wounds differs from 450 milligrams every six hours civilian sector dosing. Clinical evidence supporting this practice is limited. Subsequent use of antibiotics (beyond 72 hours) should be reserved for treatment of documented infections, as opposed to prophylaxis, in order to limit the selection of multidrug-resistant organisms. In patients who present more than 72 hours after injury, or are injured with antipersonnel land mines (implying soil contamination), metronidazole should be added as well to the treatment for 48 hours intravenously and then orally until delayed primary wound closure is complete.<sup>85</sup> Evidence is scant regarding effectiveness or outcomes of aforementioned recommendations.

Wounds should only be cultured routinely when an infection is suspected. Antibiotic selection is ideally based on results of wound cultures and bacterial antibiotic sensitivities. Recent hospital and regional bacterial flora should influence antibiotic selection. Temporal and geographic variations occur with the organisms isolated from combat wounds.<sup>113,114</sup> Longstanding systematic tetanus immunization programs for US military personnel have largely prevented tetanus infections.<sup>113</sup> New cases of tetanus in military personnel are rarely seen today.<sup>113,114</sup> If a combat casualty (e.g., host national) has not received a primary immunization series against tetanus infection, primary tetanus immunization and passive prophylaxis (tetanus immune globulin) should be administered.<sup>85</sup>



All penetrating combat wounds should be considered tetanus-prone, and patients should be provided a tetanus toxoid booster immunization if more than five years have passed since their most recent tetanus immunization.

## Fracture Management

- Fractures stabilization decreases pain, eases wound care, and improves soft-tissue and vascular repair outcomes.
- Initial fracture stabilization is performed in a damage control manner in war and is not definitive.
- Most hand and foot fractures can be adequately stabilized for transport with simple splints applied over dressings.
- External fixators can loosen with patient transport; so the clamps should be periodically retightened (e.g., 24 to 48 hours) after application.

### Introduction

Extremity trauma with bony fractures is a common war injury.<sup>60</sup> About 26 percent of casualties with

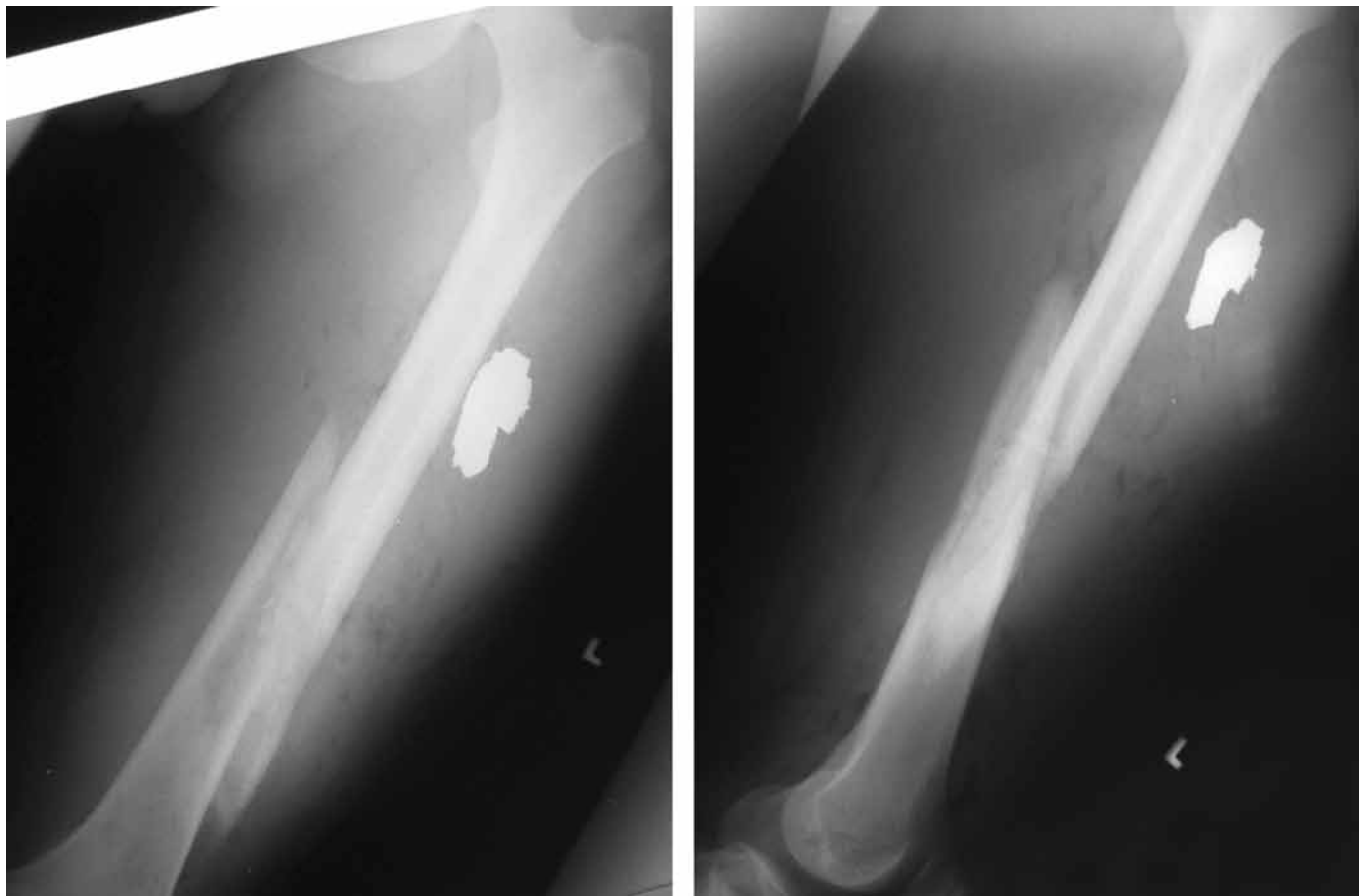

Figure 43. Radiographic evaluation of the traumatized limb should (at a minimum) include biplanar radiographs to fully delineate the bony injury. Here, (Left) PA and (Right) lateral radiographs demonstrate a midfemoral fracture and the metallic fragment that caused the injury. Images courtesy of the Borden Institute, Office of The Surgeon General, Washington, DC.

extremity wounds in OIF have a fracture. The majority of these injuries (82 percent) are open fractures where the soft-tissue envelope around the fracture has been physically disrupted, and the bone has been exposed to the external environment.<sup>2,4</sup> Inexperienced providers can underestimate wounds by thinking that a skin wound does not communicate with a nearby fracture when it actually does, so a high index of suspicion should persist pending orthopaedic evaluation.

Eighty-two percent of extremity fractures in OIF are open fractures.

Radiographic evaluation of the traumatized limb should (at a minimum) include biplanar radiographs to fully delineate the bony injury (Fig. 43). Stabilization of these fractures has several benefits, including patient comfort, protection of the surrounding soft-tissues, protection of vascular repairs, and improved wound care.<sup>116</sup> The goals of fracture management in the combat setting are to prevent infection, preserve options for limb reconstruction or limb salvage, and prevent further tissue injury and hemorrhage during patient treatment and transport.<sup>57</sup> Simple, early management of fractures can avoid long-term complications such as osteomyelitis and nonunion.

Goals of fracture management in the combat setting are to prevent infection, preserve options for limb reconstruction or limb salvage, and prevent further tissue injury and hemorrhage during patient treatment and transport.

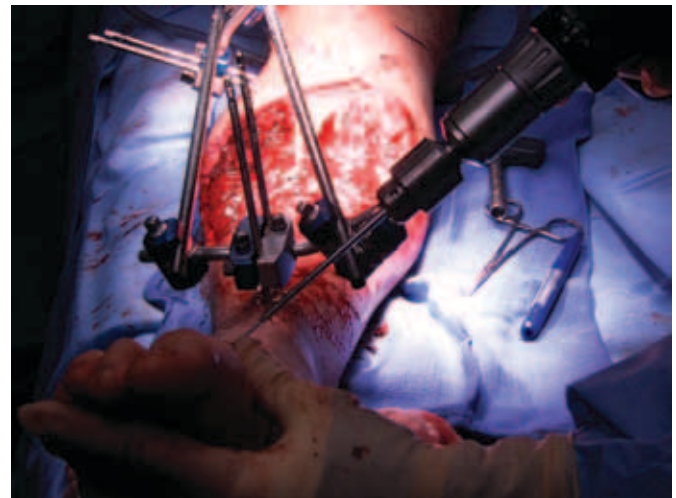
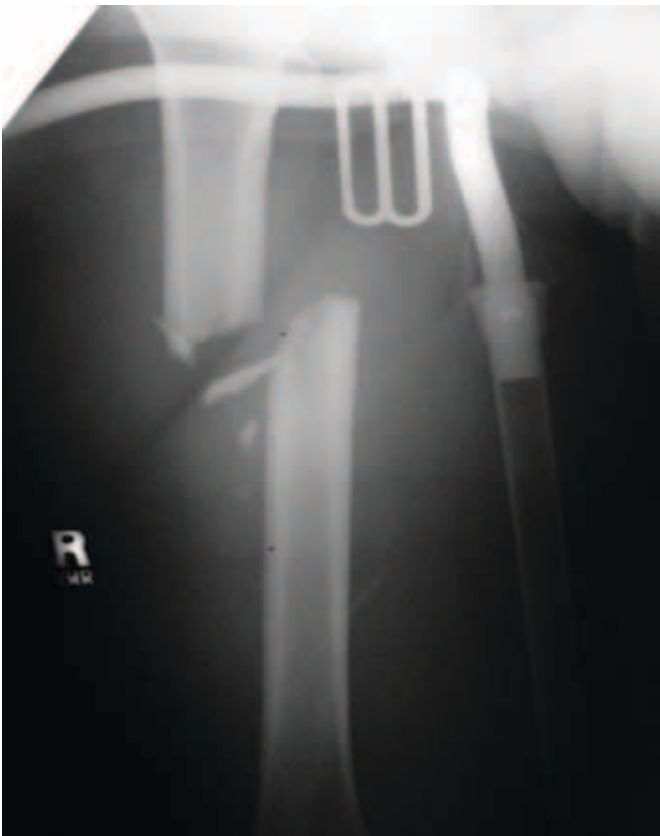

Figure 44. (Left) *Limb deformity due to displaced fractures can compromise the vascular supply to the distal limb. If compromised perfusion is detected, immediate longitudinal traction should be applied.*

Figure 45. (Above) *When possible, fixation devices should be placed in a location that avoids traversing the traumatic wound or hematoma itself.*

## ***Initial Fracture Wound Management***

Initial limb deformity due to displaced fractures can compromise the vascular supply to the distal limb (Fig. 44). The CCC provider should respond to the limb with compromised perfusion and displaced fracture with longitudinal limb traction, which will grossly realign the limb at its proper length, thereby reducing the fracture shortening and typically improving distal perfusion. The fracture reduction can be maintained with manual traction if necessary; or if supplies and time allow, temporary plaster splints can be applied to hold the limb out-to-length.

In this type of unstable skeletal injury, the distal pulses should be checked frequently and more definitive fracture fixation should be sought. If fracture reduction is successfully performed and the vascular supply to the distal extremity remains compromised, an arterial injury should be assumed until proven otherwise. Careproviders are advised to immediately transfer such cases to an echelon of care capable of providing vascular repair (typically a Level III facility). Periarticular fracture reduction is also important for limb perfusion, length, soft-tissue balance, joint surface reduction, and follow-on care.

If vascular supply distal to a skeletal injury remains compromised following successful fracture reduction, arterial injury should be assumed present and the casualty transferred to a Level III facility for further evaluation.

## ***Initial Fracture Stabilization***

Initial fracture stabilization should be viewed as part of limb resuscitation and not definitive fixation.<sup>141</sup> Care should be taken to first do no further harm by ensuring the placement of fixation devices is away from nerves and vessels. When possible, to minimize risk of infection, fixation devices should be placed in a location that avoids traversing the traumatic wound or hematoma itself (Fig. 45). Half-pin frame external fixators, K-wires (Kirschner wires), splints, and skeletal traction can all be used for fracture stabilization.<sup>142</sup> Skeletal traction is fast but limited to patients not needing further evacuation because traction must be removed for transport. External splints allow for noninvasive fracture stabilization and provide a cradle for the injured soft-tissue envelope (Fig. 46). The disadvantage of splinting is the potential for loss of fracture reduction with motion in the splint and the inability to easily inspect the wounds underlying the splint unless it is removed.

Initial fracture stabilization should be viewed as part of damage control limb resuscitation and not as definitive fixation.

External fixators and K-wires provide skeletal fixation and are indicated for long-bone and periarticular fractures in which stability cannot be achieved by splinting.<sup>77</sup> Commonly, the fixator will be applied concurrently with a vascular procedure to provide a stable limb and protect the site of vascular repair or shunting (Fig. 47). Segmental metacarpal and metatarsal fractures with bony loss can be spanned longitudinally with K-wires to reduce soft-tissue contractures during transport. Such wires can be straight or have 90-degree bends to block the fractures' ends out at their reduced positions for optimal soft-tissue lengths (Fig. 48). There is no single, ideal form of resuscitation fixation, but the options used should first do no further harm and, second, provide a stable extremity for transport out of the theater of operations.<sup>77</sup>

Figure 46. (Right) *External splints allow for noninvasive fracture stabilization. In this combat casualty, additional surgery was deferred until the patient was stable. Image courtesy of the Borden Institute, Office of The Surgeon General, Washington, DC.*

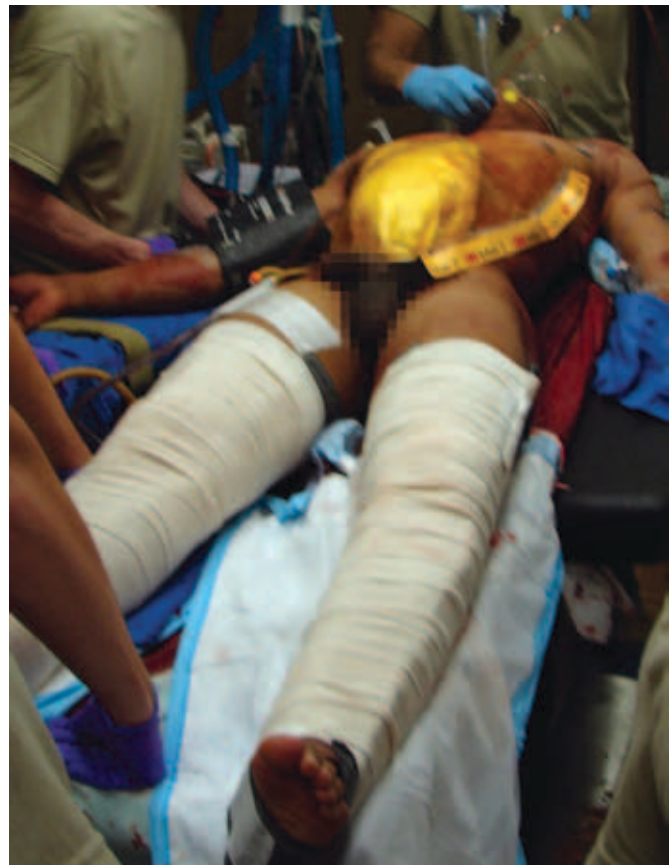
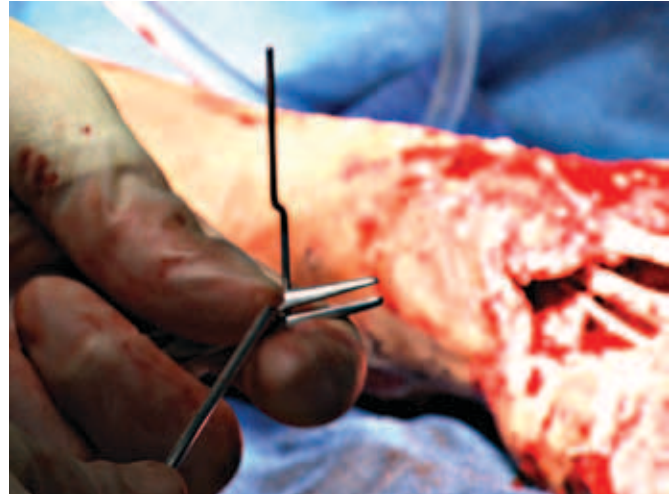
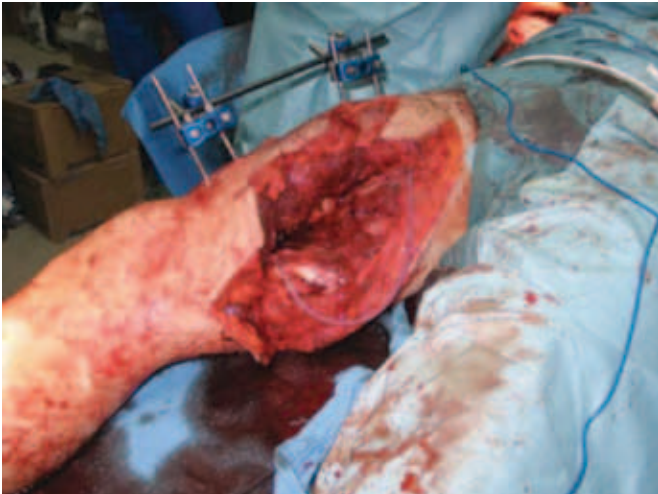Figure 47. (Bottom Left) *This open femur fracture was rapidly stabilized with external fixation while a shunt of the superficial femoral artery was placed. The external fixator provided added protection to the site of vascular shunting.*

Figure 48. (Bottom Right) *Segmental metacarpal and metatarsal fractures with bony loss can be spanned longitudinally with K-wires to reduce soft-tissue contractures. The K-wire is bent four times (90-degree corners) so when the ends are inserted in the bone marrow, the corners hold the soft-tissues out the length of the bone depth.*



External fixators and K-wires provide skeletal fixation. They are indicated for long-bone and periarticular fractures in which stability cannot be achieved by splinting.

### ***Open Fracture Management***

The approach to an open fracture should proceed with similar tenets as for other contaminated wounds. Initial open fracture wound irrigation can be performed as part of the wound inspection in the emergency department. This initial inspection and irrigation should not be considered definitive treatment. Copious



intraoperative wound irrigation and sharp surgical debridement are indicated with adjunctive, broad-spectrum, intravenous antibiotic prophylaxis (Fig. 49).<sup>77,116</sup> Nonviable tissues, including bone fragments stripped of their soft-tissues, should be removed (Fig. 50). An exception to this removal may include retention of large articular bony fragments regardless of soft-tissue attachments as long as they are not grossly contaminated and appear suitable for articular reconstruction.<sup>77</sup>

Internal fixation of fractures should be delayed until the patient has been resuscitated and the soft-tissue injury has been treated.<sup>77</sup> With rapid aeromedical evacuation of combat casualties to Level IV and V facilities, there are no compelling indications for internal fracture fixation of US and coalition forces in-theater during OEF and OIF. Internal fixation of host nation patients after a clean wound bed has been obtained has been performed in OEF and OIF.<sup>77</sup> Certain fracture types (e.g., displaced femoral neck and talus fractures) have, in the past, been considered a dilemma for CCC providers, as delay in fracture reduction was believed to increase risk of avascular necrosis. Recent studies have shown no difference in results, and therefore the increased risk, and often increased reduction difficulty, favor early evacuation and fixation out-of-theater.

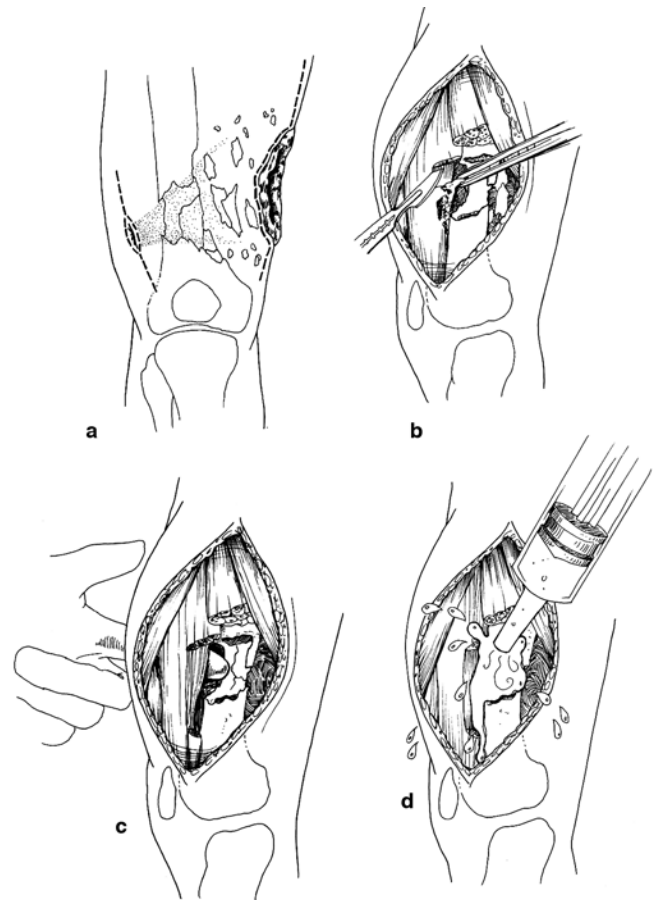


Figure 49. The approach to an open fracture should proceed with similar tenets as for other contaminated wounds. Copious intraoperative wound irrigation and sharp surgical debridement are indicated with adjunctive broad-spectrum intravenous antibiotic prophylaxis. Image courtesy of the Borden Institute, Office of The Surgeon General, Washington, DC. Illustrator: Jessica Shull.

With rapid aeromedical evacuation of combat casualties to Level IV and V facilities, there are no compelling indications for internal fracture fixation of US and coalition forces in-theater during OEF and OIF.

Most of the initially placed frames will eventually be removed or modified to allow for definitive fracture fixation.<sup>143,144</sup> Bony stabilization of the extremities is indicated to hold alignment of the long bones to prevent laceration of soft-tissue structures by the fracture surfaces, prevent injury to vascular shunts or grafts, and provide comfort to patients during transport. External splinting may be appropriate for more distal fractures. Such fractures are closed, low-energy, and stable fractures. External splinting can also serve as an adjunct to external fixation (e.g., a posterior leg splint to keep the foot out of equinus with a half-pin frame on a tibia fracture). If a circumferential cast is used, it and the cast padding must be bivalved prior to aeromedical evacuation.

### **External Fixation of Extremity Fractures**

External fixation is invasive and is generally reserved for long-bone and periarticular fractures not amenable to splinting. External fixation preserves access to the wound and soft-tissues for serial evaluation

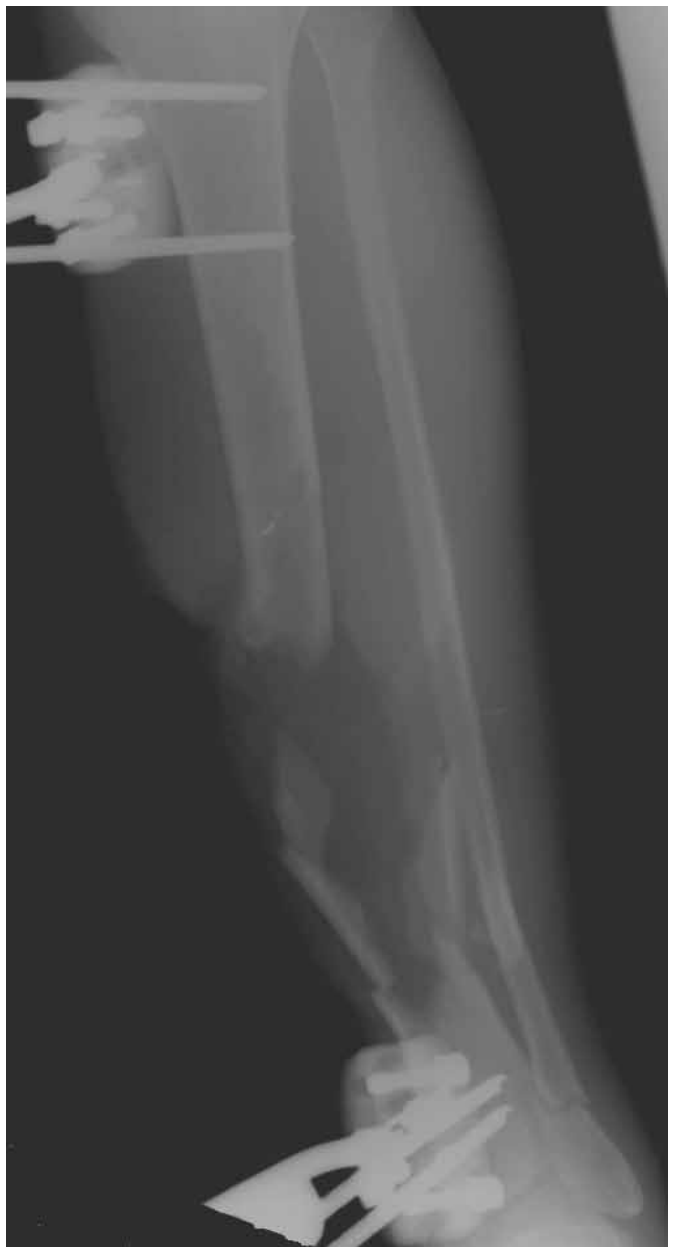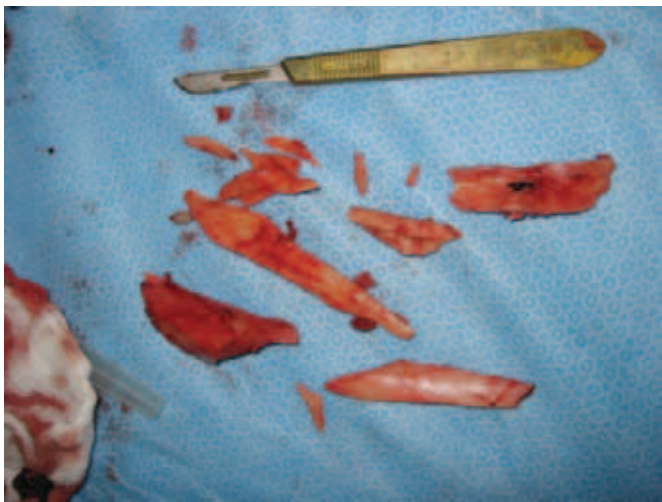

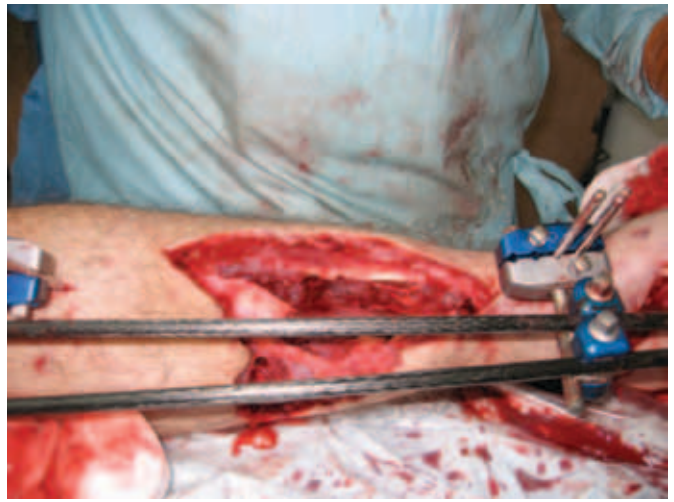
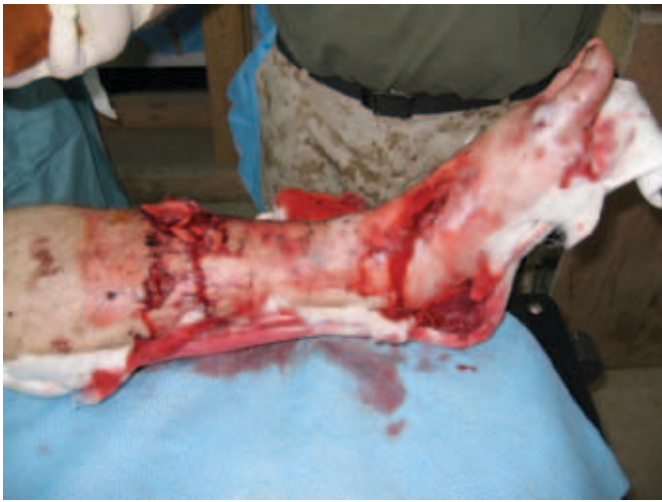Figure 50. *Open fracture management: (Top Left) Casualty with open tibial and fibular fractures at presentation. (Top Right) Appearance of wound following irrigation, sharp surgical debridement, removal of nonviable tissue, and external fixation. (Bottom Left) Bone fragments stripped of their soft-tissues. (Bottom Right) Radiographic appearance of the injured limb following external fixation.*

and debridement while providing rigid skeletal fixation, and it may save time during damage control interventions.<sup>109</sup> Disadvantages of external fixation are the potential for iatrogenic vessel or nerve injury, pin site infections, lack of soft-tissue support, and possibly fewer surgical options if pin complications occur.<sup>77,145</sup> General surgeons should be familiar with the standard constructs of external fixation for use in initial care of battle casualties and have a thorough understanding of limb anatomy to ensure safe pin placement.<sup>57</sup> External fixation constructs may be applied without fluoroscopy and without the need for power tools.

General surgeons should be familiar with the standard constructs of external fixation for use in initial care of battle casualties and have a thorough understanding of limb anatomy to ensure safe pin placement.

For effective external fixation, a minimal number of pins should be used to provide skeletal stability during resuscitation. This stabilization is commonly performed with two half-pins on both proximal and distal sides of the fracture (Fig. 51). Other factors that can make the external fixator frames more rigid are bony cortical contact of the reduced fracture edges, larger diameter half-pins, pin pairs spread farther apart (each pair on either side of the fracture), number of bars used in the frame, use of bars in multiple planes in the frame, and lessening the distance from the bone to the closest bar.<sup>142</sup>

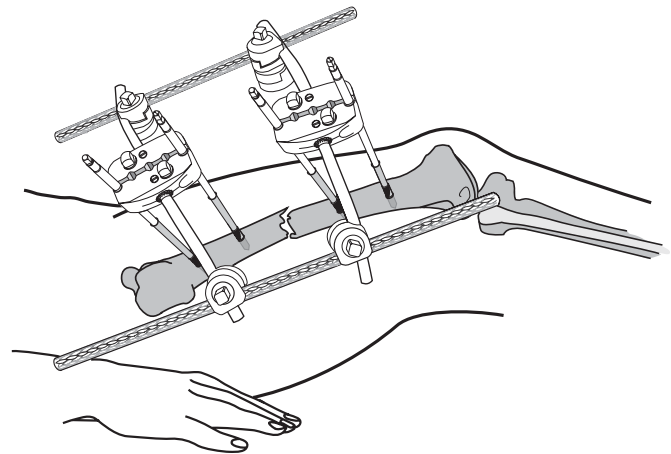


Figure 51. *Stabilization with external fixation is commonly performed with two half-pins on both proximal and distal sides of the fracture. Image courtesy of the Borden Institute, Office of The Surgeon General, Washington, DC. Illustrator: Bruce Maston.*

Basic principles of external fixation dictate that the half-pins used should be bicortical (as opposed to unicortical) with avoidance of all neurovascular structures, joints, open wounds, fractures, and fracture hematoma.<sup>142,145</sup> As with any fracture work, care must be paid to the surrounding neurovascular structures before, during, and after provisional fracture reduction.

Principles of external fixation dictate that half-pins should be bicortical (as opposed to unicortical) and should avoid all neurovascular structures, joints, open wounds, fractures, and fracture hematomas.

External fixation of a distal femur fragment at distal Hunter's canal involves placing the half-pin tip in close proximity to neurovascular structures. Care must be exercised to avoid inadvertent injury to the superficial femoral artery as it courses through Hunter's canal.<sup>145</sup> Distal pulses should be reevaluated if limb manipulation is performed and after external fixation pins are placed. Clinical examination of peripheral nerves is important because external fixation pins can injure nerves.<sup>145</sup> An excellent atlas for review of safe tissue intervals for placement of external fixation half-pins is the Atlas for the Insertion of Transosseous Wires and Half-Pins: Ilizarov Method.<sup>142</sup>

### Upper Extremity Fracture Fixation

Upper extremity fractures are typically stabilized with splints or external fixators. Most fractures of the hand and upper extremity can be managed with external splints applied to the injured limbs (Fig. 52).

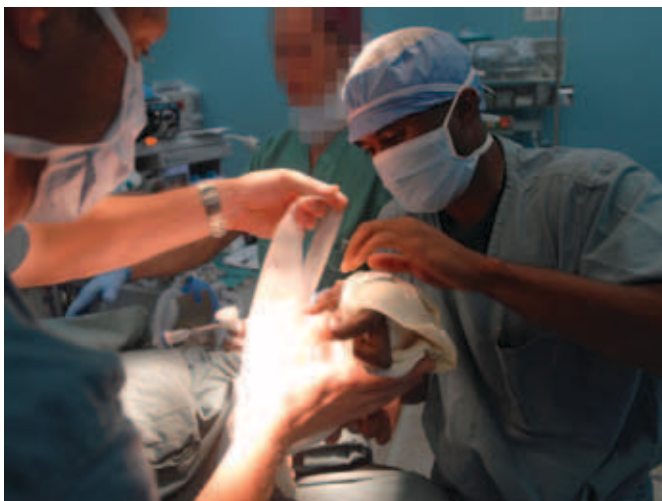

Figure 52. Most fractures of the hand and upper extremity can be managed with external splints applied to the injured limbs. Image courtesy of Defense Imagery Management Operations Center (DIMOC).

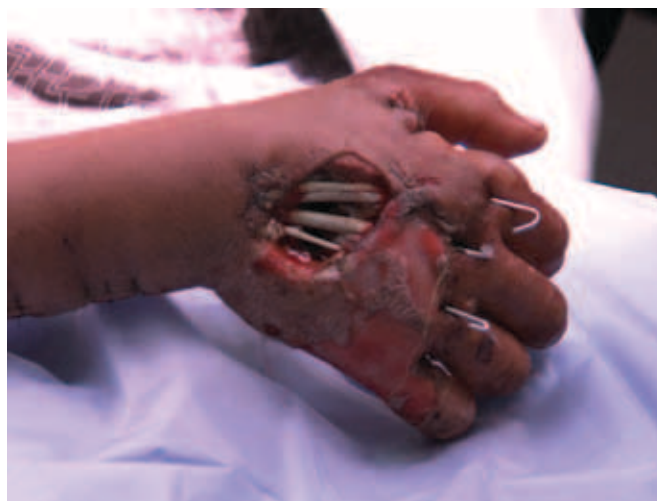

Figure 53. In this pediatric hand injury with segmental loss of multiple metacarpal shafts, K-wires were used to preserve bony length.

These splints should be well-padded. If the splints span across the wrist, they should place the wrist and hand in the neutral or safe position (wrist is placed in 20 degrees of extension, metacarpophalangeal joints are positioned at 70 degrees of flexion, and interphalangeal joints are straight), whenever possible. External fixation of upper extremity fractures can be of value in cases with marked soft-tissue injury, vascular shunt or repair, and segmental bone loss. Additionally, metacarpal fractures with bony loss may benefit from internal K-wire fixation to maintain bony length and prevent soft-tissue contracture during evacuation out of theater and initial limb resuscitation and wound debridements.<sup>77</sup> With external fixation of smaller diameter bones, the inserted pin diameter size should be kept to less than one-third of the diameter of the bone to limit the risk of fracture upon half-pin removal. When severe bony loss shortens the injured limb (e.g., segmental loss of multiple metacarpal shafts), K-wires (0.065 inch) can be placed in the proximal and distal bone fragments after four 90-degree bends are made at the desired bone length in order to keep limb length ideal during planned staged care (Fig. 53). If the hand maintains its good perfusion, it can be relatively resistant but not immune to infections and infected hardware. Fixation of hand fractures is often delayed until the wounds are clean and otherwise generally follows most civilian care principles. The priority in hand injuries in war are restoring perfusion and providing soft-tissue care followed by fracture care.

External fixation of humerus fractures should be reserved for those fractures with risk of vascular or neurologic injury due to fracture displacement. Often a coaptation splint or cuff and collar sling can suffice in simple fracture patterns, but if vascular structures have been shunted or repaired, more rigid skeletal fixation is indicated. Bony loss around the elbow joint may also be an indication for spanning external fixation, as this injury treated with a splint may displace and put traversing arteries and nerves at risk. Forearm fractures can also be managed with splinting or external fixation depending on the degree of soft-tissue injury, vascular status, and risk of displacement in a splint.

### Lower Extremity Fracture Fixation

Similar to the upper extremity injuries, lower extremity fractures are amenable to splinting or external fixation depending on the soft-tissue injury, risk of fracture displacement, and risk to vascular structures or repairs if the fractures displace. Foot injuries can be treated in a similar fashion as hand fractures;



K-wires can be fashioned to maintain metatarsal length if segmental loss is present. A plantar or posterior splint can be used for simple fracture patterns of the ankle and feet. If a splint is used across the ankle joint, the ankle should be placed in neutral dorsiflexion. Tibia fractures should be closely evaluated for presence of or potential to develop compartment syndromes. Simple closed fractures can be treated in a splint but may need additional time in-theater to allow for serial compartment checks during the first 24 to 48 hours of fracture swelling. Commonly, open tibia fractures are initially treated with external fixation. This allows for wound care, protection of neurovascular structures, and patient comfort during evacuation. Injuries of the proximal tibia and distal femur may warrant a knee-spanning external fixation to prevent knee dislocation or fracture displacement.

### Femur Fracture Fixation

Femur fractures can present with a markedly shortened, floppy limb with severe hemorrhage (both internal and external to the limb).<sup>146</sup> Restoration of the bony length reduces pain, blood loss, and risk of neurovascular injury from the sharp bony fracture surfaces.<sup>146</sup> Initially external traction splints can achieve some stability and bony alignment for safe patient transport (Fig. 54). For example, a Thomas splint, which is similar to the modern Hare traction splint, is the only other first-aid device besides the tourniquet evidenced to save lives of the limb injured (Fig. 55).<sup>146</sup> However, these traction splints rely on pressure on the ischial tuberosity proximally for their mechanical effect to hold the limb out to length. If such splints are misused or unattended, risk of sciatic nerve compression and possible risk of tourniquet-like effect by tight straps can occur. Such problems underscore the importance of periodic reassessment and adjustment of splints.

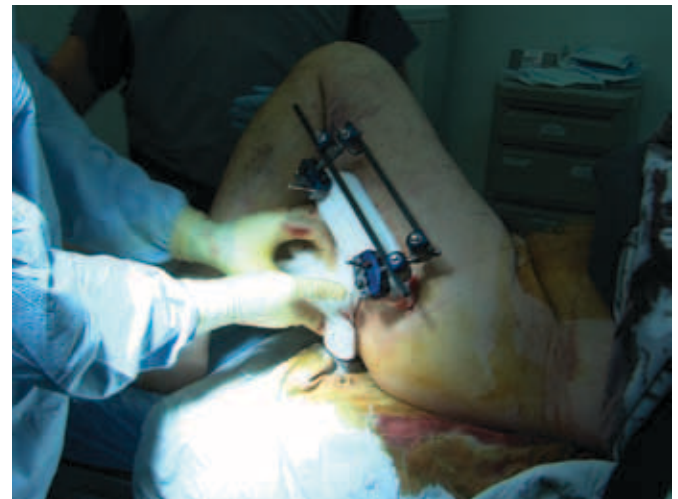
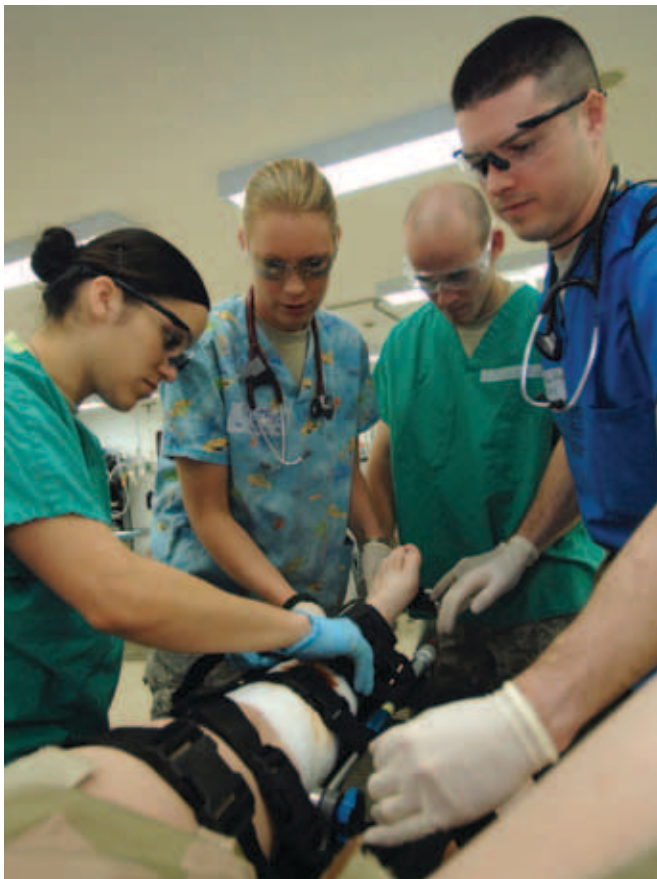
Figure 54. (Left) *An external traction splint can help stabilize and align displaced femur fractures. Image courtesy of Defense Imagery Management Operations Center (DIMOC).*

Figure 55. (Above) *Restoration of the bone length reduces pain, blood loss, and risk of neurovascular injury from sharp fracture fragments.*

Proximal tibial or distal femoral traction pins can be used to bring the femoral fracture out to length as well, but they cannot be used routinely during interhospital patient transport (Fig. 56). Hip spica casting of femur fractures should be avoided because wound access and visibility are poor, and the heavy logistical burden outweighs the benefit of the cast.<sup>147</sup> A common form of femoral fracture immobilization is half-pin external fixation in a unilateral frame configuration (Fig. 57). Safe areas for half-pin placements are from anterior in the thigh to lateral in the thigh (i.e., half-pin placement across the anterolateral quadrant is safe).<sup>142,148</sup> Care must be taken to avoid placing pins into the knee joint, as this risks septic arthritis and iatrogenic cartilage injury. Care in not overdrilling the pins through the far cortices and into the distal Hunter's canal is needed to avoid arterial injury.<sup>145</sup> Hip or knee-spanning frames may be used as well for very proximal and distal fractures, respectively.

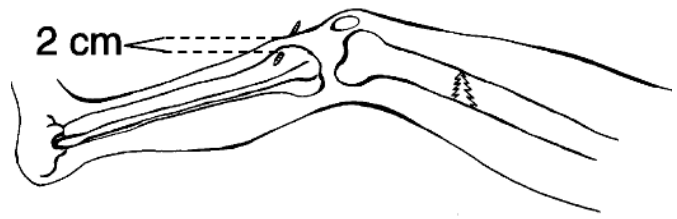

Figure 56. Proximal tibial or distal femoral traction pins can be used to bring a femoral fracture out to length. Image courtesy of the Borden Institute, Office of The Surgeon General, Washington, DC.

### Pelvic Fracture Fixation

The evaluation of patients sustaining pelvic trauma is a critical component of trauma care. Severe pelvic injuries result from high-energy trauma and are associated with a variety of injuries. A multidisciplinary

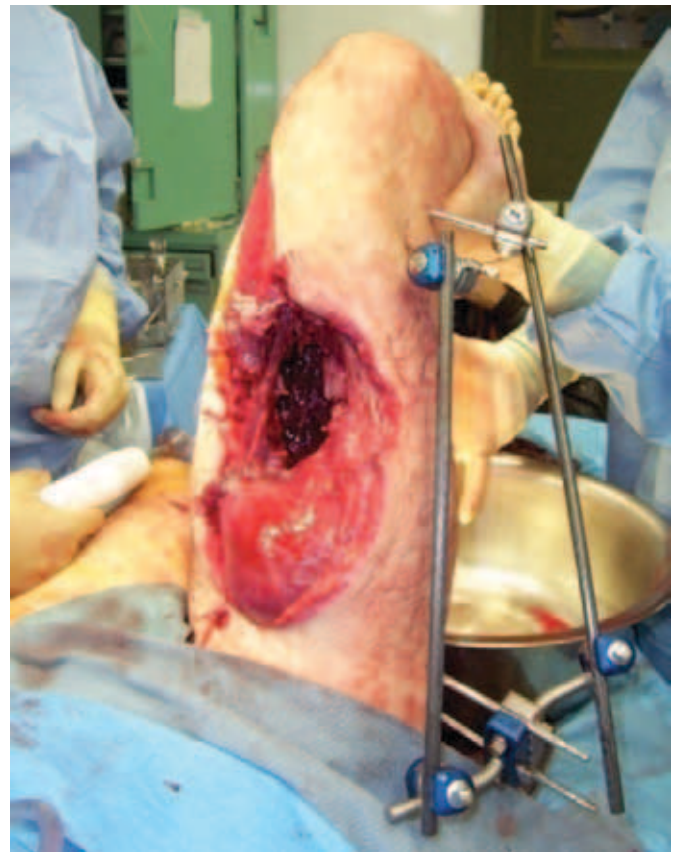
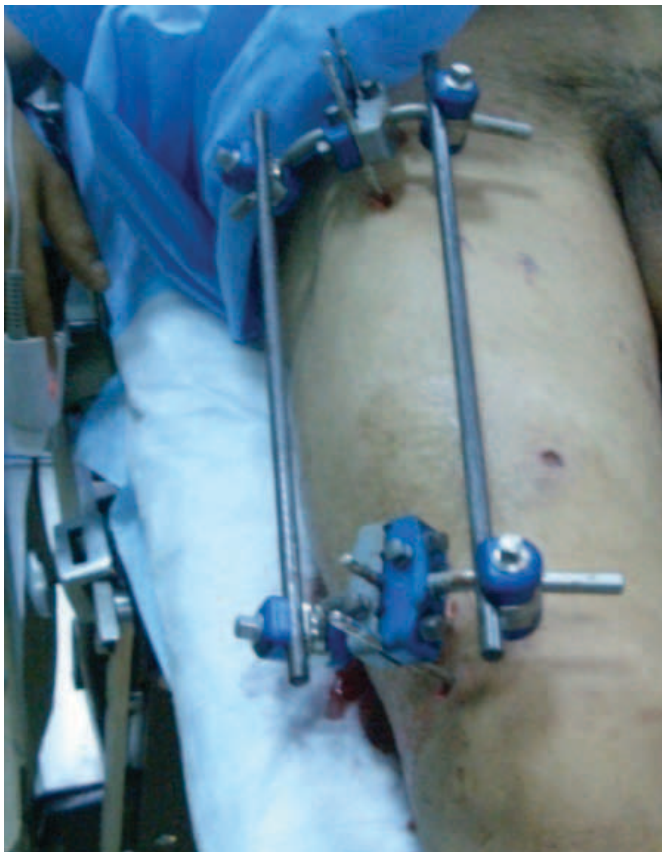
Figure 57. For femoral fracture immobilization, half-pins may be safely placed across the anterolateral quadrant of the thigh. Images courtesy of David Carmack, MD, and Michael Shaun Machen, MD, COL, MC, US Army.

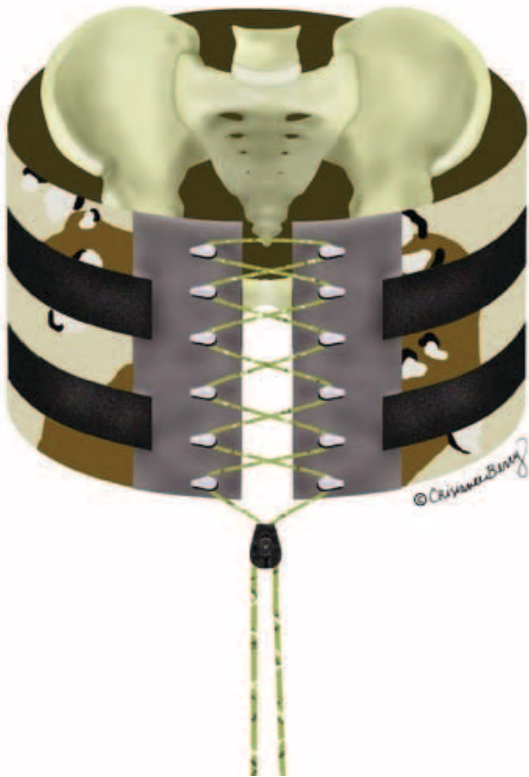
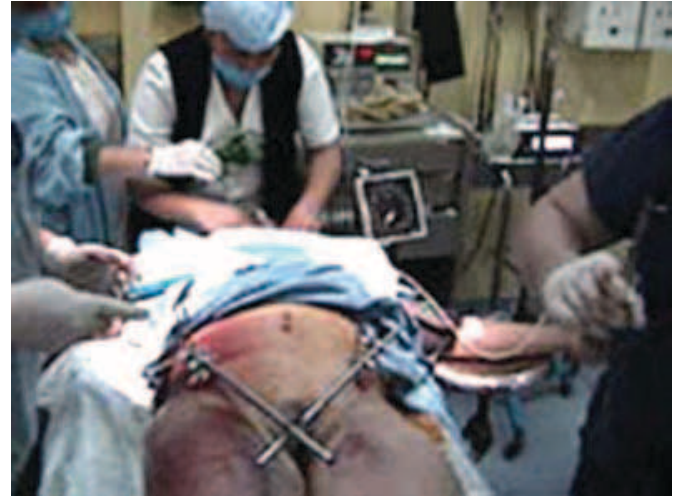
Figure 58. (Left) *Pelvic stability may be improved with application of a pelvic binder or bed sheet around the patient's hips. Image courtesy of Pelvic Binder, Inc.*

Figure 59. (Below) *Selective use of external fixation of the pelvis should be considered in patients with mechanical pelvic instability and persistent hemorrhage. Image courtesy of Trauma.org*



approach to the early care of the casualty with pelvic trauma is important. Further discussion of acute surgical issues associated with pelvic trauma is provided in the Damage Control Surgery chapter.

Early pelvic stabilization can control hemorrhage and reduce mortality.

Pelvic fractures in combat settings can present with severe and difficult to control hemorrhage.<sup>149</sup> The goals of resuscitation are to first stop the bleeding in the pelvis and then identify all open wounds. A patient with a pelvic fracture needs a thorough external and internal physical examination (including rectum and vagina) to identify any open fractures. The sources of bleeding from a pelvic fracture are venous, arterial, and bony fracture surfaces themselves. Errors in early assessment or management can increase mortality.<sup>150</sup> Fecal contamination and associated injuries can complicate care.

Patients with a pelvic fracture need a thorough external and internal physical examination (including rectum and vagina) to identify open pelvic fractures.

If the pelvic fracture pattern is unstable, initial stability may be improved with a pelvic binder or sheet around the patient's hips (greater trochanters) to reduce motion in an unstable pelvis (Fig. 58).<sup>77</sup> Pelvic binders should be avoided in lateral compression fractures because they add to the compression laterally by their pressure on the greater trochanters; in this way, pelvic binders can worsen fracture displacement.<sup>151</sup>

Eastridge et al. noted the importance of pelvic fracture pattern in guiding management in a civilian patient population suffering from pelvic ring disruption and hemorrhagic shock.<sup>149</sup> These authors noted that



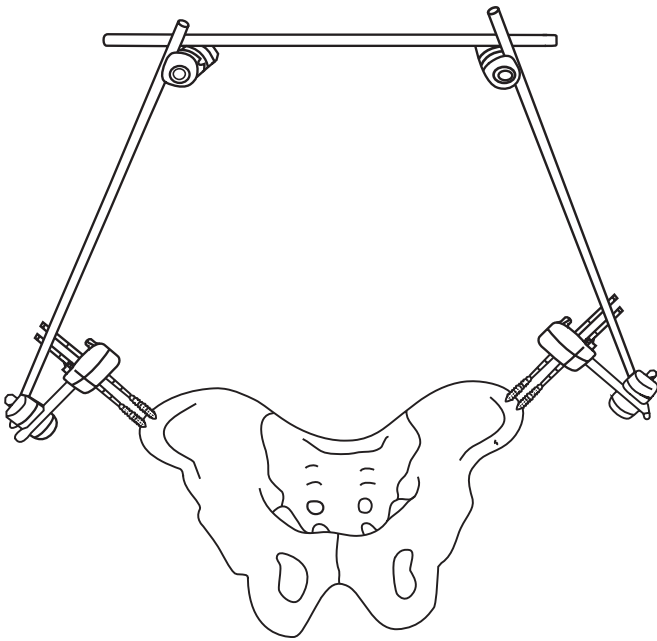


Figure 60. External fixator placement in the iliac crests allows for the most direct control of the pelvis. Image courtesy of the Borden Institute, Office of The Surgeon General, Washington, DC.

casualties with signs of ongoing shock with stable pelvic fracture patterns and hemoperitoneum require celiotomy as the initial intervention, as the site of major hemorrhage is predominantly intraperitoneal. In patients with unstable fracture patterns, even in the presence of hemoperitoneum, consideration should be given to angiography before celiotomy.<sup>149</sup> Extraperitoneal pelvic packing has been used as an adjunctive measure to angiographic embolization to achieve direct hemostasis and control venous bleeding following massive traumatic pelvic hemorrhage.<sup>151,152</sup> Further studies are required to define the utility of this approach. Interventional radiology capacity (therapeutic angiography) is limited in OEF and OIF, thus making pelvic packing a primary consideration in patients with massive pelvic hemorrhage.

If pelvic mechanical instability and hemodynamic instability persist, selective use of external fixation of the pelvis should be considered.<sup>151</sup> Rigid bony

stability may allow for hemostasis, as the hematoma and vessels may be protected from further injury during initial management.<sup>151</sup> Of note, external fixators can displace pelvic fractures with posterior element (sacroiliac joint) instability and result in anterior pelvic compression and posterior pelvic element distraction, which can exacerbate pelvic hemorrhage (Fig. 59).<sup>151</sup> This phenomenon is possible with overcompression of the anterior ring resulting in diastasis of the posterior injury.

An anterior pelvic fixator can be placed without power tools and without fluoroscopic assistance. The half-pins can be tightened into a T-handled chuck for bony insertion as the half-pin's threads can cut into bone. The half-pins that are specifically designed with blunt tips for pelvic bone insertion in the Stryker's Hoffman® II External Fixation System are commonly used in the US military. The blunt tipped half-pins tend to stay within the bone between the two tables of the pelvic bone instead of sharply cutting through the inner or outer tables, and thereby with more bony purchase have better skeletal fixation. Through a skin incision and finger dissection yielding direct digital palpation of the inner and outer cortices of the pelvis with the surgeon's thumb and forefinger, half-pins are typically inserted through the bone cortex two to four centimeters posterior to the anterior superior iliac spines aligned with and between the inner and outer tables of the pelvis. This distance posterior to the anterior superior iliac spine has the greatest amount of bone available for optimal pin placement and will avoid the lateral femoral cutaneous nerve (Fig. 60).

### **Open Pelvic Trauma**

Open pelvic fractures are uncommon in war.<sup>153</sup> When they do occur, they can present with severe hemorrhage that is difficult to control. Open pelvic fractures often result from penetrating trauma that causes less skeletal instability but higher rates of arterial hemorrhage relative to closed pelvic fractures (Figs. 61 and 62). Damage control surgery such as emergent laparotomy, proximal control of vessels, and pelvic packing may be indicated, although there is little evidence to guide management. The resuscitation



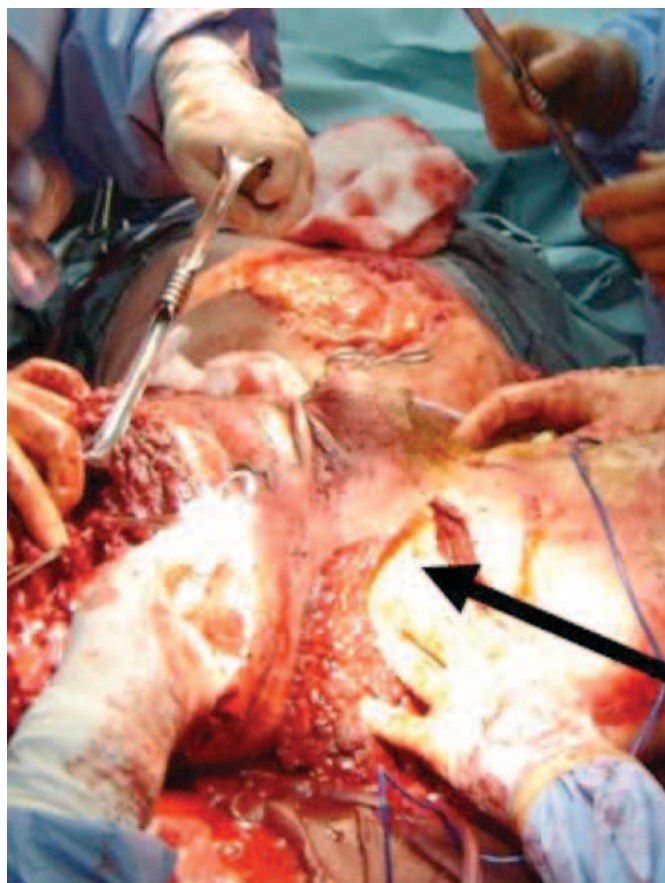
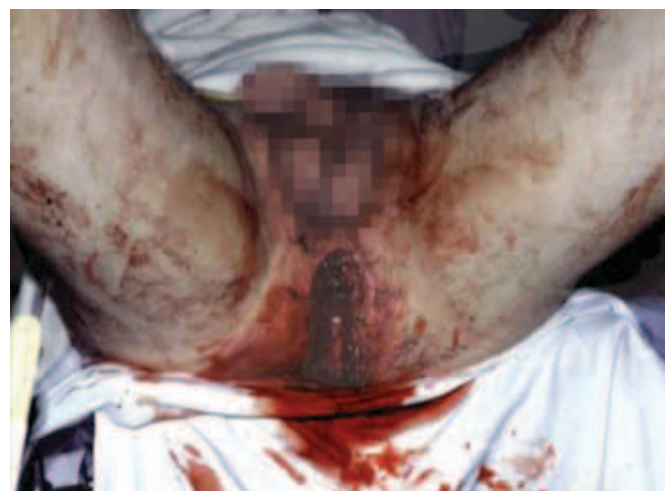
Figure 61. (Left) *Open pelvic fractures can present with severe hemorrhage that is difficult to control. This casualty required 200 units of blood in 24 hours. Image courtesy of Leopoldo C. Cancio, MD, FACS, COL, MC, US Army.*

Figure 62. (Below) *Open pelvic fractures require immediate hemorrhage control, aggressive and thorough debridement, pelvic stabilization, and a diverting colostomy in the presence of wounds at risk for fecal soiling. Image courtesy of Raymond F. Topp, MD, LTC, MC, US Army.*



requirements in such cases can be extreme and mortality rates high.<sup>153</sup> If the open fracture has radiographic findings suggestive of pelvic fracture instability commonly associated with blunt trauma, then the principles of care from blunt pelvic trauma still probably apply as discussed previously.<sup>149</sup> However, additional principles of open pelvic trauma may also apply and include consideration for massive transfusion and pelvic packing.<sup>152,154</sup>

Open pelvic fractures are uncommon in war. When present, they require immediate hemorrhage control, aggressive and thorough debridement, pelvic stabilization, and a diverting colostomy in the presence of wounds at risk for fecal soiling.

## Associated Injuries

### ***Genitourinary Complications***

The genitourinary injuries found in association with pelvic injuries are discussed in the Damage Control Surgery chapter.

### ***Hip Dislocations***

Hip dislocations are often associated with pelvic (e.g., acetabular fractures) trauma.<sup>155</sup> Hip dislocations are classified as posterior (80 to 90 percent), anterior (10 to 15 percent) and central (2 to 4 percent). All hip dislocations must be regarded as true orthopaedic emergencies (Fig. 63). Following a hip dislocation, traction on the blood vessels supplying the femoral head can result in ischemia. Prompt reduction of hip dislocations is necessary to minimize the incidence of avascular necrosis of the femoral head.<sup>156</sup>

Classic teaching is that all hip dislocations should be reduced within six hours.<sup>157,158</sup> The sooner the hip is reduced the better. The longer a hip is dislocated, the greater the risk of avascular necrosis. The timing and method of reduction depend on the patient's condition, the type of dislocation, and associated fractures. Adequate relaxation ensures the greatest chance for success. Patients will need to undergo deep sedation.

All hip dislocations must be regarded as true orthopaedic emergencies. Prompt reduction of hip dislocations is necessary to minimize the incidence of avascular necrosis of the femoral head.

Most anterior hip dislocations reduce easily with traction in line with the deformity. Posterior hip dislocations may be reduced by the Allis or Stimson maneuvers. In the Allis maneuver, an assistant stabilizes the anterior superior iliac spines while the patient is supine. First the knee is flexed, then the hip is flexed, and traction is applied below the knee pulling it upward. The leg is internally and externally rotated until reduction is achieved. The Stimson maneuver requires the patient to lie prone with the affected extremity completely off the table or stretched. The hip and knee are flexed to 90 degrees, and downward pressure is placed on the flexed knee. The leg is gently externally and internally rotated until reduction is accomplished.

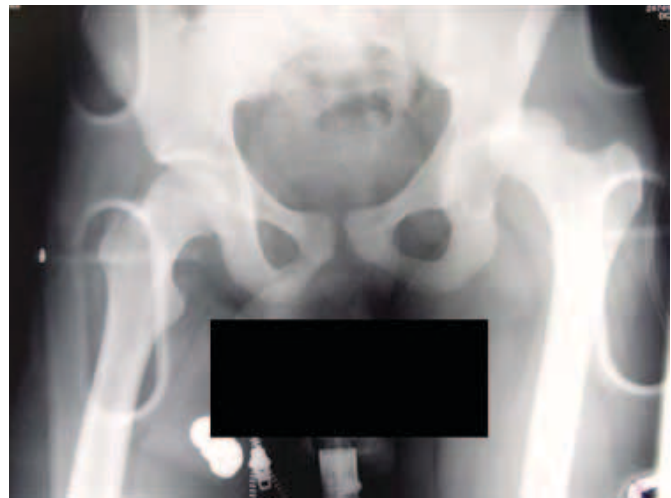

Figure 63. *Example of a left hip dislocation. All hip dislocations should be treated as true orthopaedic emergencies and reduced as soon as possible.*

Following hip reduction, an abduction pillow is placed between the patient's thighs and holds them widely apart to maintain the reduction. A post-reduction hip radiograph should be obtained to confirm adequate reduction and document any fracture fragments. Occasionally, a hip dislocation may be irreducible due to the incarceration of a tendon, joint capsule, or fracture fragment. These cases will need closed reduction under general anesthesia or open (i.e., operative) reduction.

### ***Acetabular Fractures***

Fractures of the acetabulum represent 20 percent of all pelvic fractures.<sup>159</sup> There are four types of acetabular fractures: posterior rim, transverse, iliopubic (i.e., anterior column) and ilioischial (i.e., posterior column). Posterior rim fractures represent the most common form of acetabular fracture. They are almost always associated with posterior hip dislocations. Transverse acetabular fractures may be associated with central hip dislocations. Iliopubic column acetabular fractures may be associated with central or anterior hip dislocations. Ilioischial column fractures have an associated sciatic nerve injury in 25 to 30 percent of cases.<sup>160</sup> The general treatment of acetabular fractures includes analgesia, CT imaging with thin sections to further characterize the injury, hospitalization, and orthopaedic consultation. The goal of treating acetabular fractures is to reestablish the normal femoral head and acetabular relationship. Associated hip dislocations require prompt reduction to avoid long-term complications.

## Summary

The frequency and severity of extremity injuries in OEF and OIF are substantial. Extremity injury care underscores one of the most obvious differences between military and civilian scope of practice for nonorthopaedic CCC providers. Combat casualty care providers need to have a solid understanding of the general principles of combat extremity wound and injury management. General surgeons will often need to perform orthopaedic procedures such as complex wound debridement, external fixation of fractures, and fasciotomy for compartment syndrome. For experienced orthopaedists, the means and goals of CCC differ slightly in context. For example, host nation casualty management is aimed more towards providing definitive care, to the extent local logistical constraints allow. Definitive care of US military casualties is typically deferred to Level V facilities. Balancing ideal versus practical casualty care in a combat theatre will challenge even the most seasoned care provider.

## References

1. Hamdan TA. Missile injuries of the limbs: an Iraqi perspective. *J Am Acad Orthop Surg* 2006;14(10 Spec No.):S32-36.
2. Owens BD, Kragh JF Jr, Wenke JC, et al. Combat wounds in Operation Iraqi Freedom and Operation Enduring Freedom. *J Trauma* 2008;64(2):295-299.
3. Cho JM, Jatoi I, Alarcon AS, et al. Operation Iraqi Freedom: surgical experience of the 212th Mobile Army Surgical Hospital. *Mil Med* 2005;170(4):268-272.
4. Owens BD, Kragh JF Jr, Macaitis J, et al. Characterization of extremity wounds in Operation Iraqi Freedom and Operation Enduring Freedom. *J Orthop Trauma* 2007;21(4):254-257.
5. Masini BD, Waterman SM, Wenke JC, et al. Resource utilization and disability outcome assessment of combat casualties from Operation Iraqi Freedom and Operation Enduring Freedom. *J Orthop Trauma* 2009;23(4):261-266.
6. Kelly JF, Ritenour AE, McLaughlin DF, et al. Injury severity and causes of death from Operation Iraqi Freedom and Operation Enduring Freedom: 2003-2004 versus 2006. *J Trauma* 2008;64(2 Suppl):S21-26; discussion S26-27.
7. Kragh JF Jr, Jones BH, Amaroso PJ, et al. Parachuting injuries among Army Rangers: a prospective survey of an elite airborne battalion. *Mil Med* 1996;161(7):416-419.
8. Kragh JF Jr, Taylor DC. Parachuting injuries: a medical analysis of an airborne operation. *Mil Med* 1996;161(2):67-69.
9. Kragh JF Jr, Taylor DC. Fast-roping injuries among Army Rangers: a retrospective survey of an elite airborne battalion. *Mil Med* 1995;160(6):277-279.
10. Erpelding JM, Taylor DC, Kragh JF Jr. Extremity trauma in wartime: lessons learned from recent conflicts. *Techniques in Orthopaedics* 1995;10(3):171-175.
11. Kragh JF Jr, Wade CE, Baer DG, et al. Orthopaedic trauma in the current war: severity, fasciotomy, and tourniquets. *J Orthop Trauma* In press 2010.
12. Watson F. *The Life of Sir Robert Jones*. London: Hodder & Stoughton;1934.
13. Ritenour AE, Dorlac WC, Fang R, et al. Complications after fasciotomy revision and delayed compartment release in combat patients. *J Trauma* 2008;64(2 Suppl):S153-161; discussion S161-162.
14. Reis ND, Better OS. Mechanical muscle-crush injury and acute muscle-crush compartment syndrome: with special reference to earthquake casualties. *J Bone Joint Surg Br* 2005;87(4):450-453.



15. Kragh JF Jr, Walters TJ, Baer DG, et al. Survival with emergency tourniquet use to stop bleeding in major limb trauma. *Ann Surg* 2009;249(1):1-7.
16. Ennis JL, Chung KK, Renz EM, et al. Joint Theater Trauma System implementation of burn resuscitation guidelines improves outcomes in severely burned military casualties. *J Trauma* 2008;64(2 Suppl):S146-S151; discussion S151-S152.
17. Holcomb JB, Wade CE, Michalek JE, et al. Increased plasma and platelet to red blood cell ratios improves outcome in 466 massively transfused civilian trauma patients. *Ann Surg* 2008;248(3):447-458.
18. Eastridge BJ, Jenkins D, Flaherty S, et al. Trauma system development in a theater of war: experiences from Operation Iraqi Freedom and Operation Enduring Freedom. *J Trauma* 2006;61(6):1366-1372; discussion 1372-1373.
19. Bellamy RF. The causes of death in conventional land warfare: implications for combat casualty care research. *Mil Med* 1984;149(2):55-62.
20. Bellamy, RF. Combat trauma overview. In: Textbook of military medicine. Part IV. Surgical combat casualty care: Anesthesia and perioperative care of the combat casualty. Washington, DC: Office of the Surgeon General, Borden Institute; 1995. p. 1-42.
21. Maughon JS. An inquiry into the nature of wounds resulting in killed in action in Vietnam. *Mil Med* 1970;135(1):8-13.
22. Mabry RL, Holcomb JB, Baker AM, et al. United States Army Rangers in Somalia: an analysis of combat casualties on an urban battlefield. *J Trauma* 2000;49(3):515-528; discussion 528-529.
23. Keggi KJ, Southwick WO. Early care of severe extremity wounds: a review of the Vietnam experience and its civilian applications. *Instr Course Lect* 1970;19:183-203.
24. Feltis JM J. Surgical experience in a combat zone. *Am J Surg* 1970;119(3):275-278.
25. Beebe GW, DeBakey ME, editors. Battle casualties. Springfield, IL: Charles C Thomas; 1952.
26. Beebe GW, DeBakey ME. Battle casualties: incidence, mortality, and logistic considerations. *Ann Intern Med* 1953;38(6):1345-1346.
27. Holcomb JB, Stansbury LG, Champion HR, et al. Understanding combat casualty care statistics. *J Trauma* 2006;60(2):397-401.
28. Kragh JF Jr, Baer DG, Walters TJ. Extended (16-hour) tourniquet application after combat wounds: a case report and review of the current literature. *J Orthop Trauma* 2007;21(4):274-278.
29. Bellamy RF. A note on American combat mortality in Iraq. *Mil Med* 2007;172(10):I, 1023.

30. Burns BD, Zuckerman S. The wounding power of small bomb and shell fragments. British Ministry of Supply, Advisory Council on Scientific Research and Technical Developments; 1942.
31. Holcomb JB, McMullin NR, Pearse L, et al. Causes of death in U.S. Special Operations Forces in the global war on terrorism: 2001-2004. *Ann Surg* 2007;245(6):986-991.
32. Brav EA. Military contributions to the development of orthopaedic surgery by the Armed Forces, U.S.A. Since World War I. *Clin Orthop Relat Res* 1966;44:115-126.
33. Grant RT, Reeve EB. Observations on the general effects of injury in man: with special reference to wound shock. Medical Research Council Special Report Series No. 277. London: HM Stationery Office; 1951. p. 3-67.
34. Artz CP, Howard JM, Sako Y, et al. Clinical experiences in the early management of the most severely injured battle casualties. *Ann Surg* 1955;141(3):285-296.
35. Beekley AC, Sebesta JA, Blackburne LH, et al. Prehospital tourniquet use in Operation Iraqi Freedom: effect on hemorrhage control. *J Trauma* 2008;64(2 Suppl):S28-37.
36. Kragh JF Jr, Walters TJ, Baer DG, et al. Practical use of emergency tourniquets to stop bleeding in major limb trauma. *J Trauma* 2008;64(2 Suppl):S38-49; discussion S49-50.
37. Klenerman L. The tourniquet manual. London: Springer-Verlag; 2003.
38. Brodie S, Hodgetts TJ, Ollerton J, et al. Tourniquet use in combat trauma: UK military experience. *J R Army Med Corps* 2007;153(4):310-313.
39. Parker P, Clasper J. The military tourniquet. *J R Army Med Corps* 2007;153(1):10-12.
40. Hodgetts TJ, Mahoney PF. The military tourniquet: a response. *J R Army Med Corps* 2007;153(1):12-15.
41. Mubarak SJ, Hargens AR. Compartment syndromes and Volkmann's contracture. Philadelphia, PA: Saunders; 1981. p. 50-57.
42. Balian B, Ennis O, Moorcroft CI, et al. Factors affecting healing in closed tibia fractures. American Academy of Orthopaedic Surgeons meeting; Las Vegas, NV; 2009.
43. Elliott KG, Johnstone AJ. Diagnosing acute compartment syndrome. *J Bone Joint Surg Br* 2003;85(5):625-632.
44. Rorabeck CH, Macnab I. The pathophysiology of the anterior tibial compartmental syndrome. *Clin Orthop* 1975;113:52-57.
45. Ulmer T. The clinical diagnosis of compartment syndrome of the lower leg: are clinical findings

predictive of the disorder. *J Orthop Trauma* 2002;16(8):572-577.

46. McQueen MM, Christie J, Court-Brown CM. Acute compartment syndrome in tibial diaphyseal fractures. *J Bone Joint Surg Br* 1996;78(1):95-98.

47. Kragh JF. Joint Theater Trauma System (JTTS) Clinical Practice Guideline. Compartment syndrome (CS) and the role of fasciotomy in extremity war wounds. 2009 Apr 30 [cited 2010 May 5]. Available from: URL: <http://www.usaisr.amedd.army.mil/cpgs.html>.

48. Tull F, Borrelli J Jr. Soft-tissue injury associated with closed fractures: evaluation and management. *J Am Acad Orthop Surg* 2003;11(6):431-438.

49. Cope O, Moore FD. The redistribution of body water and the fluid therapy of the burned patient. *Ann Surg* 1947;126(6):1010-1045.

50. Tremblay LN, Feliciano DV, Rozycki GS. Secondary extremity compartment syndrome. *J Trauma* 2002;53(5):833-837.

51. Kosir R, Moore FA, Selby JH et al. Acute lower extremity compartment syndrome (ALECS) screening protocol in critically ill trauma patients. *J Trauma* 2007;63(2):268-275.

52. Madigan MC, Kemp CD, Johnson JC, et al. Secondary abdominal compartment syndrome after severe extremity injury: are early, aggressive fluid resuscitation strategies to blame? *J Trauma* 2008;64(2):280-285.

53. Revell M, Greaves I, Porter K. Endpoints for fluid resuscitation in hemorrhagic shock. *J Trauma* 2003;54(5 Suppl):S63-67.

54. Tornetta P III, Templeman D. Compartment syndrome associated with tibial fracture. *Instr Course Lect* 1997;46:303-308.

55. Heckman MM, Whitesides TE Jr, Grewe SR, et al. Compartment pressure in association with closed tibial fractures. The relationship between tissue pressure, compartment, and the distance from the site of the fracture. *J Bone Joint Surg Am* 1994;76(9):1285-1292.

56. Nessen SC, Lounsbury DE, Hetz SP, editors. Soft-tissue Trauma and Burns. In: War Surgery in Afghanistan and Iraq: A Series of Cases, 2003-2007. Washington, DC: Department of the Army, Office of the Surgeon General, Borden Institute; 2008. p. 205-248.

57. US Department of Defense (US DoD) Extremity fractures. In: Emergency War Surgery, Third United States Revision. Washington, DC: Department of the Army, Office of the Surgeon General, Borden Institute; 2004. p. 23.1-23.21.

58. Sheridan GW, Matsen FA III. Fasciotomy in the treatment of the acute compartment syndrome. *J Bone Joint Surg Am* 1976;58(1):112-115.

59. Matsen FA III, Wyss CR, Krugmire RB Jr, et al. The effects of limb elevation and dependency on local arteriovenous gradients in normal human limbs with particular reference to limbs with increased tissue pressure. *Clin Orthop Relat Res* 1980;150:187-195.
60. Bronwell AW, Artz CP, Sako Y. Recent advances in medicine and surgery based on professional medical experiences in Japan and Korea 1950-1953. *Debridement in Medical Science Publication No. 4*. US Army Medical Service Graduate School. Washington, DC: Walter Reed Army Medical Center; 19-30 Apr, 1954.
61. Stansbury LG, Branstetter JG, Lalliss SJ. Amputation in military trauma surgery. *J Trauma* 2007;63(4):940-944.
62. US Department of Defense (US DoD). General Considerations of Forward Surgery. In: *Emergency War Surgery, Second United States Revision*. Washington, DC: Department of the Army, Office of the Surgeon General, Borden Institute; 1988.
63. US Department of Defense (US DoD). Amputations. In: *Emergency War Surgery, Third United States Revision*. Washington, DC: Department of the Army, Office of the Surgeon General, Borden Institute; 2004. p. 25.1-25.8.
64. Stansbury LG, Lalliss SJ, Branstetter JG, et al. Amputations in U.S. military personnel in the current conflicts in Afghanistan and Iraq. *J Orthop Trauma* 2008;22(1):43-46.
65. Fox CJ, Gillespie DL, Cox ED, et al. The effectiveness of a damage control resuscitation strategy for vascular injury in a combat support hospital: results of a case control study. *J Trauma* 2008;64(2 Suppl):S99-106; discussion S106-107.
66. Fox CJ, Gillespie DL, Cox ED, et al. Damage control resuscitation for vascular surgery in a combat support hospital. *J Trauma* 2008;65(1):1-9.
67. Fox CJ, Mehta SG, Cox ED, et al. Effect of recombinant factor VIIa as an adjunctive therapy in damage control for wartime vascular injuries: a case control study. *J Trauma* 2009;66(4 Suppl):S112-119.
68. Bosse MJ, MacKenzie EJ, Kellam JF, et al. A prospective evaluation of the clinical utility of the lower-extremity injury-severity scores. *J Bone Joint Surg Am* 2001;83-A(1):3-14.
69. Bosse MJ, McCarthy MJ, Jones AL, et al. The Lower Extremity Assessment Project (LEAP) Study Group. The insensate foot following severe lower extremity trauma: an indication for amputation? *J Bone Joint Surg Am* 2005;87(12):2601-2608.
70. Hsu JR, Beltran MJ; Skeletal Trauma Research Consortium. Shortening and angulation for soft-tissue reconstruction of extremity wounds in a combat support hospital. *Mil Med* 2009;174(8):838-842.
71. Gulsen M, Ozkan C. Angular shortening and delayed gradual distraction for the treatment of asymmetrical bone and soft-tissue defects of tibia: a case series. *J Trauma* 2009;66(5):E61-66.



72. Webb LX, Dedmond B, Schlatterer D, et al. The contaminated high-energy open fracture: a protocol to prevent and treat inflammatory mediator storm-induced soft-tissue compartment syndrome (IMSICS). *J Am Acad Orthop Surg* 2006;14(10 Spec No.):S82-86.
73. Langworthy MJ, Smith JM, Gould M. Treatment of the mangled lower extremity after a terrorist blast injury. *Clin Orthop* 2004;422:88-96.
74. O'Shaughnessy KD, Dumanian GA, Lipschutz RD, et al. Targeted reinnervation to improve prosthesis control in transhumeral amputees. A report of three cases. *J Bone Joint Surg Am* 2008;90(2):393-400.
75. Barillo DJ, Cancio LC, Goodwin CW. Treatment of white phosphorus and other chemical burn injuries at one burn center over a 51-year period. *Burns* 2004;30(5):448-52.
76. US Department of Defense (US DoD). Burn injuries. In: *Emergency War Surgery, Third United States Revision*. Washington, DC: Department of the Army, Office of the Surgeon General, Borden Institute; 2004. p. 28.1-28.15.
77. Nessen SC, Lounsbury DE, Hetz SP, editors. Orthopedic Trauma. In: *War Surgery in Afghanistan and Iraq: A Series of Cases, 2003-2007*. Washington, DC: Department of the Army, Office of the Surgeon General, Borden Institute; 2008. p. 249-316.
78. Hayda RA, Ficke JR. Wartime amputation instructional video [Digital video disc]. Washington, DC: Department of the Army; Feb 2002.
79. Dougherty PJ. Wartime amputee care. In: Smith DG, Michael JW, Bowker JH, editors. *Atlas of amputations and limb deficiencies: surgical, prosthetic, and rehabilitation*. 3rd ed. Rosemont, IL: American Academy of Orthopaedic Surgeons; 2004. p. 77-97.
80. Smith DG, Granville RR. Moderators' summary: amputee care. *J Am Acad Orthop Surg* 2006;14(10 Spec No.):S179-182.
81. Gajewski D, Granville R. The United States Armed Forces Amputee Patient Care Program. *J Am Acad Orthop Surg* 2006;14(10 Spec No.):S183-187.
82. Potter BK, Scoville CR. Amputation is not isolated: an overview of the US Army Amputee Patient Care Program and associated amputee injuries. *J Am Acad Orthop Surg* 2006;14(10 Spec No.):S188-90.
83. Rehabilitation of the injured combatant, Vol 1. Textbook of military medicine. Washington, DC: Department of the Army, Office of The Surgeon General, Borden Institute; 1998.
84. Rehabilitation of the injured combatant, Vol 2. Textbook of military medicine. Washington, DC: Department of the Army, Office of The Surgeon General, Borden Institute; 1999.
85. Hospenhal DR, Murray CK, Andersen RC, et al. Guidelines for the prevention of infection after combat-related injuries. *J Trauma* 2008;64(3 Suppl):S211-S220.

86. Vertrees A, Fox CJ, Quan RW, et al. The use of prosthetic grafts in complex military vascular trauma: a limb salvage strategy for patients with severely limited autologous conduit. *J Trauma* 2009;66(4):980-983.
87. Fox CJ, Starnes BW. Vascular surgery on the modern battlefield. *Surg Clin North Am* 2007;87(5):1193-1211.
88. Kragh JF Jr, Basamania CJ. Surgical repair of acute traumatic closed transection of the biceps brachii. *J Bone Joint Surg Am* 2002;84-A(6):992-998.
89. Kragh JF Jr, Svoboda SJ, Wenke JC, et al. Suturing of lacerations of skeletal muscle. *J Bone Joint Surg Br* 2005;87(9):1303-1305.
90. Kragh JF Jr, Svoboda SJ, Wenke JC, et al. The role of epimysium in suturing skeletal muscle lacerations. *J Am Coll Surg* 2005;200(1):38-44.
91. Chance JR, Kragh JF Jr, Agrawal CM, et al. Pullout forces of sutures in muscle lacerations. *Orthopaedics* 2005;28(10):1187-1190.
92. Kragh JF Jr, Svoboda SJ, Wenke JC, et al. Epimysium and perimysium in suturing in skeletal muscle lacerations. *J Trauma* 2005;59(1):209-212.
93. Kragh JF Jr, Svoboda SJ, Wenke JC, et al. Passive biomechanical properties of sutured mammalian muscle lacerations. *J Invest Surg* 2005;18(1):19-23.
94. Burkhalter WE, editor. Orthopaedic surgery in Vietnam. Medical Department, United States Army. Washington, DC: Office of the Surgeon General and Center of Military History; 1994.
95. Voit GA, Irvine G, Beals RK. Saline load test for penetration of periarticular lacerations. *J Bone Joint Surg Br* 1996;78(5):732-733.
96. Nord RM, Quach T, Walsh M, et al. Detection of traumatic arthrotomy of the knee using the saline solution load test. *J Bone Joint Surg Am* 2009;91(1):66-70.
97. Keese GR, Boody AR, Wongworawat MD, et al. The accuracy of the saline load test in the diagnosis of traumatic knee arthrotomies. *J Orthop Trauma* 2007;21(7):442-443.
98. Vutskits L, Briner A, Klauser P, et al. Adverse effects of methylene blue on the central nervous system. *Anesthesiology* 2008;108(4):684-692.
99. Mathew S, Linhartova L, Raghuraman G. Hyperpyrexia and prolonged postoperative disorientation following methylene blue infusion during parathyroidectomy. *Anaesthesia* 2006;61(6):580-583.
100. Sweet G, Standiford SB. Methylene-blue-associated encephalopathy. *J Am Coll Surg* 2007;204(3):454-458.

101. Ng BK, Cameron AJ, Liang R, et al. Serotonin syndrome following methylene blue infusion during parathyroidectomy: a case report and literature review. *Can J Anaesth* 2008;55(1):36-41.
102. Omer GE Jr, Spinner M, Van Beeks AL, editors. *Management of peripheral nerve problems*. 2nd ed. Philadelphia: W.B. Saunders; 1998.
103. Sunderland S. *Nerves and nerve injuries*. New York: Churchill Livingstone; 1978.
104. US Department of Defense (US DoD). *Wounds and Injuries of Peripheral Nerves*. In: *Emergency War Surgery, Second United States Revision*. Washington, DC: Department of the Army, Office of the Surgeon General, Borden Institute; 1988.
105. US Department of Defense (US DoD). *Soft-tissue injuries*. In: *Emergency War Surgery, Third United States Revision*. Washington, DC: Department of the Army, Office of the Surgeon General, Borden Institute; 2004. p. 22.1-22.15.
106. Kumar AR. Standard wound coverage techniques for extremity war injury. *J Am Acad Orthop Surg* 2006;14(10 Spec No.):S62-65.
107. Moran KA, Murray CK, Anderson EL. Bacteriology of blood, wound, and sputum cultures from non-US casualties treated in a combat support hospital in Iraq. *Infect Control Hosp Epidemiol* 2008;29(10):981-984.
108. Rajasekaran S, Dheenadhayalan J, Babu JN, et al. Immediate primary skin closure in type-III A and B open fractures: results after a minimum of five years. *J Bone Joint Surg Br* 2009;91(2):217-224.
109. Manring MM, Hawk A, Calhoun JH, et al. Treatment of war wounds: a historical review. *Clin Orthop Rel Res* 2009;467(8):2168-2191.
110. Sherman R, Rahban S, Pollak AN. Timing of wound coverage in extremity war injuries. *J Am Acad Orthop Surg* 2006;14(10 Spec No.):S57-61.
111. Noe A. Extremity injury in war: a brief history. *J Am Acad Orthop Surg* 14(10 Spec No.):S1-6.
112. Levin LS. New developments in flap techniques. *J Am Acad Orthop Surg* 2006;14(10 Spec No.):S90-93.
113. Murray CK. Infectious disease complications of combat-related injuries. *Crit Care Med* 2008;36(7 Suppl):S358-364.
114. Murray CK, Roop SA, Hospenthal DR, et al. Bacteriology of war wounds at the time of injury. *Mil Med* 2006;171(9):826-829.
115. Owens BD, Wenke JC. Early wound irrigation improves the ability to remove bacteria. *J Bone Joint Surg Am* 2007;89(8):1723-1726.

116. Murray CK, Hsu JR, Solomkin JS, et al. Prevention and management of infections associated with combat-related extremity injuries. *J Trauma* 2008;64(3 Suppl):S239-251.
117. Lin DL, Kirk KL, Murphy KP, et al. Evaluation of orthopaedic injuries in Operation Enduring Freedom. *J Orthop Trauma* 2004;18(8 Suppl):S48-53.
118. Johnson EN, Burns TC, Hayda RA, et al. Infectious complications of open type III tibial fractures among combat casualties. *Clin Infect Dis* 2007;45(4):409-415.
119. Yun HC, Branstetter JG, Murray CK. Osteomyelitis in military personnel wounded in Iraq and Afghanistan. *J Trauma* 2008;64(2 Suppl):S163-168; discussion S168.
120. Owens BD, Wenke JC, Svoboda SJ, et al. Extremity trauma research in the United States Army. *J Am Acad Orthop Surg* 2006;14(10 Spec No.):S37-40.
121. Owens BD, White DW, Wenke JC. Comparison of irrigation solutions and devices in a contaminated musculoskeletal wound survival model. *J Bone Joint Surg Am* 2009;91(1):92-98.
122. Joint Theater Trauma System Clinical Practice Guidelines. Initial management of war wounds: wound debridement and irrigation. 2010 Mar 1 [cited 2010 May 5]. Available from: URL: <http://www.usaisr.amedd.army.mil/cpgs.html>.
123. Svoboda SJ, Owens BD, Gooden HA, et al. Irrigation with potable water versus normal saline in a contaminated musculoskeletal wound model. *J Trauma* 2008;64(5):1357-1359.
124. Bowyer G. Débridement of extremity war wounds. *J Am Acad Orthop Surg* 2006;14(10 Spec No.):S52-56.
125. Rose CA, Hess OW, Welch CS. Vascular injuries of the extremities in battle casualties. *Ann Surg* 1946;123(2):161-179.
126. Artz CP, Sako Y, Scully RE. An evaluation of the surgeon's criteria for determining the viability of muscle during debridement. *AMA Arch Surg* 1956;73(6):1031-1035.
127. Peyser A, Khoury A, Liebergall M. Shrapnel management. *J Am Acad Orthop Surg* 2006;14(10 Spec No.):S66-70.
128. Simchen E, Raz R, Stein H, et al. Risk factors for infection in fracture war wounds (1973 and 1982 wars, Israel). *Mil Med* 1991;156(10):520-527.
129. Parker MJ, Livingstone V, Clifton R, et al. Closed suction surgical wound drainage after orthopaedic surgery. *Cochrane Database Syst Rev* 2007;3:CD001825.
130. Kauvar DS, Wade CE. The epidemiology and modern management of traumatic hemorrhage: US and international perspectives. *Crit Care* 2005;9 (Suppl 5):S1-9.



131. Nelson DE. Coagulation problems associated with multiple transfusions secondary to soft-tissue injury. *USARV Medical Bulletin* 1968;3(5):40-49.
132. Bowden RE, Gutmann E. The fate of voluntary muscle after vascular injury in man. *J Bone Joint Surg Am* 1949;31B(3):356-68.
133. Leininger BE, Rasmussen TE, Smith DL, et al. Experience with wound VAC and delayed primary closure of contaminated soft tissue injuries in Iraq. *J Trauma* 2006;61(5):1207-1211.
134. Lalliss SJ, Branstetter JG, Murray CK, et al. Infection rates in U.S. military personnel using vacuum-assisted closure. *Plast Reconstr Surg* 2007;120(2):574-575;author reply 575-576.
135. Webb LX. New techniques in wound management: vacuum-assisted wound closure. *J Am Acad Orthop Surg* 2002;10(5):303-311.
136. Berkowitz MJ, Rediske MW, Chance MJ, et al. Technique tip: creation of a vacuum-assisted closure system for wound management in an austere environment. *Foot Ankle Int* 2007;28(3):388-391.
137. Wenke JC, Owens BD, Svoboda SJ, et al. Effectiveness of commercially-available antibiotic-impregnated implants. *J Bone Joint Surg Br* 2006;88(8):1102-1104.
138. Thomas DB, Brooks DE, Bice TG, et al. Tobramycin-impregnated calcium sulfate prevents infection in contaminated wounds. *Clin Orthop Relat Res* 2005;441:366-371.
139. Butler F, O'Connor K. Antibiotics in tactical combat casualty care 2002. *Mil Med* 2003;168(11):911-914.
140. Holtom PD. Antibiotic prophylaxis: current recommendations. *J Am Acad Orthop Surg* 2006;14(10 Spec No.):S98-100.
141. Mazurek MT, Burgess AR. Moderators' summary: stabilization of long bones. *J Am Acad Orthop Surg* 2006;14(10 Spec No.):S113-117.
142. Catagni, MA. Atlas for the insertion of transosseous wires and half-pins: Ilizarov method. 2nd ed. Memphis, TN: Smith & Nephew Orthopaedics; 2003.
143. Dougherty PJ, Silvertown C, Yeni Y, et al. Conversion from temporary external fixation to definitive fixation: shaft fractures. *J Am Acad Orthop Surg* 2006;14(10 Spec No.):S124-127.
144. Della Rocca GJ, Crist BD. External fixation versus conversion to intramedullary nailing for definitive management of closed fractures of the femoral and tibial shaft. *J Am Acad Orthop Surg* 2006;14(10 Spec No.):S131-135.
145. Topp RF, Hayda R, Benedetti G, et al. The incidence of neurovascular injury during external fixator placement without radiographic assistance for lower extremity diaphyseal fractures: a cadaveric

study. *J Trauma* 2003;55(5):955-958.

146. Kirkup J. Foundation lecture. Fracture care of friend and foe during World War I. *ANZ J Surg* 2003;73(6):453-459.

147. McHenry T, Simmons S, Alitz C, et al. Forward surgical stabilization of penetrating lower extremity fractures: circular casting versus external fixation. *Mil Med* 2001;166(9):791-795.

148. Mehta S, Sankar WN, Born CT. External fixation of the pelvis and extremities. Philadelphia, PA: Lippincott Williams & Wilkins; 2005.

149. Eastridge BJ, Starr A, Minei JP, et al. The importance of fracture pattern in guiding therapeutic decision-making in patients with hemorrhagic shock and pelvic ring disruptions. *J Trauma* 2002;53(3):446-450; discussion 450-451.

150. Giannoudis PV, Pape HC. Damage control orthopaedics in unstable pelvic ring injuries. *Injury* 2004;35(7):671-677.

151. Hak DJ, Smith WR, Suzuki T. Management of hemorrhage in life-threatening pelvic fracture. *J Am Acad Orthop Surg* 2009;17(7):447-457.

152. Tötterman A, Madsen JE, Skaga NO, et al. Extraperitoneal pelvic packing: a salvage procedure to control massive traumatic pelvic hemorrhage. *J Trauma* 2007;62(4):843-852.

153. US Department of Defense (US DoD). Pelvic Injuries. In: Emergency War Surgery, Third United States Revision. Washington, DC: Department of the Army, Office of the Surgeon General, Borden Institute; 2004. p. 21.1-21.4.

154. Joint Theater Trauma System (JTTS) Clinical Practice Guideline. Pelvic fracture care. 2008 Nov 12 [cited 2010 May 5]. Available from: URL: <http://www.usaisr.amedd.army.mil/cpgs.html>.

155. Alonso JE, Volgas DA, Giordano V, et al. A review of the treatment of hip dislocations associated with acetabular fractures. *Clin Orthop Relat Res* 2000;Aug(377):32-43.

156. Yang EC, Cornwall R. Initial treatment of traumatic hip dislocations in the adult. *Clin Orthop Relat Res* 2000;Aug(377):24-31.

157. Rodríguez-Merchán EC. Osteonecrosis of the femoral head after traumatic hip dislocation in the adult. *Clin Orthop Relat Res* 2000;Aug(377):68-77.

158. Cash DJ, Nolan JF. Avascular necrosis of the femoral head 8 years after posterior hip dislocation. *Injury* 2007;38(7):865-867.

159. Gibbs MA, Bosse MJ. Pelvic ring fractures. In: Ferrera PC, Colucciello SA, Marx JA, et al, editors. Trauma management: an emergency medicine approach. St Louis, MO: Mosby; 1998. p. 330-333.

160. Hillyard RF, Fox J. Sciatic nerve injuries associated with traumatic posterior hip dislocations. *Am J Emerg Med* 2003;21(7):545-548.

## Appendices


1. Combat Application Tourniquet (C-A-T®) Application Steps
2. Joint Theater Trauma System Clinical Practice Guideline — Compartment Syndrome (CS) and the Role of Fasciotomy in Extremity War Wounds
3. Glossary and Classification of Amputations
4. Joint Theater Trauma System Clinical Practice Guideline — Irrigation of War Wounds





## Combat Application Tourniquet®

The C-A-T is delivered in its one-handed configuration. This is the recommended storage configuration.



### Instructions for Use: Two-handed Application

- 1 Route the band around the limb and pass the red tip through the

inside slit of the buckle. Pull the band tight.



- 2 Pass the red tip through the outside slit of the buckle.

The friction buckle will lock the band in place.



- 3 Pull the band **very tight** and securely fasten the band back on itself.

When the band is pulled tight, no more than 3 fingers will fit between the band and the limb.



- 4 Twist the rod **until bright red bleeding has stopped**

**and the distal pulse is eliminated.**



- 5 Place the rod inside the clip locking it in place. **Check for bleeding**

**and distal pulse.** If bleeding is not controlled, apply a second tourniquet proximal to the first and reassess.



- 6 Secure the rod inside the clip with the strap.

**Prepare the patient for transport and reassess.**

Record the time of application.



### Using the Friction Buckle

For two-handed application or when *the band becomes dirty*, use the friction buckle to lock the band in place.

- 1 Pass the red tip through the

inside slit of the buckle. Pull the band tight.



- 2 Pass the red tip through the

outside slit of the buckle.



- 3 Pull the band tight

and securely fasten the band back on itself.



The Combat Application Tourniquet® is Patent Pending

RAW-18050


1

Licensed and manufactured by:  
Composite Resources Inc.  
803.366.9700 [www.composite-resources.com](http://www.composite-resources.com)



## Instructions for Use: One-handed Application

The C-A-T is delivered in its one-handed configuration. This is the recommended storage configuration.



- 1 Insert the wounded limb through the loop formed by the band.



- 2 Pull the band tight and securely fasten the band back on itself.



- 3 Adhere the band around the limb. Do not adhere the band past the rod clip.



- 4 Twist the rod until **bright red bleeding has stopped and the distal pulse is eliminated.**



- 5 Place the rod inside the clip locking it in place. **Check for bleeding and distal pulse.**



- 6 Adhere the band over the rod, inside the clip, and fully around the limb.



- 7 Secure the rod and band with the strap. **Prepare for transport and reassess.**



## Storing in the One-Handed Configuration

- 1 Pass the red tip through the inside slit in the buckle.

Pull 6" of band through, fold it back and adhere the band to itself.



- 2 Flatten the loop formed by the band.

Place the buckle in the middle of the flattened band.



- 3 Fold the C-A-T in half placing the buckle at one end.

The C-A-T is now ready to be placed in your medical kit.



EMS Orange  
PN 30-0023

Trainer Blue  
NSN 6910-01-560-2972



Exclusive distribution in the U.S. by:  
**North American Rescue Inc. 1-888-689-6277**  
www.NARescue.com info@NARescue.com  
NSN 6515-01-521-7976

### WARNING: THIS IS A SINGLE USE PRODUCT

This product is intended for qualified medical professionals trained in the application of a tourniquet. It is not intended for the general public. Use only as directed by your EMS authority or under the supervision of a physician. Read entire Instructions For Use prior to using this product. Inappropriate application can result in serious injury or loss of limb. The use of any tourniquet is **A LAST RESORT** and should only be employed when bleeding cannot be stopped and the situation is life threatening.

### LIMITATION OF LIABILITY:

Composite Resources, Inc., its employees, agents, contractors, suppliers, and distributors shall assume no liability for injury or damages arising from the application and use of the Combat Application Tourniquet® (C-A-T®). The user assumes all risk of liability.

## Joint Theater Trauma System Clinical Practice Guideline

**COMPARTMENT SYNDROME (CS) AND THE ROLE OF FASCIOTOMY  
IN EXTREMITY WAR WOUNDS**

Original Release/Approval	30 Apr 09	Note: This CPG requires an annual review.	
Reviewed:	Apr 09	Approved:	30 Apr 09
Supersedes:	This is a new CPG		
<input type="checkbox"/> Minor Changes (or)	<input type="checkbox"/> <i>Changes are substantial and require a thorough reading of this CPG (or)</i>		
<input type="checkbox"/> Significant Changes:			

**1. Goal.** Provide an overview of CS and present a standardized approach to guide providers in the evaluation and treatment of patients with extremity war wounds, including the role of prophylactic and therapeutic fasciotomy.

**2. Background.** Compartment syndrome (CS) is a common, controversial, and disabling problem in the current war. Recent research indicates proper detection of compartment syndrome is lifesaving; and lethal if late.<sup>1</sup> The operational definition of compartment syndrome is a clinical syndrome wherein high pressure within a myofascial space reduces perfusion and decreases tissue viability. Therapeutic fasciotomy is indicated for established compartment syndrome, and prophylactic fasciotomy is indicated for risk of compartment syndrome.<sup>2-4</sup> Fasciotomy during lag phase between injury and syndrome onset is prophylactic. Early detection is challenging, so prophylactic fasciotomy is routine when compartment syndrome is likely; but the circumstances for prophylactic fasciotomy are unclear. Injury, treatment, and casualty variables affect risk (Tables 1 and 2).<sup>1-7</sup> Variable importance and their time lags differ widely, but the main factors are limb injury severity (particularly vessel injuries), and overall casualty injury severity (particularly shock) with a lesser factor being over-resuscitation (particularly >5 liters of crystalloid). Some factors are interrelated, e.g. in rats functional loss resulting from tourniquet use is worsened by additional hemorrhage in fast-twitch but not slow twitch muscles. Surveys indicate surgeons with more education and experience are willing to perform fasciotomy more often, and the fasciotomy rate has increased five-fold in the current war. Initially, the rate was too low, but the optimal rate is unknown. Other variables may affect limb ischemia-reperfusion with swelling. In and of itself, injury swelling maximizes in 1 to 2 days, additional swelling from post-injury ischemia-reperfusion (e.g., revascularization, shock, tourniquet use) appears to delay maximal limb swelling further; perhaps to 2 to 3 days post injury. Problems with compartment syndrome include morbidity and mortality (Table 3). High altitude (including normal AE aircraft cabin pressure), in and of itself, is not a contributor to compartment syndrome. Once the decision has been made to perform a prophylactic or therapeutic fasciotomy, a complete fasciotomy must be performed. There is evidence to support complete compartment release by full-length skin and fascial incisions is superior to limited fasciotomy.

**3. Evaluation and Treatment.**

- a. The signs and symptoms of CS are the classic 5 P's which include: pain on passive stretch of muscle often out of proportion to that of the injury as expected by the provider; palpably tense muscle compartments; paralysis; paresthesias or sensory deficit; pulslessness.<sup>2</sup> Pain is sensitive and early given a cooperative casualty, but it is not

Guideline Only/Not a Substitute for Clinical Judgment

April 2009



---

## Joint Theater Trauma System Clinical Practice Guideline

---

specific. Palpably tense muscle is specific but not sensitive, and usually there is some swelling; rigor is differentiated by stiffness. Paralysis and paresthesias are generally late and least helpful acutely. Pulselessness is seen virtually never in civilian compartment syndrome, but occurs rarely in war, sometimes within minutes of an arterial injury or an expanding hematoma.

- b. The most common compartment syndrome is in the anterior leg.<sup>1-2</sup> About 45% of all compartment syndromes are caused by tibia fracture, and Volkmann's contracture occurs in 1% to 10% of cases of CS. Open fractures, even with traumatic fasciotomy, have higher CS rates than closed fractures because they are more severe, with more swelling and more often injured arteries. The most commonly missed compartment syndromes are the anterior and deep posterior compartments of the leg. The most commonly incompletely released compartments are also in the leg.<sup>1</sup>
- c. Passive stretch pain (e.g., ankle dorsiflexion), palpation of muscles for tenseness, and pulse quality. Pressure monitoring by manometer does not diagnose reliably CS in theater, so the diagnosis remains a clinical, not a laboratory, diagnosis. Since there is currently no sensitive or specific technique for establishing the diagnosis of compartment syndrome, a fasciotomy should be considered in a patient with significant mechanism of injury and clinical findings suspicious for compartment syndrome.
- d. When monitoring patients for the development of CS, serial clinical examinations are repeated hourly when risk is high and less frequent when low. Provider experience and training improve detection. Documentation is important for later providers and performance improvement. The methods of manometric monitoring of compartments and the clinically significant thresholds to identify compartment syndrome are, at present, not known. A new manometer drains fluid.
- e. In one study, burns sustained in combat have been associated with an increased fasciotomy rate.<sup>1</sup> **In the absence of crush injury, fracture, multiple trauma, over-resuscitation, electrical injury or similar indications, prophylactic fasciotomies on burned extremities may increase morbidity and mortality and are not indicated.** (For additional information on escharotomy and fasciotomy in the management of patients with extremity burns, see "Burn Care" JTTS CENTCOM CPG, 21 Nov 08).
- f. When established limb compartment syndromes prolonged, complications (mortality, infection) are frequent according to the best evidence available<sup>6</sup>. These casualties may meet indications for resuscitation, urine alkalization, mannitol use, and intensive support. Such conservative care has led to better outcomes than fasciotomy in casualties with closed injuries with mechanically crushed muscle (see Figure 1 and Reis & Better, 2005). So for compartment syndromes that last more than 12 hours (warm ischemia) and the muscle appears to be dead, there may be better outcomes with conservative care than fasciotomy.

**4. Author:** COL John Kragh is the primary author of this CPG.

---

Guideline Only/Not a Substitute for Clinical Judgment

April 2009



## Joint Theater Trauma System Clinical Practice Guideline

---

### 5. References.

- <sup>1</sup> Ritenour AE, Dorlac WC, Fang R, et al. Complications after fasciotomy revision and delayed compartment release in combat patients. *J Trauma*. 2008;64(2 Suppl):S153-61; discussion S161-2. Landstuhl cohort. Inadequate fasciotomy risks mortality. Surgeons should have this.
- <sup>2</sup> Mubarak SJ, Hargens AR. Compartment Syndromes and Volkmann's Contracture. Saunders, Philadelphia, 1981. First book on compartment syndrome, a dated classic.
- <sup>3</sup> US Army, Medical Research and Materiel Command. Compartment Syndrome: Diagnosis and Surgical Management DVD, 2008. 90 minutes, how to do surgery.
- <sup>4</sup> Office of The US Army Surgeon General, Health Policy and Services (HP&S) Directorate, All Army Action Order, Complications after fasciotomy revision and delayed compartment release in combat patients. 15 May 2007. Ritenour message.
- <sup>5</sup> Klenerman L. The Tourniquet Manual. London: Springer; 2003. The only book on tourniquets which increase the risk of compartment syndrome somewhat especially if used incorrectly such as a venous tourniquet.
- <sup>6</sup> Reis ND. Better OS. Mechanical muscle-crush injury and acute muscle-crush compartment syndrome : with special reference to earthquake casualties. *J Bone Joint Surg Br*. 87(4) :450-3, 2005. Late fasciotomy risks infection and mortality.
- <sup>7</sup> Walters TJ, Kragh JF, Kauvar DS, Baer DG. The combined influence of hemorrhage and tourniquet application on the recovery of muscle function in rats. *J Orthop Trauma*. 22(1) :47-51, 2008. Risk factors are interrelated.

Approved by CENTCOM JTTS Director, JTS Director  
and Deputy Director and CENTCOM SG

---

Guideline Only/Not a Substitute for Clinical Judgment

April 2009

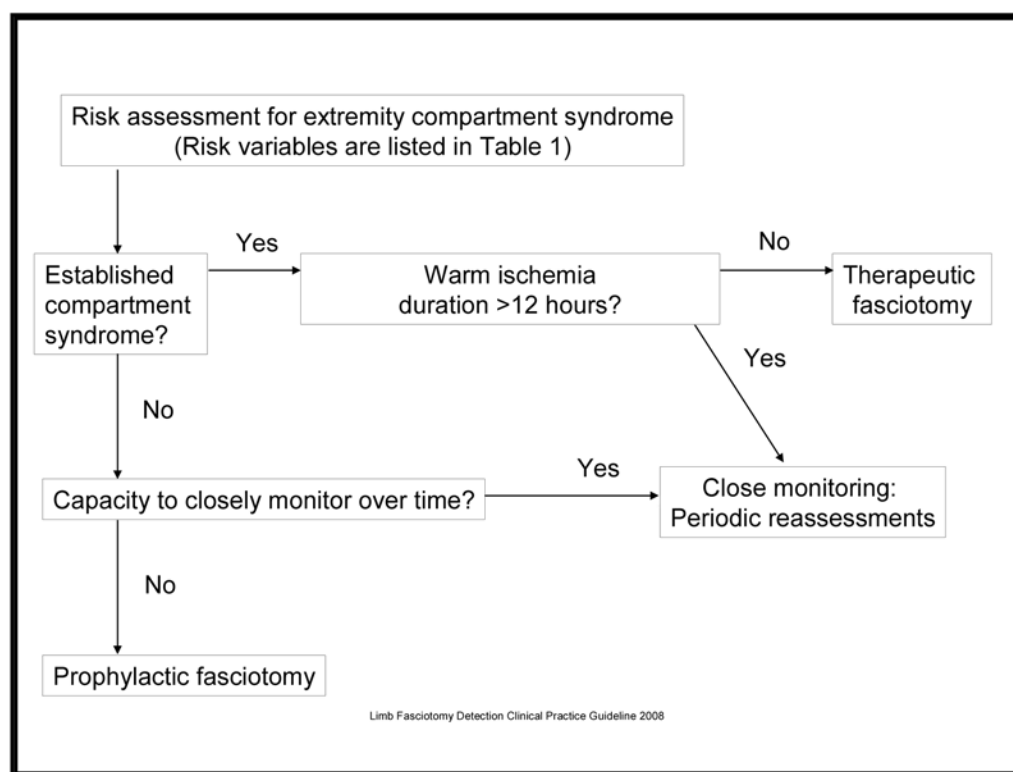
**APPENDIX A**  
**TABLES & FIGURES**

<b>Table 1.</b> <b>Risks for Acute Traumatic Compartment Syndrome*</b>	
Decreased Compartment Volume	Tight cast or dressing, closure of prior fasciotomy, excess traction
	External limb compression or crush particularly in obtunded or incapacitated casualty
	Frostbite, burns or electric injury (may include escharotomy)
Increased Compartment Contents	Edema accumulation: embolism, intravascular thrombosis, replantation, venous tourniquet, injections, extravasation, infiltration, ergotamine ingestion ischemia-reperfusion, swelling, artery injury or spasm, revascularization procedures, prolonged arterial tourniquet use, shock hypoperfusion, angiography and catheterization, limbs positioned well above heart, mal-positioned joints (ankle dorsiflexion,) or stretched muscles
	Prolonged immobilization and limb compression particularly with obtunded or drugged casualty, some surgical positioning
	Hemorrhage, hemophilia, coagulopathy, anticoagulation, vessel injury
	Fractures particularly tibia fractures in adults, supracondylar humerus fractures in children displaced, comminuted, or open fractures increase hemorrhage, swelling, and CS risk
	Popliteal cyst, long leg brace
<i>*Modified from reference 2</i>	

---

Guideline Only/Not a Substitute for Clinical Judgment

April 2009



**Figure 1.**  
**Algorithm for Clinical Decision Making**  
**on Compartment Syndrome in a Deployed Setting**

Table 2. Healthcare Record Data in the Setting of Compartment Syndrome During War
Was the fasciotomy prophylactic (compartment syndrome absent) or therapeutic (compartment syndrome present)?
When was the fasciotomy indicated and when was the injury? When was the procedure (to determine treatment lag)?
Was the casualty able to be followed closely? If so, what was the clinical course? Was the casualty alert, intubated, or head injured?
Was there a nerve injury or nerve block/regional anesthetic?
What was the injury or risk factors, e.g., ischemia-reperfusion, that indicated the procedure?

Guideline Only/Not a Substitute for Clinical Judgment

April 2009

## Joint Theater Trauma System Clinical Practice Guideline

**Table 2. (continued)**  
**Healthcare Record Data in the Setting of**  
**Compartment Syndrome During War**

What are the sources of ischemia-reperfusion in the injury and care of this case?
Associated injuries altering risk of compartment syndrome: shock, occult hypoperfusion, hypoxia, nerve dysfunction, impaired, obtunded, or uncooperative casualty, arterial injury or ischemia, fractures with soft tissue injury, over-resuscitation syndrome, coagulopathies (including hemophilia, etc.), hematoma formation, crush injury, capillary leak syndrome, and prolonged compression.
What were the surgical findings and muscle compartment response to the procedure?
What was the technique (dermotomy, fasciotomy, surgical approach, length of fasciotomy)?
Was there retinaculotomy or epimysiotomy? List names of all compartments released.
What delimited the fasciotomy extent, e.g., anterior leg fascia goes from the proximal tibial crest near Gerdy's tubercle to the anterior ankle extensor retinaculum (crural ligament)?
List associated procedures: debridement, irrigation, fracture fixation, etc.
Planned care: staged? Closure, repeat debridement, delayed primary, skin graft, or flap.

**Table 3.**  
**Morbidity Risk and Sequelae**  
**of Compartment Syndrome and Fasciotomy**

Potential Morbidity: Compartment Syndrome and Early Fasciotomy	skin scar, scaly skin, ulceration, tethered tendons
	postoperative arterial or graft thrombosis, thromboembolic disease
	wound infection, nonhealing fasciotomy wounds
	limb swelling or chronic edema, shape change of limb, muscle hernia
	pain, paresis or paralysis, paresthesia
	coverage challenge: primary closure, delayed primary closure, skin graft, flap

Guideline Only/Not a Substitute for Clinical Judgment

April 2009



## Joint Theater Trauma System Clinical Practice Guideline

**Table 3. (continued)**  
**Morbidity Risk and Sequelae**  
**of Compartment Syndrome and Fasciotomy**

	possible repair of arterial injury worsening ischemia-reperfusion injury
Potential Sequelae List: Compartment Syndrome with Late or Incomplete Fasciotomy	mortality, sepsis, multi-organ failure, acute kidney failure
	myonecrosis, myoglobinemia, myoglobinuria, or rhabdomyolysis
	paresis or paralysis
	stiffness or contracture
	limb amputation, tissue loss, e.g., muscle debridement

**Table 4.**  
**Data Sheet: Compartment Names, Main Muscles, and Diagnosis and Procedure Codes**

Compartment	Main muscle(s)	Left or Right	Wound Notes, Compartment Syndrome (CS), Diagnoses, Indications, & Findings	Procedure(s) and Tissue Response to Procedure
			958.91: traumatic CS of upper extremity 958.92: traumatic CS of lower extremity 958.99: traumatic CS of other sites 958.90: CS, unspecified Prophylactic (CS absent) or therapeutic (CS present) Artery, vein, clot, & hematoma findings in compartment on exploration	83.12: fasciotomy of hand 83.14: fasciotomy, division of fascia 83.09: incision of fascia 86.09: escharotomy dermotomy, epimysiotomy Response: muscles bulged through fasciotomy, no bulge, pulse returned after absence
Deltoid	deltoid			
Arm, Anterior	biceps, brachialis			

Guideline Only/Not a Substitute for Clinical Judgment

April 2009

## Joint Theater Trauma System Clinical Practice Guideline

<b>Table 4. (continued)</b> <b>Data Sheet: Compartment Names, Main Muscles, and Diagnosis and Procedure Codes</b>				
<b>Compartment</b>	<b>Main muscle(s)</b>	<b>Left or Right</b>	<b>Wound Notes, Compartment Syndrome (CS), Diagnoses, Indications, &amp; Findings</b>	<b>Procedure(s) and Tissue Response to Procedure</b>
Arm, Posterior	triceps			
Forearm, volar	flexors			
Forearm, dorsal	extensors			
Forearm, mobile wad	brachioradialis			
Hand, interossei	interossei			
Hand, central palmar	flexors			
Hand, hypothenar	digiti minimi			
Hand, thenar	thumb muscles			
Gluteus maximus	gluteus maximus			
Gluteus medius	other glutei			
Tensor fascia lata	tensor			
Thigh, anterior	quadriceps			
Thigh, posterior	hamstrings			
Thigh, adductor	adductors			
Leg, anterior	tibialis anterior			
Leg, lateral	peronei			
Leg, deep posterior	tibialis posterior			
Leg, superficial	gastrocnemius			

Guideline Only/Not a Substitute for Clinical Judgment

April 2009

## Joint Theater Trauma System Clinical Practice Guideline

<b>Table 4. (continued)</b> <b>Data Sheet: Compartment Names, Main Muscles, and Diagnosis and Procedure Codes</b>				
<b>Compartment</b>	<b>Main muscle(s)</b>	<b>Left or Right</b>	<b>Wound Notes, Compartment Syndrome (CS), Diagnoses, Indications, &amp; Findings</b>	<b>Procedure(s) and Tissue Response to Procedure</b>
posterior				
Foot, interossei	interossei			
Foot, central	flexors			
Foot, lateral	digiti minimi			
Foot, medial	great toe muscles			
Iliacus	iliacus, psoas			

<b>Table 5.</b> <b>Operative Note Template for Dictation, Surgical Planning, or Data Collection</b>	
<sup>1</sup> Patient	<sup>2</sup> Surgeon
<sup>3</sup> Date of Surgery	<sup>4</sup> Anesthesia
<sup>5</sup> EBL:	<sup>6</sup> Tubes
<sup>7</sup> Specimens	<sup>8</sup> Complications
<sup>9</sup> Implants, Devices	
<sup>10</sup> <u>Indication for operation:</u> established compartment syndrome (therapeutic) risk of compartment syndrome developing (prophylactic)	
<sup>11</sup> <u>Preoperative wound appearance:</u> size (volume of damaged tissue: large surgeon hand ~500ml) depth, location, contamination material or matter	
<sup>12</sup> <u>Preoperative imaging findings:</u> soft tissue injury seen & fracture	

Guideline Only/Not a Substitute for Clinical Judgment

April 2009

## Joint Theater Trauma System Clinical Practice Guideline

<b>Table 5. (continued)</b>	
<b>Operative Note Template for Dictation, Surgical Planning, or Data Collection</b>	
13.	<u>Examination under anesthesia, fluoroscopy, and surgical exploration findings:</u> distal pulse status wound size, depth, location, contamination, materials or matter; burn eschar location and depth vessel status, pulse, limb perfusion, capillary refill, congestion, edema, color of skin, warmth clot presence, intravascular or extra vascular site, size (volume), location hematoma presence compartment hardness: soft, hard epimysiotomy (if done by muscle name or compartment if known) retinaculotomy (if done by name, e.g., partial proximal ankle extensor retinaculotomy extended from anterior leg compartment fasciotomy result of fasciotomy and procedure (distal perfusion and pulse; gap in fasciotomy edges on release in cm; bulging out of muscles in compartment) compartments soft or hard muscle color, consistency, contractility, capacity to bleed
14.	<u>Patient condition, status, disposition and plan:</u>
15.	<u>Key note for air evacuation: "Patient has been monitored for X hours after injury/surgery and has not had progression of signs or symptoms of compartment syndrome."</u>

Guideline Only/Not a Substitute for Clinical Judgment

April 2009



# Glossary and Classification of Amputations

### *Mechanism*

- Traumatic amputations are injuries, not procedures.

### *Timing of amputation procedure*

- Originally, the use of primary, secondary, and intermediate amputation dealt with the timing of sup-puration, but recently the usage of primary has generally meant early and secondary meant late.
- Primary amputation is a procedure done at the first surgery; it means the same as a debridement amputation or completion amputation (terms which are less specific). Synchronous amputations: multiple amputations when occurring simultaneously as when two or more operative teams work together on different limbs.

### *Degree of amputation (limb transection)*

- Partial (or subtotal) traumatic amputation is preferable to near complete amputation since complete traumatic amputation is confusable with completion amputation which is a procedure. Total traumatic amputation is preferable to complete traumatic amputation.
- Open traumatic amputation is the norm, but closed traumatic amputations occur rarely while involving disruption of most of the limb yet have intact skin.
- Site of major amputation
- On physical examination before the results of the radiographs are available, providers can simply use the word 'about' (as in 'amputation about the knee') instead of speculating what exactly the amputation site may be.
- Trans-pelvic
- Through the hip
- Transfemoral is preferable to above knee which is less specific
- Through the knee
- Transtibial is preferable to below knee which is less specific.
- Through the ankle
- Fore quarter (interscapulothoracic)
- Hind quarter (interilioabdominal or internominoabdominal)
- Major amputation: amputation of upper extremity proximal to the wrist and lower extremity proximal to the ankle ('proximal' is more precise than 'above').
- Minor amputation: amputation of the smaller parts such as fingers, toes, hands or feet.

### *Number of limbs*

- Single amputation: amputation of one limb only
- Double amputation: amputation of two limbs
- Triple amputation: amputation of three limbs
- Quadruple amputation: amputation of four limbs

### *Surgical Technique*

- The 'guillotine amputation' technique was a rapid procedure that was done with a circular sweep of the knife and cut of the saw through bone transverse to the long axis of the limb with the cross-section being left open when the primary closure was not indicated. The guillotine amputation label

was later superseded by the open circular amputation which actually permitted the different tissue cuts to be at different levels. The current preferred term is open, length-preserving amputation in order to emphasize the principle of preserving the maximum distal tissue as practical instead of following an arbitrary or transverse direction that wastes normal tissue.

## Joint Theater Trauma System Clinical Practice Guideline

### IRRIGATION OF WAR WOUNDS: Wound Debridement, Washout and Irrigation

Original Release/Approval	2 Oct 2006	Note: This CPG requires an annual review.	
Reviewed:	Apr 2009	Approved:	6 May 2009
Supersedes:	Irrigation of War Wounds, 19 Nov 2008		
<input checked="" type="checkbox"/> Minor Changes (or)	<input type="checkbox"/> Changes are substantial and require a thorough reading of this CPG (or)		
<input type="checkbox"/> Significant Changes			

**1. Goal:** To review indications for and the procedures associated with battle related wound debridement, washout, and irrigation.

**2. Background.** Wound debridement, washout and irrigation are the surgical procedures most performed in the combat theater. Given the power of today's munitions, prompt removal of devitalized tissue, debris, blood and bacteria is imperative not only to prevent local wound complications, but also may decrease the incidence of systemic effects associated with such wounds. **While the degree of initial debridement is left to the operating surgeon, care must be given to ensuring all devitalized tissue is removed while at the same time attempting to preserve as much soft tissue as possible for reconstructive surgery at higher echelons of care. This is best accomplished via serial debridement and washouts.** Though high pressure pulsatile lavage devices (HPPL) are used extensively in civilian institutions, they should not be used in the combat theater as they may contribute to increased tissue damage and result in a rebound increase in bacterial load, as opposed to that seen with the simple bulb syringe method of washout and irrigation.<sup>1</sup>

**3. Evaluation and Treatment.**

- a. **Devices:** **Simple bulb irrigation or gravity irrigation is the preferred method for wound washout and irrigation.** In addition, the bulb and syringe method is more widely available and is significantly less expensive. Large bore gravity-run tubing is the suggested choice for a quick method of irrigation, since it accepts two bags at once, yet still gentle in nature. Example of the large bore tubing is Baxter's Y-Type TUR Irrigation Set, used for urologic cystoscopy, 2C4005, Deerfield, IL: NSN 3218654401; UI 20/case.
- b. **Fluids:** Current research demonstrates that normal saline, sterile water and potable tap water have similar usefulness, efficacy and safety. Sterile isotonic solutions are readily available and remain the fluid of choice for washout and irrigation. If unavailable, sterile water or potable tap water can be used.<sup>2</sup>
- c. **Volume:** Bacterial loads drop logarithmically with increasing volumes of 1, 3, 6, and 9 liters of irrigation. Sufficient volumes should be utilized to remove all visible debris. The current recommendations are as follows: 1-3 liters for small volume wounds, 4-8 liters for moderate wounds, and 9 or more liters for large wounds or wounds with evidence of heavy contamination.

Guideline Only/Not a Substitute for Clinical Judgment

May 2009

## Joint Theater Trauma System Clinical Practice Guideline

---

- d. Timing of debridement and irrigation: Early wound irrigation facilitates the ability to decrease bacterial load.<sup>3</sup> Wounds should undergo debridement and irrigation as soon as feasible after life threatening injury. **Depending on the nature of the wound and the degree of contamination, all battle-related wounds should be washed out at least once every 48 hours.** Obviously, those wounds with more significant contamination will require more frequent washouts, and strong consideration should be given to performing a washout in the period just prior to aeromedical evacuation.
  - e. Closure: **Though no hard and fast rules exist for the closure of battle injuries, experience over the last seven years indicates that if the wound was caused by some form of munitions or battle-related trauma, it should initially be left open and allowed to heal by secondary intention or undergo delayed primary closure after several evaluations.**
4. **Responsibilities:** It is the trauma team leader's responsibility to ensure compliance with CPG adherence.
5. **References:**
- <sup>1</sup> Svoboda SJ, Bice TG, Gooden HA, et al. Comparison of bulb syringe and pulsed lavage irrigation with use of bioluminescent musculoskeletal wound model. *J Bone Joint Surg Am* 2006; 88(10): 2167-74
  - <sup>2</sup> Owens, BD, White DW, Wenke JC. Comparison of irrigation solutions and devices in a contaminated musculoskeletal wound survival model. *J Bone Joint Surg Am* 2009; 91 (1): 92-8.
  - <sup>3</sup> Owens, BD, Wenke JC. Early wound irrigation improves the ability to remove bacteria. *J Bone Joint Surg Am* 2007; 89 (8): 1723-6
  - <sup>4</sup> *Emergency War Surgery Handbook*, 3<sup>rd</sup> US Revision, 2004.

Approved by CENTCOM JTTS Director, JTS Director  
and Deputy Director and CENTCOM SG

---

Guideline Only/Not a Substitute for Clinical Judgment

May 2009

Page 2 of 2

Irrigation of War Wounds: Wound Debridement, Washout and Irrigation