

Appendix

PICTORIAL ATLAS OF FREEZING COLD INJURY

WILLIAM J. MILLS, JR., MD*

HISTORY OF AND INTRODUCTION TO FREEZING COLD INJURY

METHODS OF THAWING

TREATMENT AFTER THAWING

PROGNOSIS

Best

Uncertain

Poor

SURGICAL PROCEDURES


UNUSUAL PRESENTATIONS

SEQUELAE OF FREEZING COLD INJURY

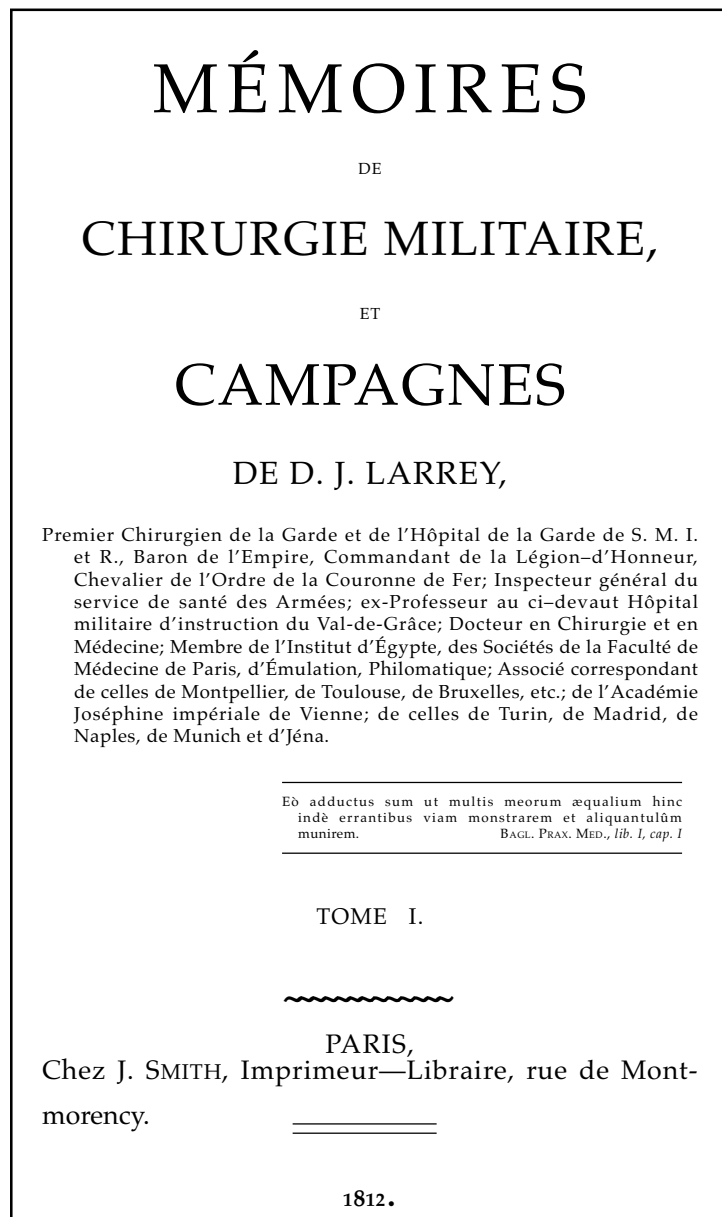
SPACE-AGE THERMAL INJURIES

*Rear Admiral, Medical Corps, US Navy (Ret); 1544 Hidden Lane, Anchorage, Alaska 99501

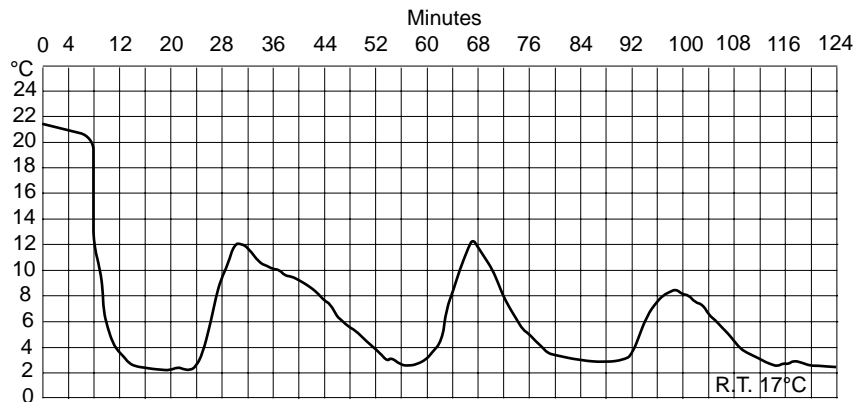
HISTORY OF AND INTRODUCTION TO FREEZING COLD INJURY



Atlas Fig. 1. (a) One of history's oldest written accounts of an army decimated by cold was that of Xenophon, who in 400 BC led 10,000 Greek soldiers from Sardis to Babylon and back, through the mountains of Armenia, battling the hazards a retreating and disorganized army faces when pursued by the combined, unrelenting foes of severe cold weather and harassing enemy forces. Warmth was obtained by campfire heat; friction; massage of the body parts with greases, oils, and unguents; and preservation of heat by covering up in snow. Amputation and death from exposure were common. (b) As this chart from Xenophon's account shows, the course of his army was not far from the ancient city of Babylon, quite near the city of Baghdad, the present-day capital of Iraq. Pursuit of the 1991 Persian Gulf War past Baghdad into the mountains of Kurdistan and the ancient trail of Xenophon's Greek army might have brought US troops into a winter war that would have required quite different preparation. Reproduced from Xenophon. *The Expedition of Cyrus Into Persia, and the Retreat of Ten Thousand Greeks, 400 BC.* Spelman E, trans. 2 vols. London, England: D. Brown; 1749.



Atlas Fig. 2. A detailed, factual, and vivid description of the effects of cold on a retreating army was documented by Baron Dominique-Jean Larrey, the chief surgeon of Napoleon's Grande Armée in the retreat from Moscow in 1812/13. Larrey's *Mémoires de Chirurgie Militaire et Campagnes* gave precise description of freezing injury and its etiology, including data on general body cooling. He recommended slow rewarming, or delayed warming with ice and snow techniques, and friction massage, all out of favor now although accepted for more than 150 years after his reports. The monograph is replete with the problems of prevention and care involving massive numbers of troops, in an army in which more than 80% of its force perished from cold and cold-related problems. Much can still be gained by a study of this classic. Larrey disapproved of rapid rewarming, and his words discouraged the use of rapid thawing until the latter half of the 20th century. He did note the disastrous effect of excessive heat, apparently recognizing that frozen extremities, warmed in the close proximity of bivouac fires, sustained a second thermal injury, a burn, with disastrous effect. For the student of freezing injury, this monograph is highly recommended.

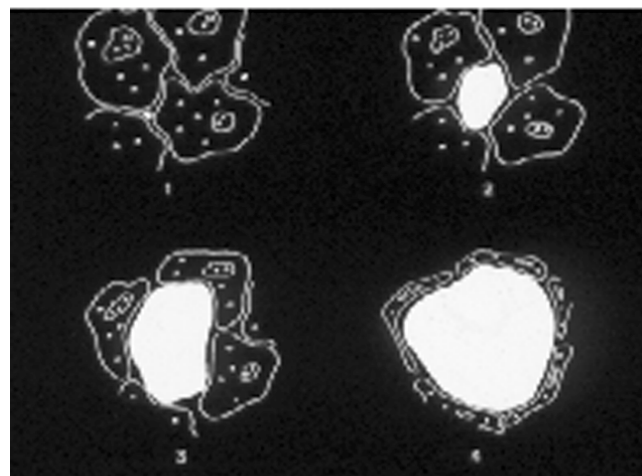


Atlas Fig. 3. Peripheral temperature curve of a finger immersed in ice water, demonstrating the “rise and fall” response, gradually decreasing, which is known as the “hunting response of Lewis.” The ice water was unstirred; the room temperature was 17°C. Reprinted with permission from Lewis T. Observations upon the reactions of the vessels of the human skin to cold. *Heart*. 1930;15:183.

Atlas Fig. 4. By definition, frostbite is a result of heat loss sufficient to permit ice formation in the superficial or deep tissues. According to H. T. Meryman, one of America’s premier cryobiologists:

The single most important and fundamental concept in biological freezing is that regardless of the mysterious complexity of the biological matrix, freezing represents nothing more than the removal of pure water from solution and its isolation into biologically inert foreign bodies, the ice crystals.¹

In Meryman’s representation of the freezing process in tissue, (1) some “substance” in the fluid of the extracellular space permits a nucleus of ice to form. (2) The extracellular solution has been concentrated from freezing and the resultant high osmotic pressure in the extracellular fluid draws intracellular water through the cell membrane. (3 and 4) The continuous growth of extracellular ice permits mechanical pressure to be exerted on cells, compressing them. This results in progressive cell dehydration, a condition more damaging to the cell membrane than the mechanical effect of the ice crystals. Quotation: (1) Meryman HT. Mechanics of freezing in living cells and tissues. *Science*. 1956;Sep 21:124. Drawing: Reprinted with permission from Meryman HT. Preservation of living cells. *Federation Proc*. 1963;22:82.



ATLAS EXHIBIT 1
TYPES OF FREEZING INJURY

- Frostbite, superficial to deep
- Mixed injury (immersion followed by freezing)
- Freeze–thaw–refreeze
- High altitude, hypoxia, freezing
- Compartment compression and freezing
- Extremity fracture and freezing
- Freezing injury superimposed on severe hypothermia
- Hypothermia following any form of cold injury (trench foot, immersion injury, frostbite)

ATLAS EXHIBIT 2

CELLULAR RESPONSE TO FREEZING AND THAWING

During Freezing

1. Growth of ice crystals damages cell structure
2. Electrolyte concentration causes protein denaturation
3. Intracellular and extracellular pH becomes more acidotic
4. Cells dehydrate
5. Protein-bound water decreases

During Freezing and Thawing

6. Cell membranes rupture
7. Intracellular organs are damaged
8. Cell membrane permeability is abnormal
9. Essential enzymes are destroyed
10. Microscopic damage occurs to capillaries
11. Arterial and venous walls are injured
12. Mitochondrial damage to muscle cells is consistent

ATLAS EXHIBIT 3

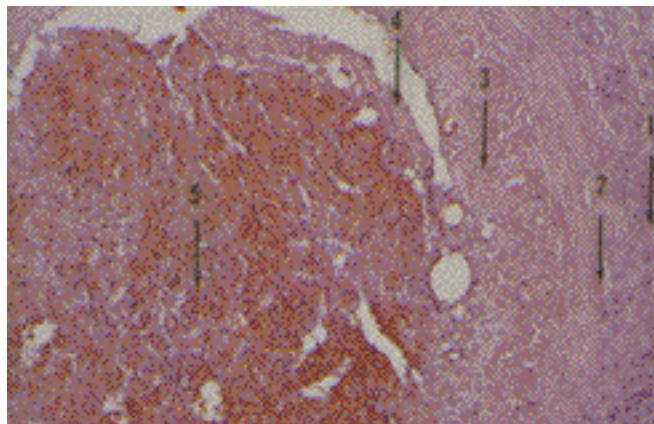
VASCULAR CHANGES DURING AND AFTER THAWING

Vascular Changes During and Soon After the Thaw

1. Circulatory stasis
2. Corpuscular aggregation
3. Venule and arterial obstruction
4. Red blood cells pile up back to the capillary bed
5. Hyaline plugs develop in the vascular tree
6. Progressive dermal ischemia, which is worsened by (or perhaps a component of which may be caused by) the activation of the arachadonic acid cascade

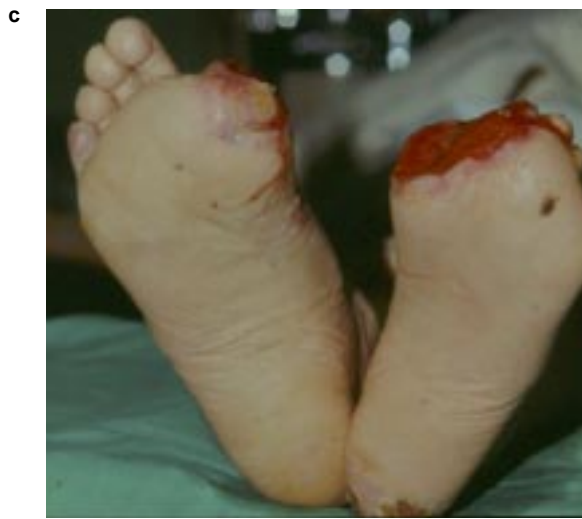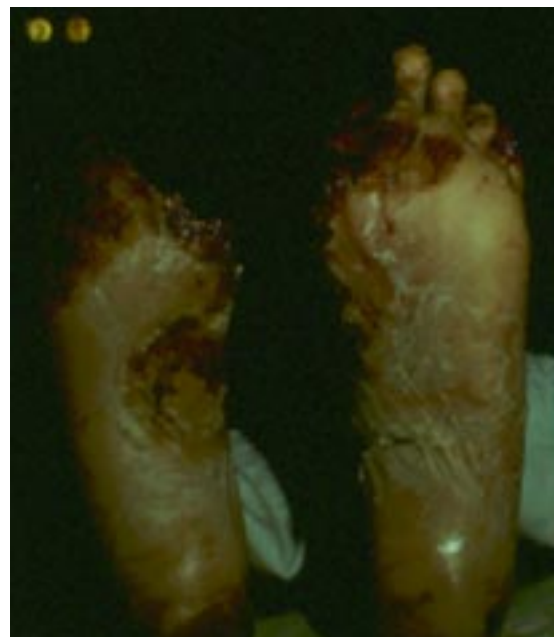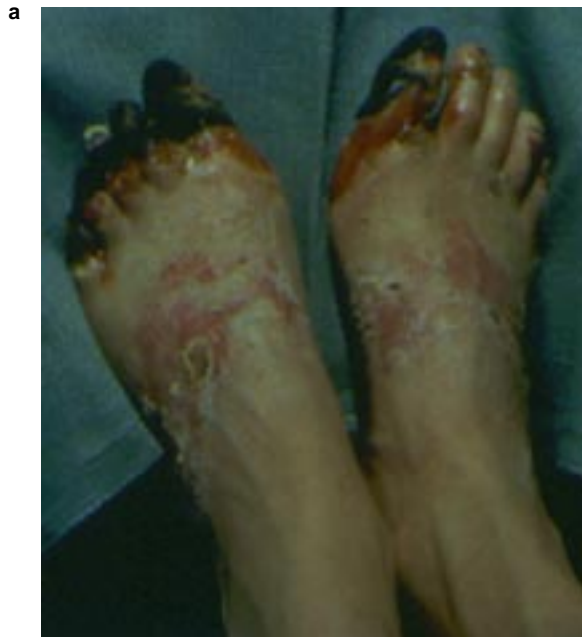Vascular Changes After the Thaw

7. Marked tissue edema
8. Anoxia and ischemia of tissues
9. Increased tissue compartment pressure
10. Capillary and peripheral vessel collapse
11. Thrombosis, ischemia, necrosis, gangrene

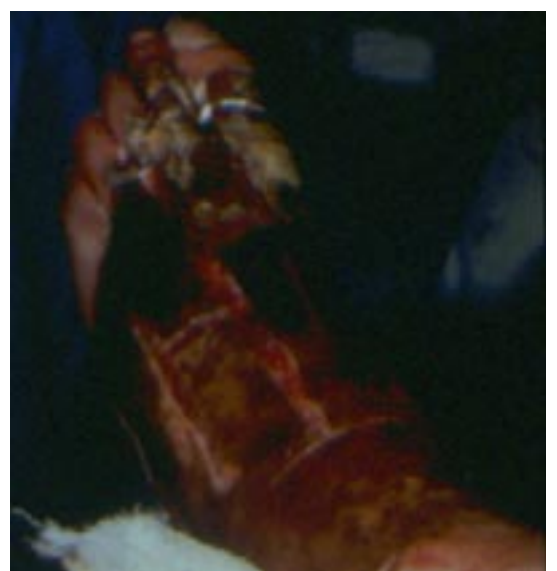
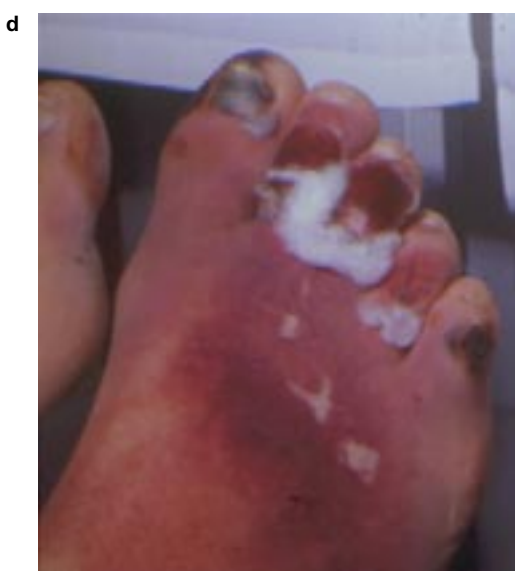
Atlas Fig. 5. Long-standing wet-cold exposure, followed by freezing. This section of a small peripheral artery of the foot shows (1) adventitia demonstrating nonspecific inflammation; (2) tunica media with less obvious inflammation, with spindle-shaped muscle fibers; (3) thickened intima and circumferential muscle fibers; (4) endothelial disruption growing into a luminal clot, with endothelialization of thrombus; and (5) an intraluminal clot being organized, with ingrowth of fibroblasts and capillaries. This pathological pattern may be found in freezing as well as peripheral nonfreezing injury. The endothelial cell and its lining are sensitive to, and early targets of, low temperatures.

Unless otherwise noted all figures are from the professional collection of William J. Mills, Jr., MD. Some of these illustrations have also been published in *Alaska Medicine*.



Atlas Fig. 6. Freezing injuries can be complicated by pre-existing conditions or subsequent injuries. Serial photographs (a–c) of a 64-year-old man whose feet were frozen while on a snowmachine trip near Nome, Alaska. Exposure: 3 days; ambient temperature: below 0°F. Frostbite of toes, and what appeared to be minimal superficial frostbite of the heels. The patient had a history of anemia and lower-leg peripheral neuropathy. His injury presumably was a mild freeze–thaw–refreeze injury in the field. (d) The frozen right foot of another patient, a fisherman with diabetes mellitus and small-vessel disease; his foot thawed spontaneously aboard ship. Eventually, because of small-vessel occlusion, a metatarsal amputation was performed. (e) A burn injury followed by a freezing injury, or a freezing injury followed by a burn injury, often results in irreparable changes, usually due to severe vessel thrombosis.



METHODS OF THAWING

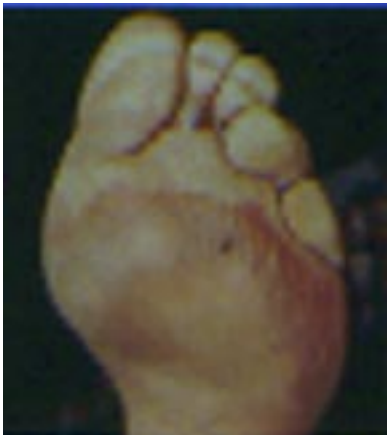ATLAS EXHIBIT 4

METHODS OF THAWING

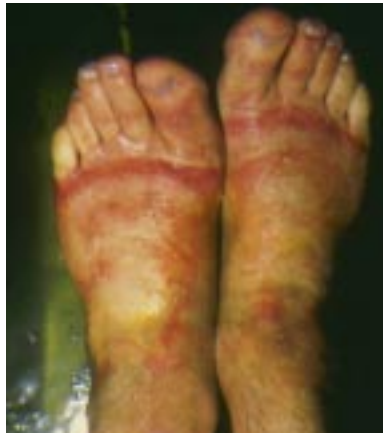In *decreasing* order of effectiveness, the following methods of thawing are utilized by rescuers, the freezing victims themselves, and even medical personnel:

1. Rapid rewarming in water, 32.2°C to 41.1°C (90°F–106°F). (Use a tub, a whirlpool bath, or a Crane lift platform in a Hubbard tub.)
2. Spontaneous thawing at room temperature, in cabin heat, during foot travel or rescue, or in sleeping bag.
3. Delayed thawing, using ice and snow techniques, cold water, or friction massage.
4. Thawing by excessive heat, such as that from a camp fire, oven, or engine exhaust (> 48.4°C, or > 120°F).

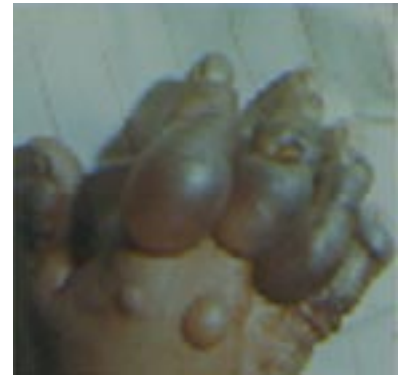a



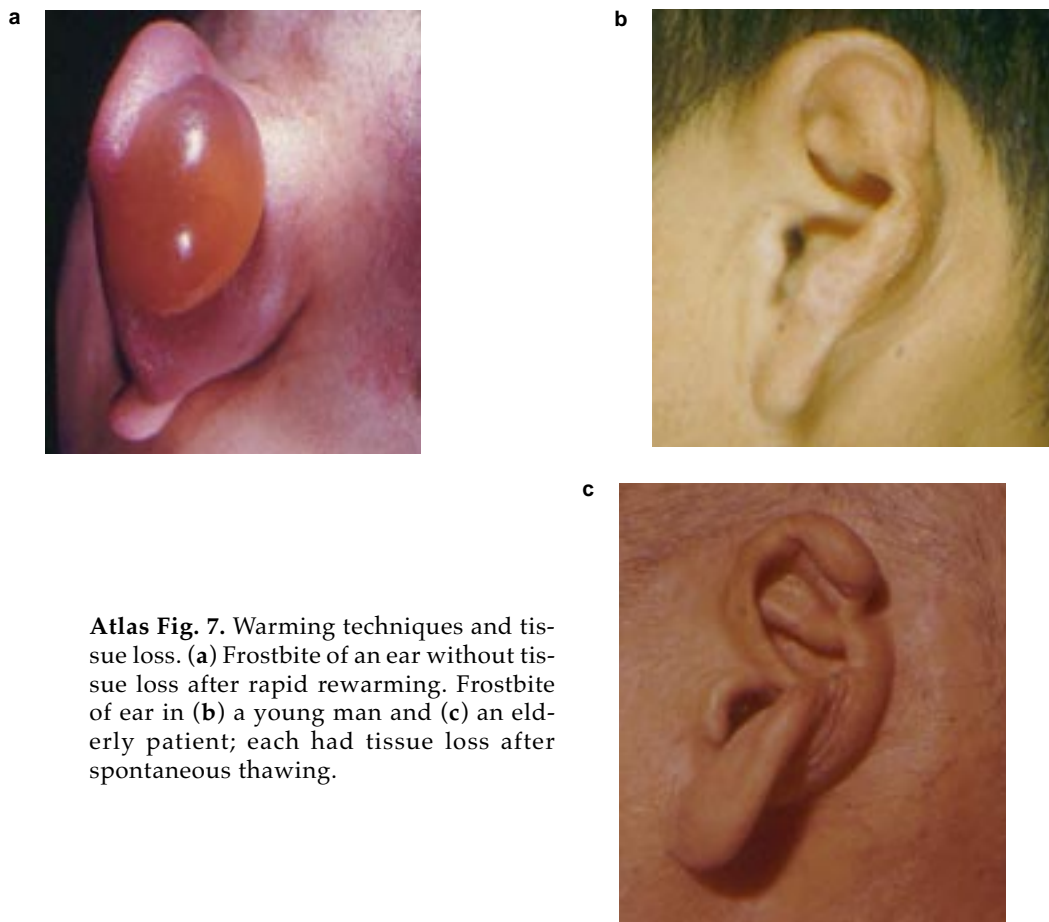
b



c

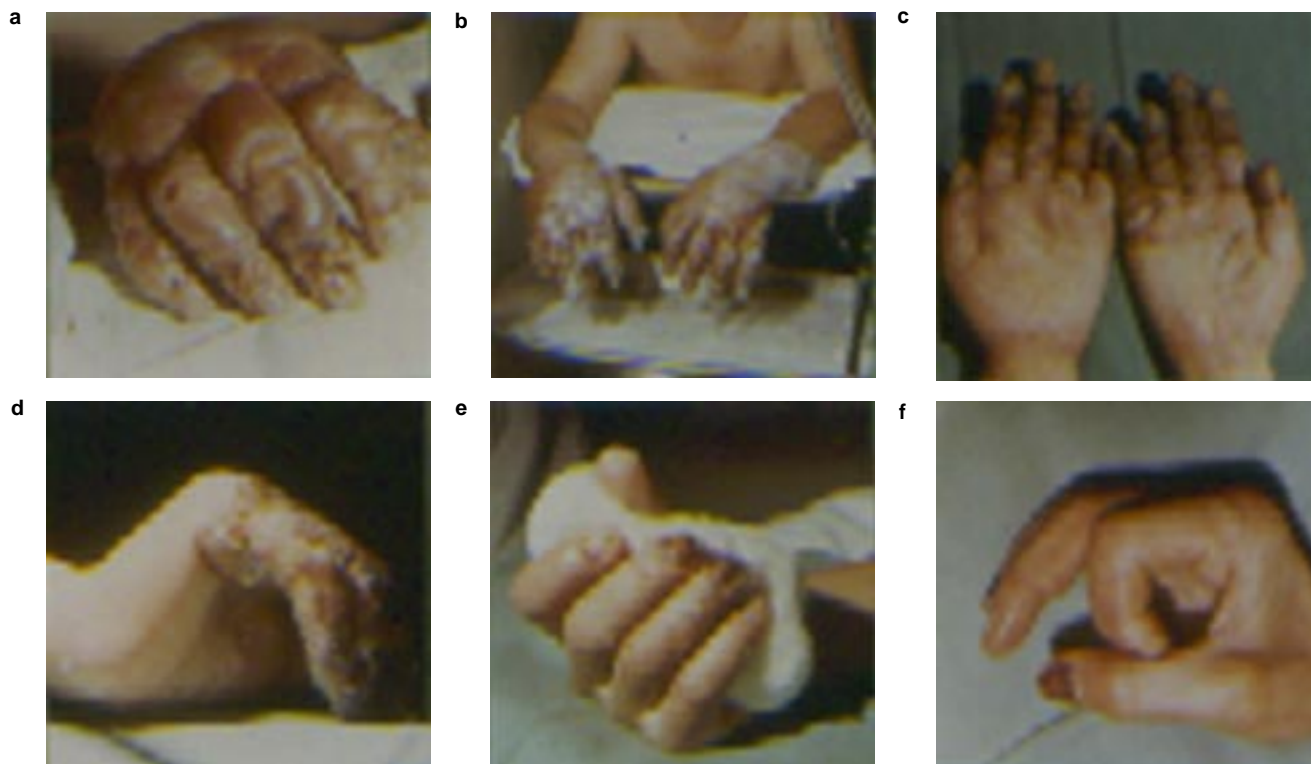


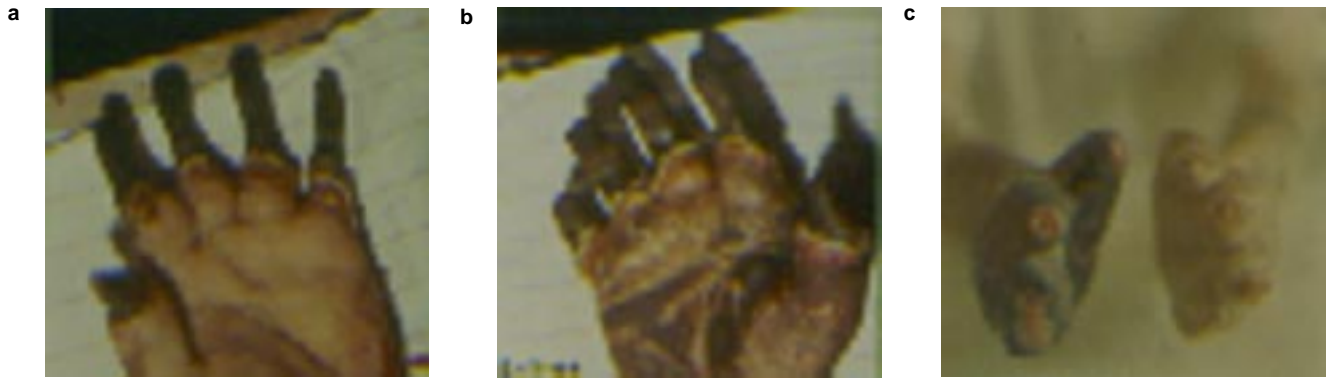Atlas Exhibit Fig. (a and b) Before thawing, the clinical appearance of the frozen part is cold, white, or bloodless. The outer shell of skin is rigid, and the depth of freezing is difficult to determine. (c) After rapid thawing, the part is flushed red or pink, or has a violaceous hue. Blebs appear 1 to 24 hours after the thaw and rupture spontaneously in 4 to 10 days. The castlike eschar forms after the blebs rupture, and the eschar sheds after 21 to 30 days.



Atlas Fig. 7. Warming techniques and tissue loss. (a) Frostbite of an ear without tissue loss after rapid rewarming. Frostbite of ear in (b) a young man and (c) an elderly patient; each had tissue loss after spontaneous thawing.

Atlas Fig. 8.





Atlas Fig. 9. Spontaneous thawing in a cabin. A trapper, hands frozen after losing his gloves, thawed spontaneously in his cold cabin until found 3 weeks later by a friend. (a and b) Third week, left and right hands. Demarcation of tissue has already occurred. (c) Fifth week. Silver nitrate (Moyer's solution) was used on the right hand because of pain and infection. (d and e) Tenth week. The patient was eventually discharged after distal proximal phalangeal amputations but still demonstrates gross hand function. The results of spontaneous thawing vary, due in part to the wide range of temperatures found in cabins, homes, and hospitals.

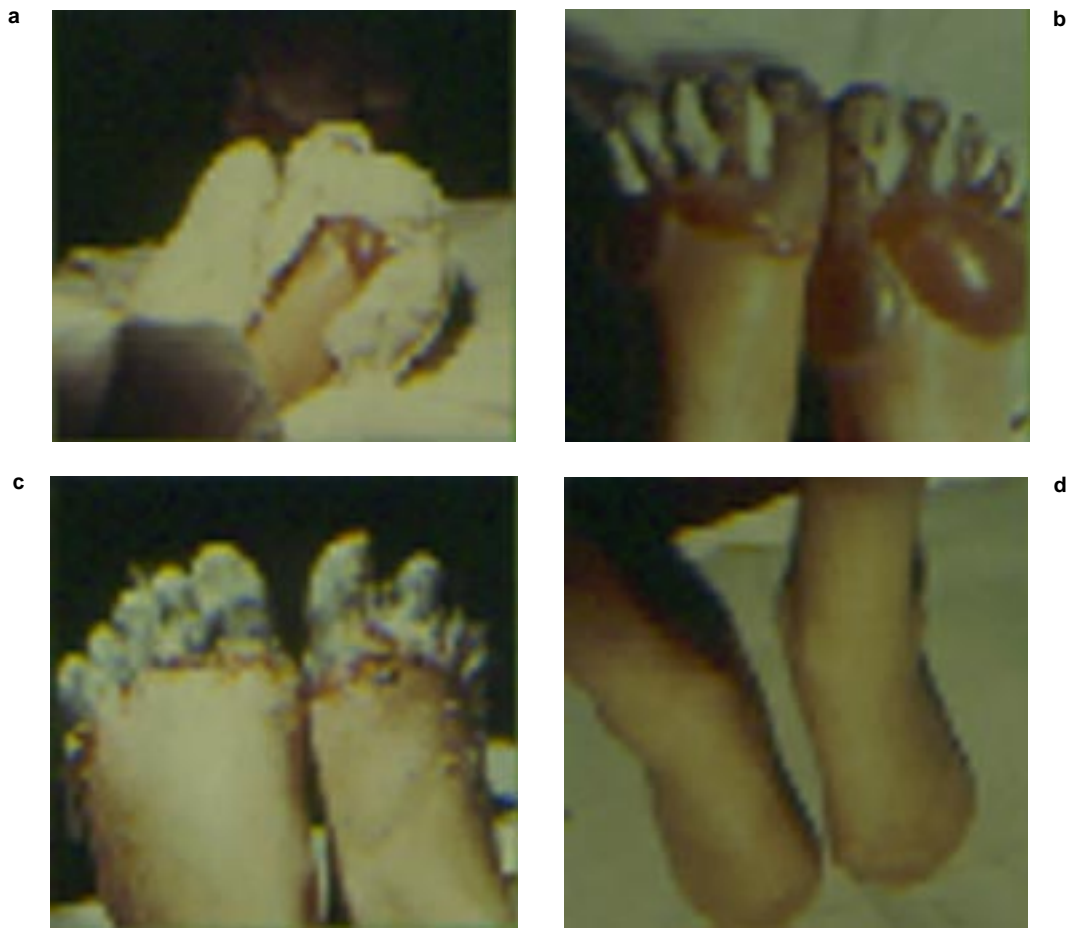

Atlas Fig. 8. Rapid rewarming in a water bath at 42°C (108°F). (a) First day. The patient sustained freezing of hands and feet on the Arctic Slope when marooned in the open as a result of a vehicle accident. Winds were 80 knots, ambient temperature between -20°C and -26°C. The patient lost his overboots and gloves in the accident. His entire exposure time, he states, was 15 to 20 minutes, followed by 45 minutes in the wrecked vehicle awaiting rescue. On rescue, he was warmed in water at 42°C (160°F); the warming and care were directed by radio from Anchorage, Alaska. The patient was then transferred from the Arctic Ocean shore to Anchorage by air travel at 24 hours. On arrival, the hands demonstrated large, clear, pink blebs extending to fingertips; these are excellent prognostic signs, especially that the blebs are distal and extend to the nailbeds. NOTE: Only after rapid rewarming in warm water is there return of sensation in the fingertips; this remains until blebs appear in the dermis and epidermis and separate those tissues from the deep structures. (b) Fourth day. Constant, twice-daily whirlpool is prescribed with digital exercises, using surgical soaps such as pHisoHex,^{*} Hibiclens,[†] or Betadine.[‡] (c) Twenty-first day. By the third week, epidermal eschar has formed, preventing joint motion. (d) Fourth week. Periodically, when the tissue permits, the eschar is incised to allow joint motion. Escharotomy usually is performed from the 14th to the 31st day. (e) Fifth week. Digital exercises are done at frequent intervals at least four times daily, as with whirlpool and biofeedback training. By this time, loss of volar fat pad and loss of nails have occurred and hypesthesia is resolving. (f) Seventh week. The anatomical result is good, but volar fat pad loss and intrinsic muscle loss are obvious. The patient has considerable atrophy of the first dorsal interosseus, and also of the abductor digiti quinti.

^{*}hexachlorophene detergent cleanser; mfg: Sinofi Winthrop Pharmaceuticals, New York, NY

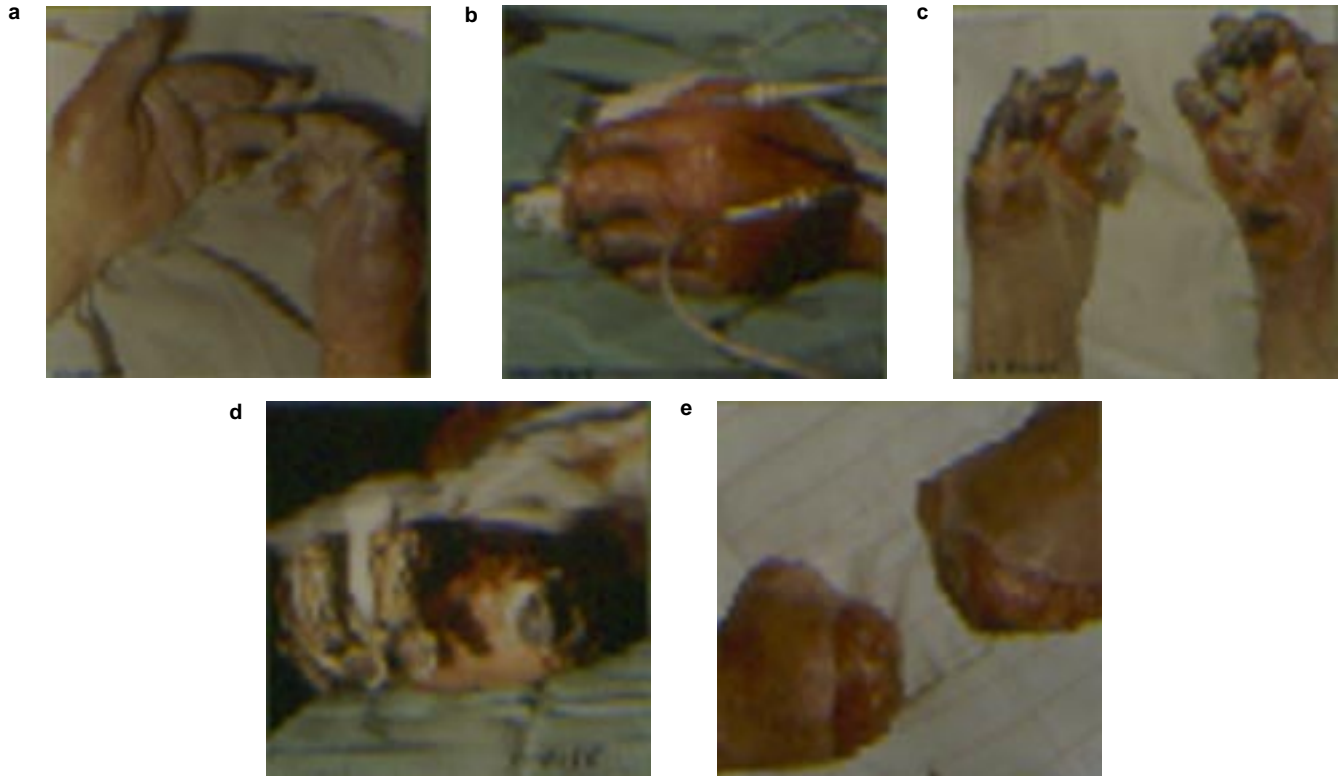
[†]chlorhexidine gluconate; mfg: Stuart Pharmaceuticals, Wilmington, Del

[‡]povidone-iodine; mfg: Purdue Frederick, Norwalk, Conn



Atlas Fig. 10. Delayed thawing with ice and snow. The patient, a 54-year-old Alaskan Eskimo trapper and hunter, was on a trail in the high arctic when a blizzard struck. His dog team ran off, leaving him stranded without food, water, or shelter, and wearing thin gloves and uninsulated rubber boots. The ambient temperature varied between -50°F and -20°F (-45°C to -29°C). He walked for 6 days, his feet “frozen solid” by the third day. He walked at least 20 miles each day with only snow available for liquid. His feet were frozen for at least 4 days and he left them frozen, without trying to thaw, to maintain adequate walking capability and to survive. On reaching the village of Black River, Alaska, his feet were immersed in snow and ice water and thawed by this delaying method over an 8-hour period. (a) On arrival at the hospital in Anchorage, the feet were edematous, cyanotic, and cold. They were wrapped with soft dressing to avoid bleb rupture, protect tissue, and avoid refreezing injury. (b) Sixth postthaw day. The feet demonstrate a sign of very poor prognosis. The blebs are dark, moderately hemorrhagic, and proximal to the metatarsophalangeal joints. The toes and distal tissues are without blebs or blistering, and are dusky, edematous, cold; the foot is insensitive at that level. Phalangeal amputation or midfoot amputation is generally unavoidable with this pattern. The final result might be anticipated from the date of admission, as early as 24 hours after the thaw, when blebs are large, hemorrhagic, and proximal, rather than pink, large, and distal.

(c) Thirtieth day. The feet, on the frostbite regimen of twice-daily whirlpool baths, demonstrate superficial infection at the junction of the viable and gangrenous tissues. Infection is held in abeyance and controlled by whirlpool baths and aseptic care, permitting the self-demarcation of tissues, so that maximum length of foot is gained. Guillotine amputation is considered from this point on, once the tissue edema has subsided and there is no further tissue retraction. (d) Six months. Following revision amputation at the distal metatarsal level at 3 months, the patient went on to a good result and returned to his occupation of trapper and hunter. NOTE: In the very early days of treatment, many patients were hospitalized for long periods. Now, owing to increasing hospital and medical expense, patients are sent home or to a nursing home after the acute stage, where the postthaw regimen (including whirlpool therapy, all drugs required, and digital exercises and biofeedback training) is carried out under supervision.



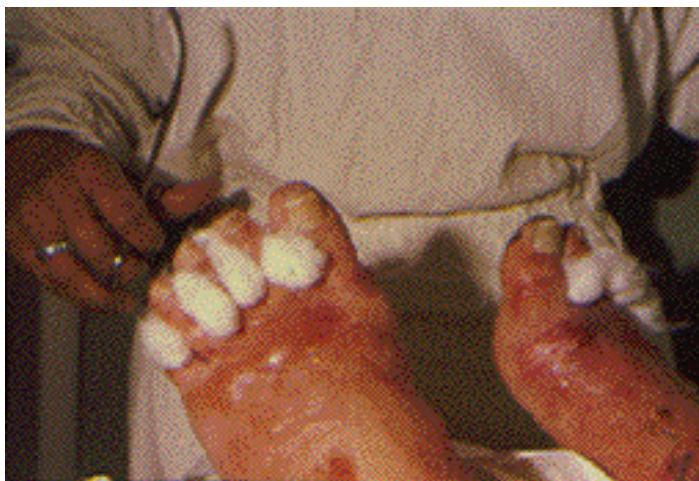Atlas Fig. 11. Freezing injury thawed with excessive heat (scalding water from a teakettle poured over freezing hands). (a) The burn appearance at 24 hours after the thaw. (b–d) From 48 hours after the thaw through the 16th day, gradual necrosis of tissue is seen, with eventual increasing mummification. (e) Spontaneous digital amputation was present between the fifth and sixth weeks, without surgical interventions. As with the freeze–thaw–refreeze injury, freezing injury thawed by excessive heat usually results in higher incidence of amputation, and at higher levels, on feet and hands.

TREATMENT AFTER THAWING

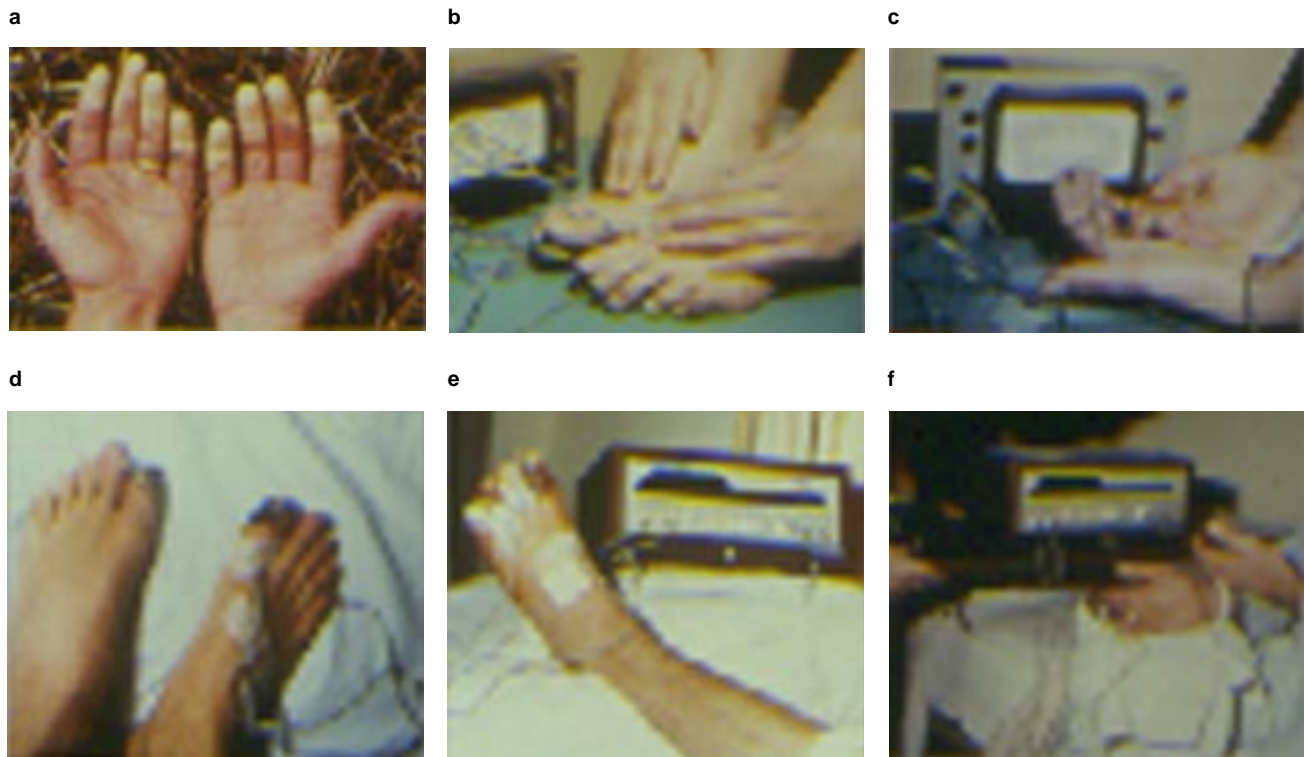ATLAS EXHIBIT 5

TREATMENT AFTER THAWING

1. Protect the thawed part.
2. Use sterile sheets, masks, and gowns during the bleb stage.
3. Practice "open" treatment.
4. Shun macerating dressings.
5. Administer whirlpool baths with benign soap twice daily.
6. Leave blebs intact.
7. Exercise digits constantly.
8. Avoid early debridement or amputation.
9. Split constricting eschar carefully; whirlpool action will debride gently thereafter.
10. Use antibiotics only with deep or ascending infections.
11. Administer toxoid booster (recommended).
12. Place cotton pledgets between digits to prevent maceration.
13. Avoid narcotics.
14. Consider early skin grafts and late pedicle flaps.
15. Use antibiotics, vasodilators, enzymes, sympathetic blockade, or sympathectomy if needed. Alcohol can be ingested in moderation if requested; smoking should not be permitted.
16. Possibly prevent infection and pain with Moyer's method, using 0.5% AgNO₃.
17. Consider fasciotomy if tissue compartment pressure is evident.



Atlas Exhibit Fig. To avoid maceration, cotton pledgets are applied between toes and fingers. If severe swelling or edema occur, pledgets are discontinued to minimize digital vessel pressure. Macerating ointments and salves are avoided if they will not permit the whirlpool to wash off superficial debris and bacteria.



Atlas Fig. 12. Biofeedback, an ancillary therapeutic method for raising digital temperature. (a) The hand of a patient with Raynaud's phenomenon, representing the thousands of individuals who demonstrate a labile vasomotor response to cooling, even if that cooling is by a slight drop of ambient temperature (eg, 68°F–65°F). As does Raynaud's phenomenon, frostbite and other cold injuries respond to biofeedback training, or physiological self-regulation. The technique encourages patients who are concerned over the appearance of cyanosis and early tissue loss, giving them a means of contributing to their treatment. Patients practicing the technique can increase the skin temperatures of their digits from the low 70s to the high 80s (degrees Fahrenheit; ~ 21°C–32°C) or even higher; the technique prevents as well as treats frostbite or other cold injury. (b) Relaxation techniques and biofeedback training permit cool or cold hands and feet to be warmed by reversing the phenomenon of cold-induced vasoconstriction. (c) Selective control of each hand by biofeedback: the left hand is cold and cyanotic, but the right, which is connected to the thermistor, is vasodilated. (d) A frostbite patient with necrosis of the large toe is using biofeedback to increase the blood flow in the border area of viability. (e) A borderline freezing injury of the foot is treated by biofeedback techniques to avoid tissue loss and increase circulation. (f) The technique is particularly effective for hands; in most patients, they appear to be more easily warmed than feet. The technique is helpful, too, in warming digits to avoid injury.

ATLAS EXHIBIT 6

DRUGS USED TO TREAT FROSTBITE

- Plasma volume expanders (eg, low molecular weight dextran)
- Vasodilating agents (tolazaline hydrochloride; eg, Priscoline, Vasodilan)
- Hypotensive agents (guanethidine monosulfate; eg, Reserpine)
- Hemorrhologic agents (pentoxifylene; eg, Trental)
- Calcium blocking agents (eg, Nifedipene)
- Sympatholytic agents (phenoxybenzamine hydrochloride; Dibenazline)
- Anticoagulating agents (eg, Heparin)
- Thrombolytic enzymes (eg, streptokinase, tissue plasminogen activator)
- Industrial solvent (dimethyl sulfoxide)
- Nonsteroidal antiinflammatory agents (acetylsalicylic acid [aspirin]; ibuprofen [eg, Motrin])

PROGNOSIS

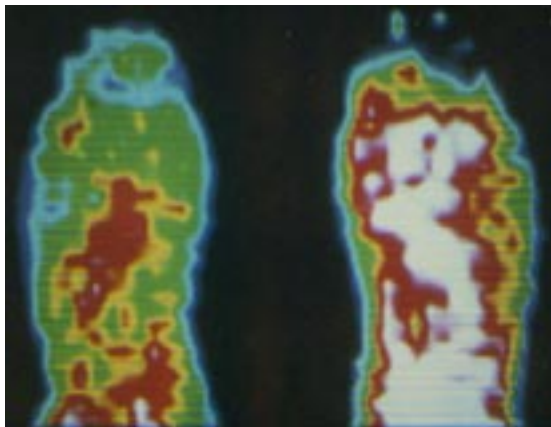
ATLAS EXHIBIT 7

FROSTBITE PROGNOSIS, I

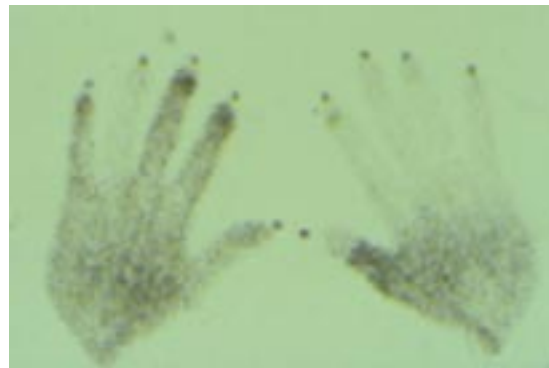
Prognosis is *best* when

1. Freezing is of short duration and depth is superficial.
2. Freezing is not associated with hypothermia, fracture, or other trauma.
3. Thawing is by rapid rewarming.
4. Blebs develop early, pink, and large, and extend to digital tips.
5. Capillary perfusion returns rapidly.

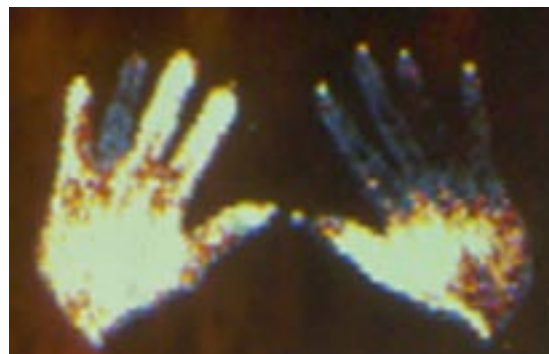a



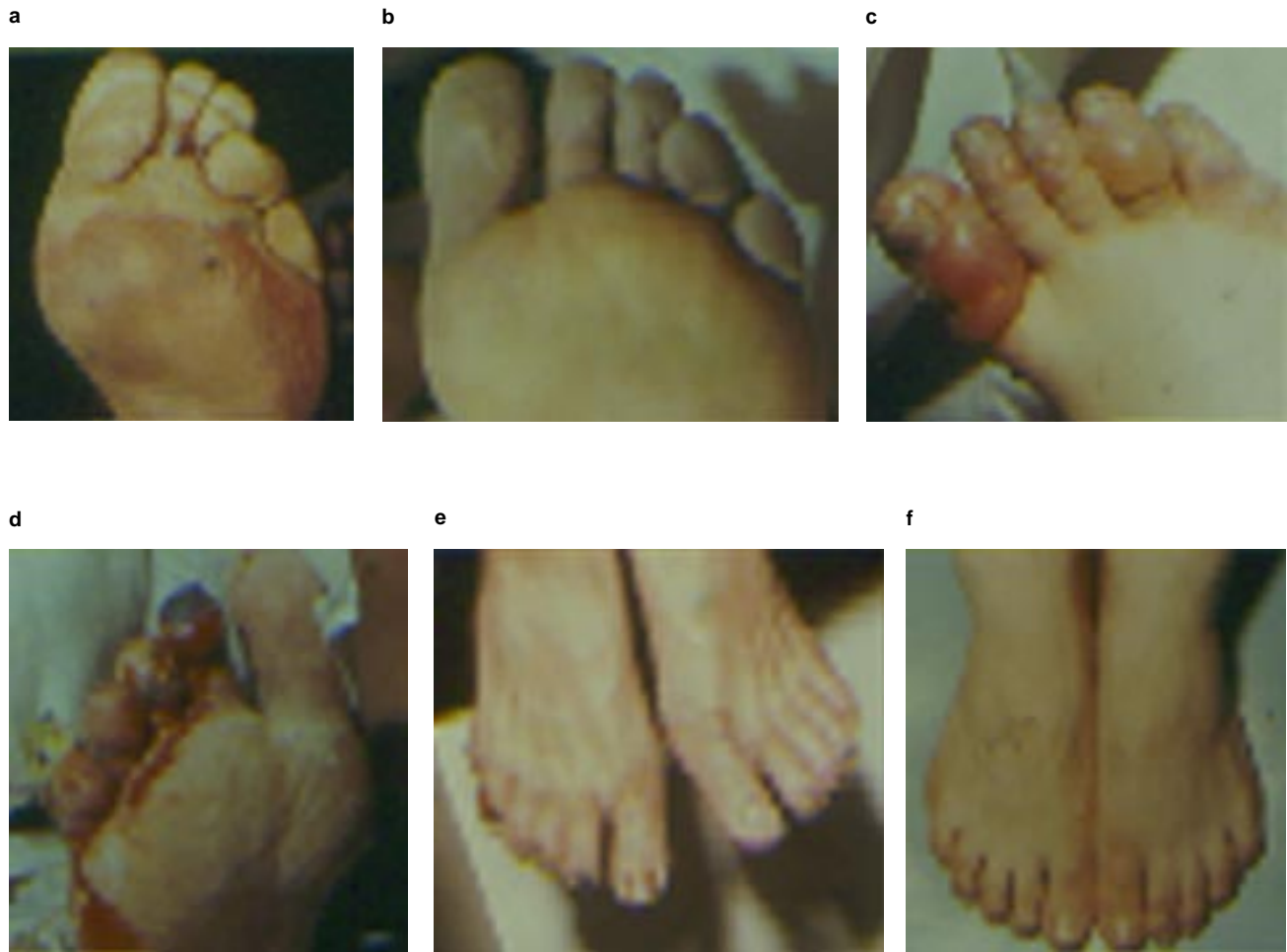b



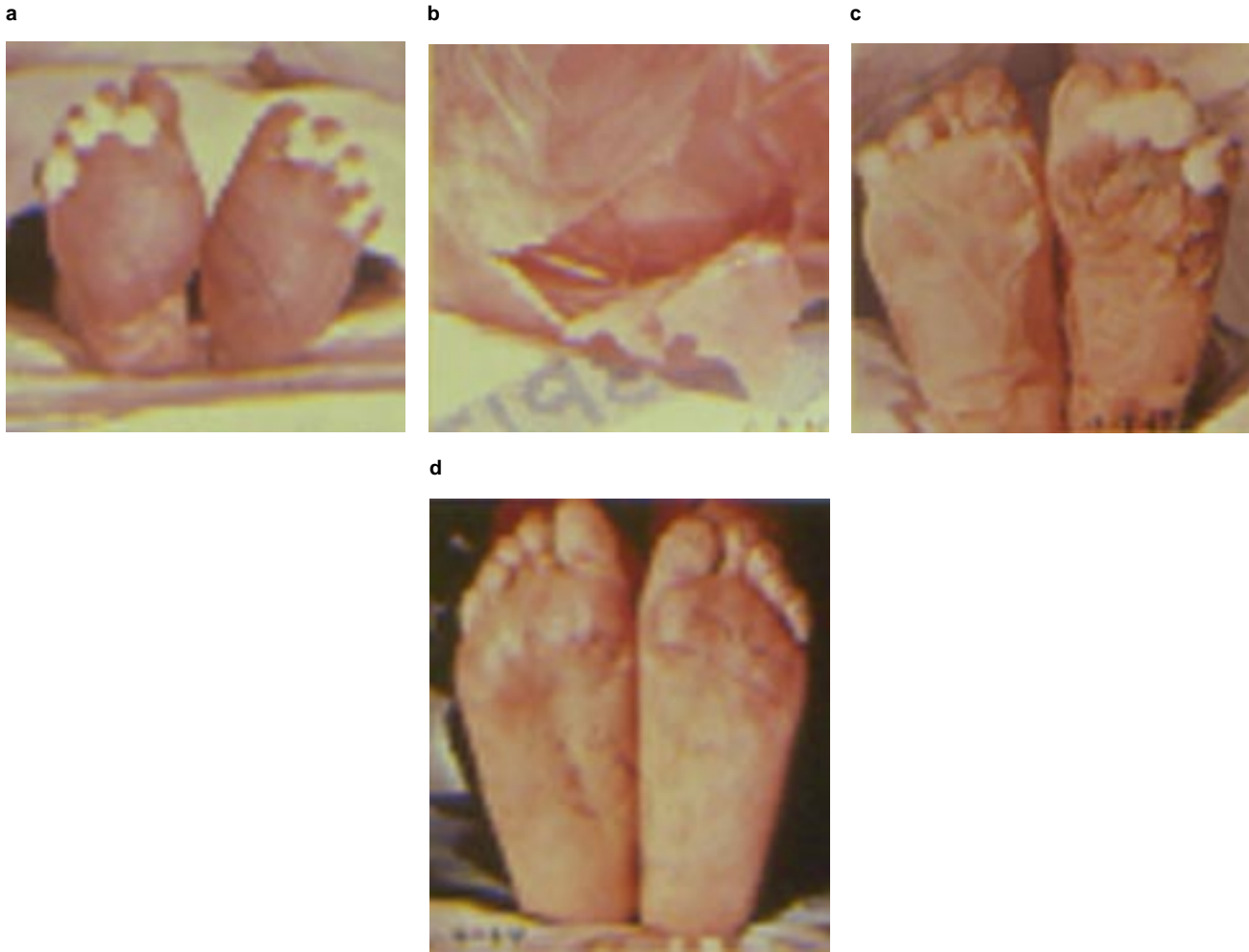
c



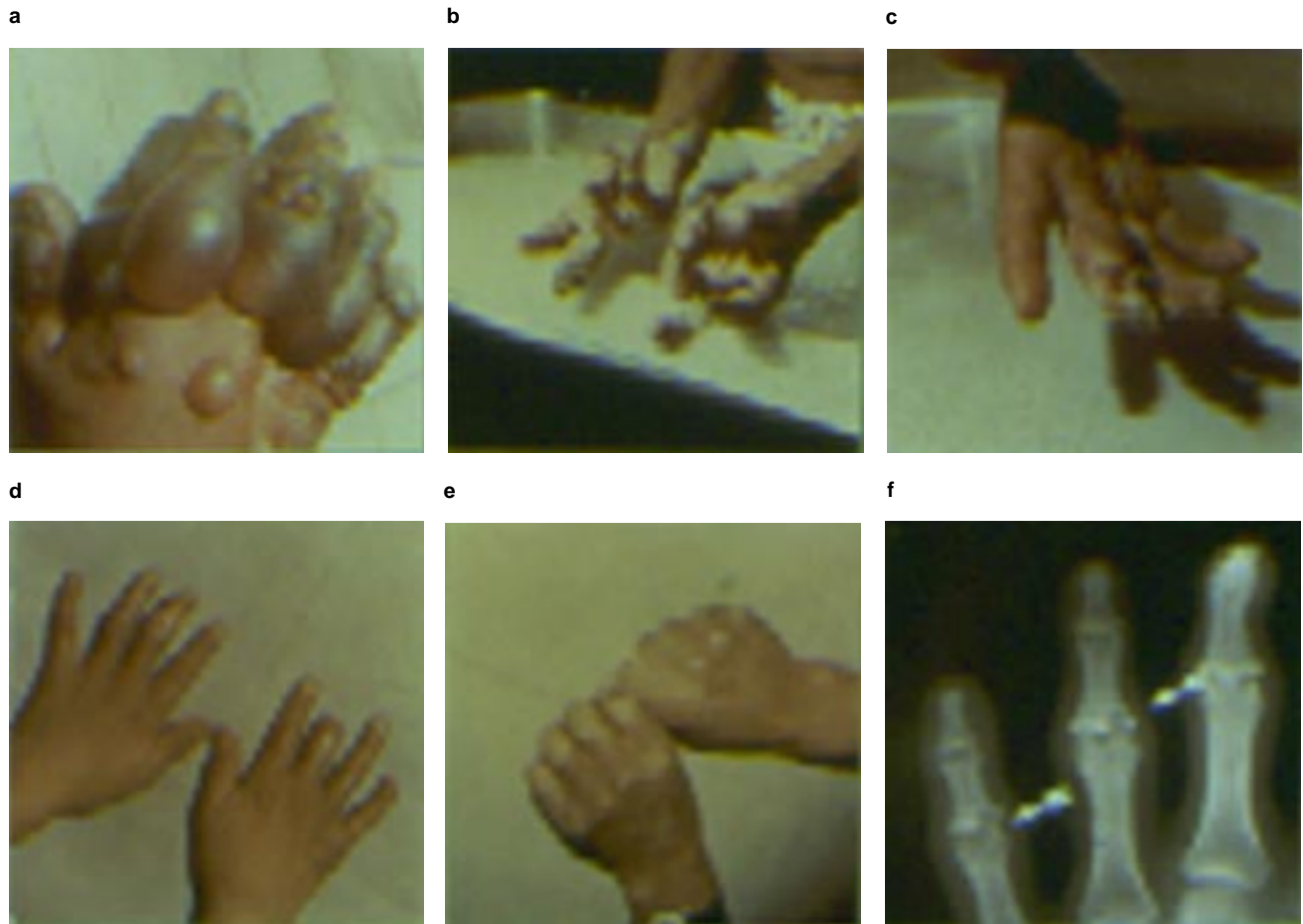
Atlas Fig. 13. For an early prognosis of the cold injury, thermography and isotope studies are helpful. Thermography permits early evaluation of the depth of freezing and adequacy of superficial perfusion, although it does not show the status of the microvascular circulation. Deeper tissues are evaluated with technetium 99m studies. Repeated evaluations with both modalities aid in determining the effectiveness of therapy. (a) In thermography, bright colors generally indicate good circulation, while dark colors (green, blue, black) indicate poor blood flow. (b) The thermogram demonstrates decreased blood flow to finger 4 of the left hand, and fingers 5, 4, 3, 2, and the tip of the thumb of the right. (c) The isotope study of the same hands shows obvious loss of deep circulation in the previously identified fingers. (The patient had worn a ring on finger 4 of his left hand; all metal rings are discouraged, and in fact are removed, during postfreezing care.)



Atlas Fig. 14. Rapid rewarming in a water bath. Freezing occurred in a young hunter, aged 15, at ambient temperatures of -15°F , while he was wearing very tight, borrowed boots. (a) A cold, rigid forefoot without sensation or digital motion. Tissue compression and sock marks are obvious. Treatment was whirlpool bath and thawing at 110°F for approximately 20 minutes. (b) By 1 hour after thawing, the toes had assumed an ominous burgundy hue (indicating cyanosis). Cyanosis has since been demonstrated in other cases, more often at temperatures greater than 110°F . The cyanosis remained for approximately 6 hours, at which time small, discrete blebs began to appear. Gross sensation was present after thawing and remained so until bleb development. (c) Over the next 48 hours, large, clear blebs developed and ultimately extended to the digital tips. (Failure of distal bleb formation, in the presence of proximal blebs, is an ominous prognostic sign.) (d) At 30 days, gangrenous skin of the second toe can be seen. (e) By 6 weeks after the injury, the anatomy has been preserved but the changes of deep injury are obvious and include volar fat pad loss, subcutaneous fat loss, early interphalangeal joint contracture, nail changes, hypes-thesias, and hyperhydrosis. Epithelialization is complete. (f) By the 4th month, the extremity has adequate sensation; mild subcutaneous loss and interphalangeal joint contracture have occurred, with a few interphalangeal subarticular lesions present on roentgenographic examination. Increased sweating is present.



Atlas Fig. 15. Rapid rewarming with warm, wet towels. The victim's feet were frozen while barefooted in the snow; ambient temperature: 0°F (-18°C); exposure: 30 minutes. The police used warm, wet towels to rapidly rewarm the feet. (a) Within 24 hours, huge bullae formed on the plantar surfaces of the feet, giving the appearance of superficial freezing. (b) At the patient's request, the bleb on the left sole was ruptured because of severe formication. Fibrous strands formed in the serum 48 hours after freezing, before the bleb was ruptured. Serum content of blebs was similar to that of normal serum exudation, except for decreased protein. (c) Pain was much increased on the sole of the patient's left foot after the bleb rupture. No infection resulted with continued whirlpool therapy. At 5 weeks both feet were almost equal in pattern, with early return of sensation: the forefoot demonstrating hypesthesia; the arch and heel, hyperesthesia. (d) At 2.5 months, edema was still present on dependency or ambulation. The interphalangeal joints had less than 50% range of motion, with volar pad loss at the toes and incomplete desquamation.



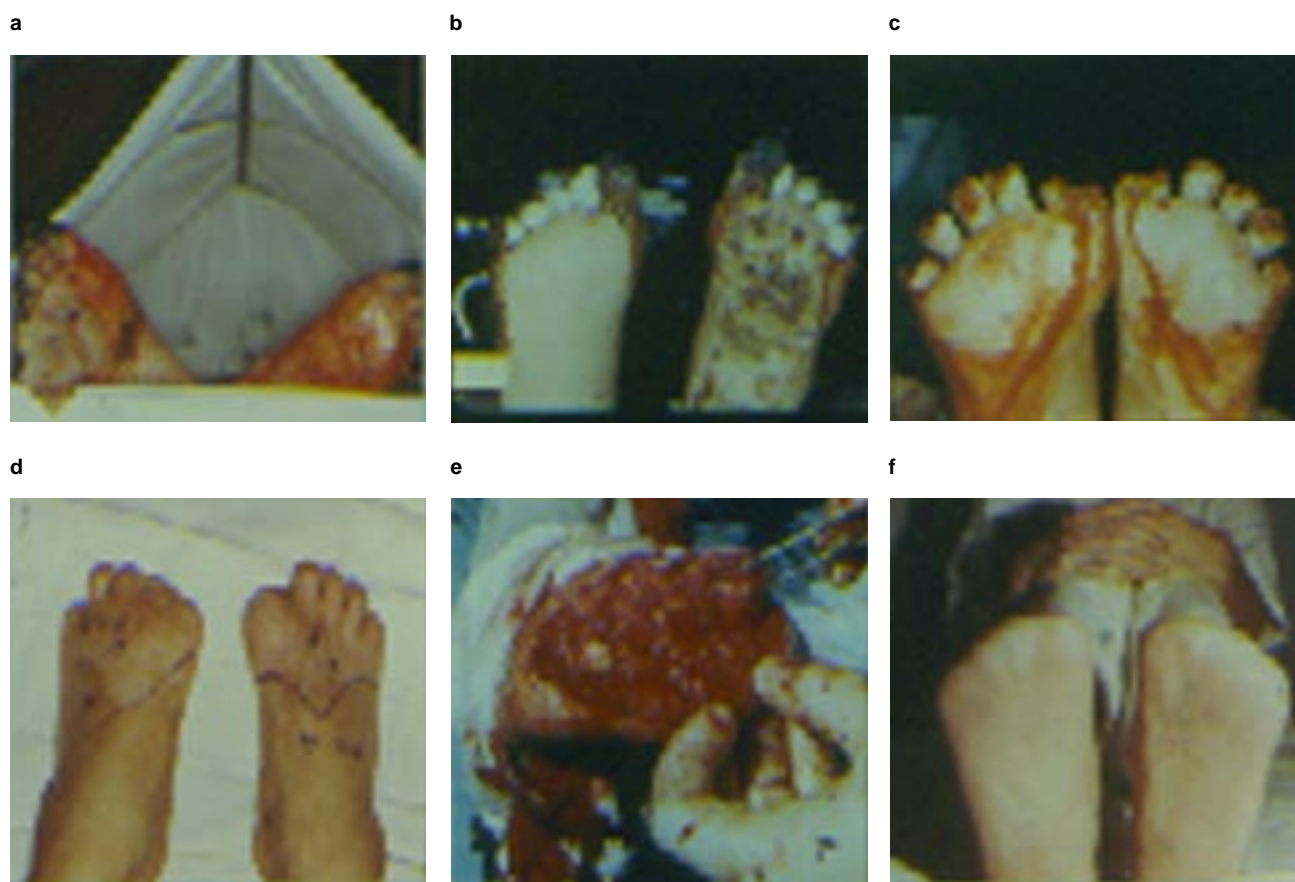
Atlas Fig. 16. Combined delayed warming (with ice and snow) and rapid warming (in water). A 23-year-old dog-team driver, who lost his dogs on the trail, froze both hands; ambient temperature: -14°C ; wind: 10 mph; exposure time: 1–2 hours. Delayed warming with snow and ice water was followed later by rapid warming in warm water. (a) By the fourth day after the injury, the clear, pink, large, distal blebs on the digits are notable, except for the mid finger of the right hand, the site of a previous digital neurovascular injury: a knife wound. (b) Twice daily whirlpool baths with pHisoHex soap and digital exercises are performed. By the third week, the gangrenous tip of the mid finger, right hand, and site of the old injury, are noted. (c) By the sixth week the necrotic tip of the mid finger of the right hand is seen, with volar fat pad loss to the fingertips throughout. (d and e) By the 12th week, partial finger amputation of the mid digit, right hand can be seen, along with scarified skin over the dorsum of the right and left hands and contracture of the proximal interphalangeal joints of digits 5, 4, and 3 on the left hand and 5, 4, 3, and 2 on the right. (f) A followup roentgenogram 3 years later demonstrates periarticular, lytic destructive changes of cartilage and bone at the proximal interphalangeal joints, fingers 5 and 4 on the right, and similar changes on the left hand. The invasion of fibrous tissue through the joint surfaces results in marked limitation of joint motion.

ATLAS EXHIBIT 8

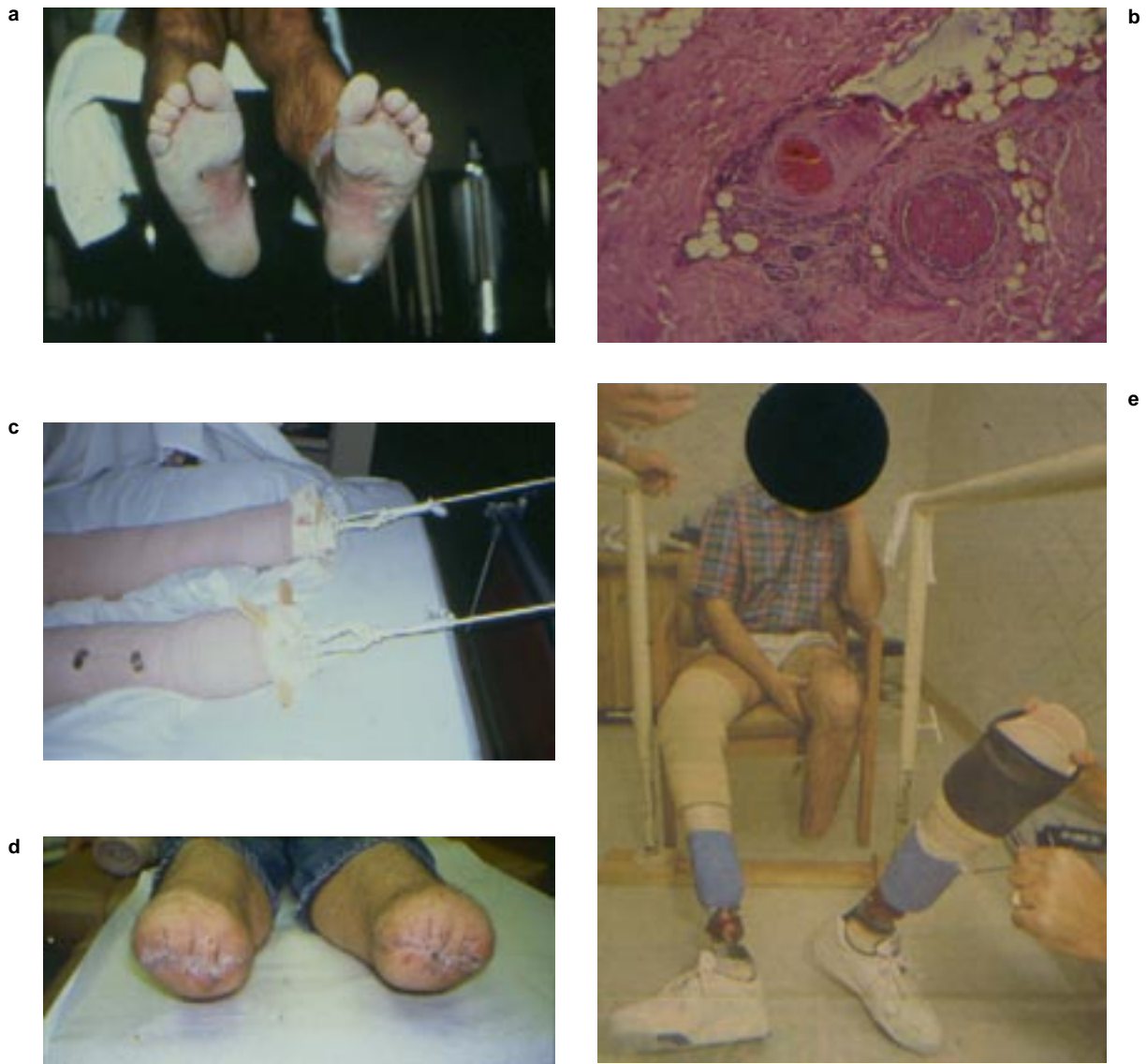
FROSTBITE PROGNOSIS, II

Prognosis is uncertain when


1. Thawing is spontaneous.
2. The frozen state is of long duration.
3. Freezing is superimposed on a fracture or dislocation or is associated with soft-tissue trauma.



Atlas Fig. 17. Spontaneous thawing, in jail. After a drinking episode in rural Alaska, the victim suffered deep frostbite to both feet. (a) By 1 week after the injury, the prisoner, now with gangrenous toe tips, was transferred to a hospital. (b) The irrational prisoner escaped the hospital bed and ran barefoot in snow until captured. A diagnosis of postalcoholic encephalitis was made. (c) Necrotic tissues were removed; the operative incision, through which a penrose drain had been inserted, was approximated using one suture. Whirlpool therapy was continued. (d) The patient experienced pain, swelling, hyperhidrosis, hypesthesia, and anesthesia in the residual digits. (e) An avascular first metatarsal head was revealed at a revision operative procedure performed 1.5 years after the injury, after which the patient received (f) an adequate weight-bearing transmetatarsal amputation.



Atlas Fig. 18. Exposed for 5 days at 19,000 ft on Mount McKinley before helicopter rescue, this climber from Poland, secluded in a small snow cave without food or water for the last 3 days before rescue, sustained deep freezing injury of both feet to the ankle level. The injury was not one of freeze–thaw–refreeze but instead of severe, deep, long-duration freezing at temperatures far below 0°F, and with 25- to 50-knot winds for most of the first 4 days. Rescue was on the fifth day. (a) The climber is in the emergency department prior to rewarming. The impressive pallor of the climber’s feet and ankles and the history are indicative of freezing injury. Technetium scans demonstrated no capillary perfusion below the ankle level bilaterally. (b) The pathology slide, after transmalleolar amputation of the feet and ankles, demonstrates intraluminal clotting in a small artery (center) and vein (right of center); the clotting occurred throughout the foot. (c) After guillotine amputation, the climber’s long tibial-fibular stumps are contained in skin traction with light weights to permit gradual closure and granulation. (d) The stumps, after revision amputation and closure. When severe gangrenous change is present, with always at least superficial infection, guillotine procedure followed by delayed closure or skin graft is chosen. (e) With long tibial stumps and a supracondylar patellar tendon bearing prosthesis, the patient has since recovered and has been climbing mountains again.

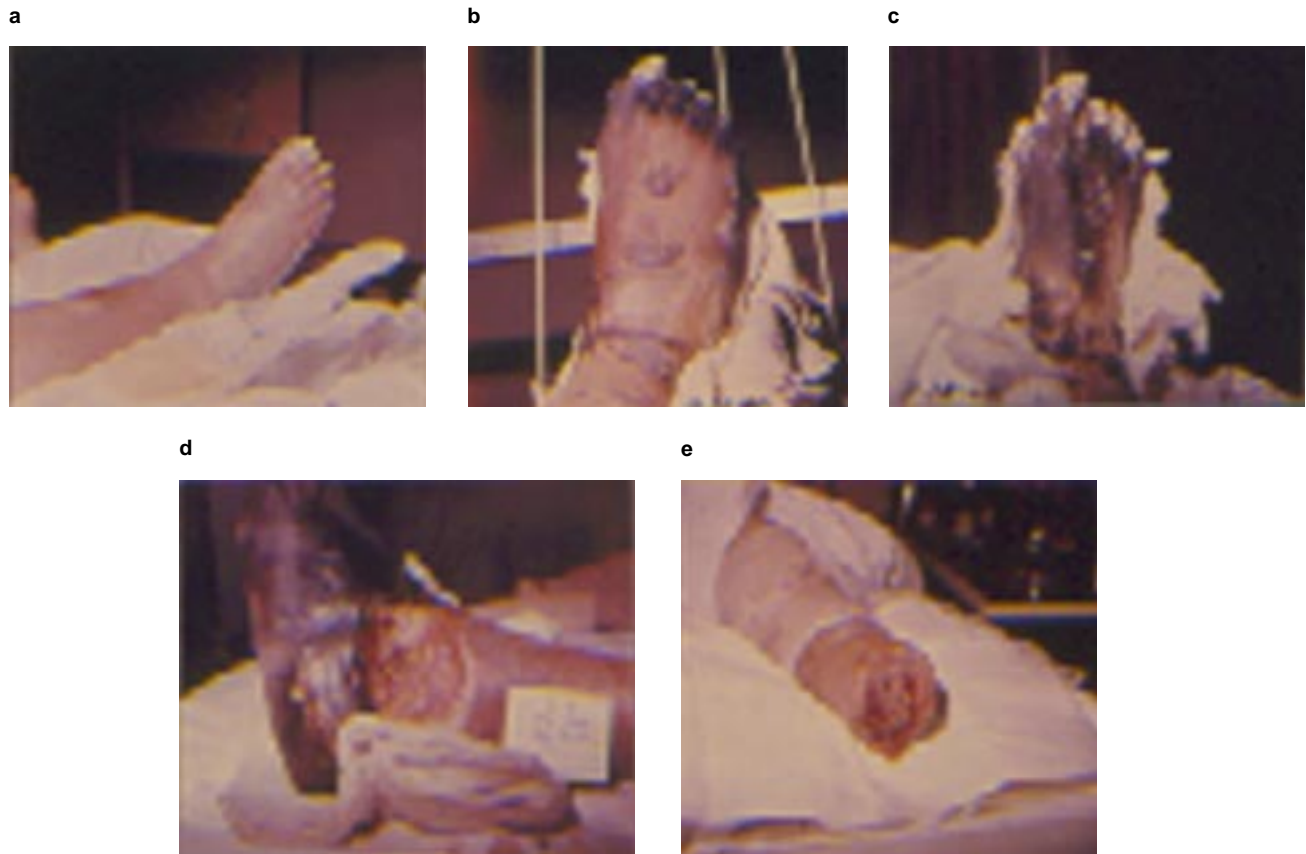


Atlas Fig. 19. Open fracture followed by freezing cold injury, thawed by rapid rewarming. A trapper was injured, sustained an open fracture of the distal radius and ulna on the left arm. He sustained freezing of the hand and wrist while seeking help. The warming at rescue was rapid rewarming in warm water; the forearm was splinted to protect the fracture. (a) Twenty-four hours after the warming, the blebs are large, light colored, and clear, and they extend to the fingertips, an excellent prognostic sign. (b) The open area above the fracture was debrided after thawing with thorough irrigation of the wound, fracture repositioning, and the antibiotic coverage (streptomycin and penicillin) that was in vogue at the time (the 1960s) was used. The arm was splinted only, and digital exercise immediately done. The wound was packed open and allowed to granulate closed. (c) The displaced (compound) fracture, with displacement and skin penetration of the fragments of radius and ulna demonstrated on roentgenogram. (d) The forearm and upper arm were contained in a plastic open splint, allowing for whirlpool therapy, motion of the joints, and observation unhindered by occlusive dressings. Whirlpool with soap (pHisoHex,^{*} Hibiclens,^{*} Betadine[‡]) was used twice daily for constant debridement. (e) Tissue healing was eventually sufficient to permit surgical fixation of the bone fragments. The patient sustained no anatomical loss. Fractures, followed by freezing, appear to do best if rapid rewarming is utilized as the thawing method. This can be supplemented if necessary by fasciotomy, stabilization of the fracture at least by splinting, and immediate reduction of fracture dislocations.

^{*}hexachlorophene detergent cleanser; mfg: Sinofi Winthrop Pharmaceuticals, New York, NY

[†]chlorhexidine gluconate; mfg: Stuart Pharmaceuticals, Wilmington, Del

[‡]povidone-iodine; mfg: Purdue Frederick, Norwalk, Conn



Atlas Fig. 20. Fracture or dislocation with superimposed freezing and spontaneous thawing. Two caribou hunters' aircraft struck a mountain ridge. One hunter sustained a fracture of the right mid tibia (and of the dorsal spine, not shown here). (a) The extremity is cyanotic, demonstrating vascular insufficiency. Pedal pulses are absent, as is sensation to the level of the malleoli. No blebs are present at this stage. This is the typical picture of extremity fracture or dislocation when thawed by other than rapid rewarming. (b) By the 14th day, the minimal blebs formed were dark and serosanguinous. The foot was without sensation and the toes obviously gangrenous. (c) By 3 full weeks after the thaw, dry gangrenous change had encompassed most of the foot, including the plantar pad. Tissue necrosis continued; the extremity was amputated at the level of the fracture.

The second hunter, who sustained (d) a fracture dislocation of the left ankle, crawled 2.5 miles down a mountain, dragging his companion (views a–c) with him. Both legs of the second hunter froze, then thawed spontaneously in a tent. (e) His left ankle was amputated. The frozen right leg, not shown and not fractured, recovered.

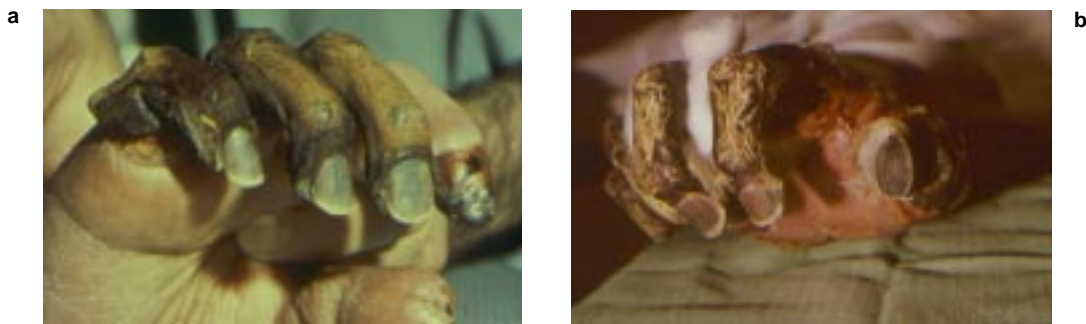Because of swelling, edema, vascular compression, or compartment syndrome, good results are generally obtained only after rapid rewarming and with, most often, fasciotomy.

ATLAS EXHIBIT 9

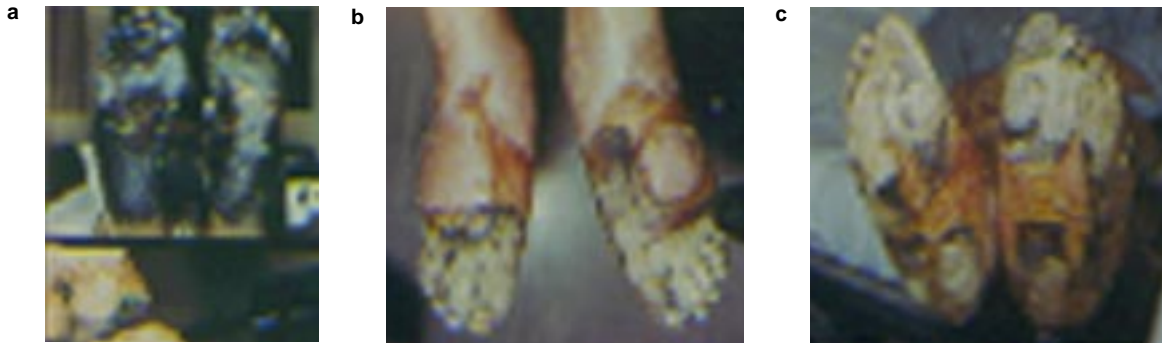FROSTBITE PROGNOSIS, III

Prognosis is *poor* when

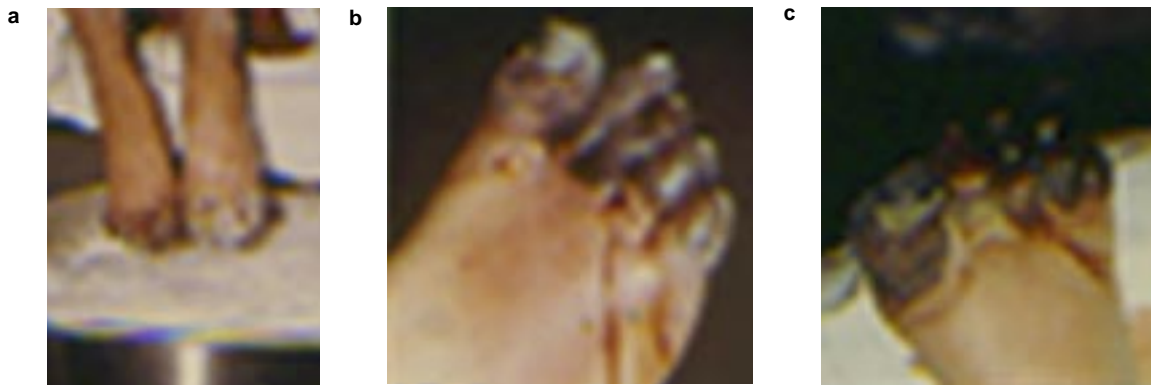1. Thawing is delayed (eg, the part is packed in ice and snow).
2. Thawing is by excessive heat.
3. Thawing (by any method) is followed by refreezing.
4. Freezing is superimposed on long-standing immersion (wet-cold) injury.
5. Freezing is associated with fracture or dislocation with unrelieved, increasing tissue compartment syndrome and vascular occlusion.



Atlas Fig. 21. Freezing injury followed by thawing at excessive heat. (a) These frozen fingers were thawed in a hot oven, which results in rapid mummification and dry, gangrenous tissues with early demarcation, often by the fifth day. (b) To emphasize the danger of thawing with excessive heat (> 116°F), this hand, thawed in water simmering in a teakettle, demonstrates at 3 weeks absolute mummification, with digits hard and total tissue death. Because of whirlpool treatment with pHisoHex or Hibiclens, however, the level of infection is superficial at the area of tissue demarcation, preceding eventual spontaneous amputation.

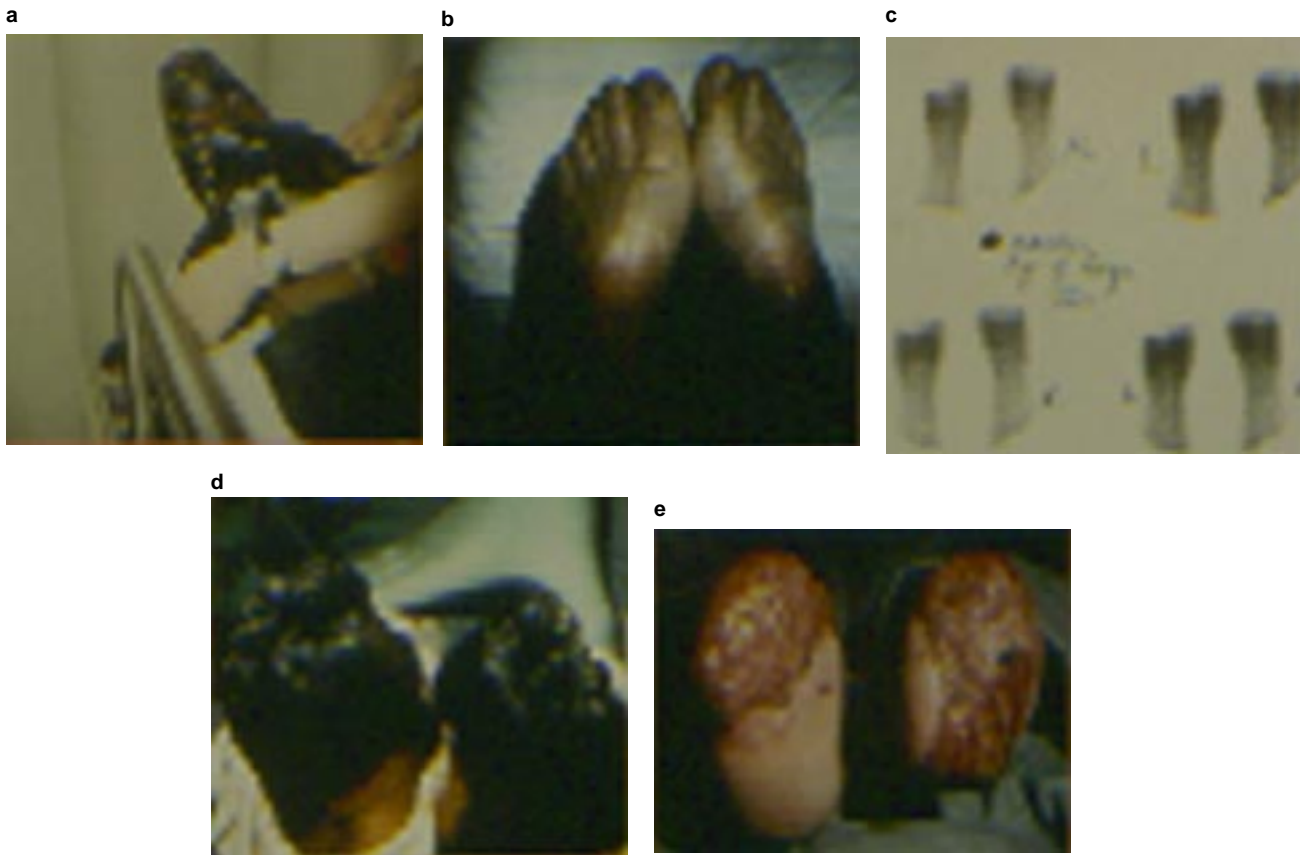

Atlas Fig. 22. Thawing with excessive heat. A vehicle was driven off the road to avoid hitting a dog team. The vehicle driver, wearing oxford shoes, ran 2 hours for help at an ambient temperature of -45°C (-50°F). On reaching shelter, he thawed his feet at a diesel generator exhaust at a temperature of approximately 79.4°C to 85°C (175°F – 180°F). (a) The victim was seen 3 weeks after the injury, at which time mummification of toes and epidermal gangrenous plaques were present on soles, and multiple dorsal escharotomies were performed on the lower right foot. (b) The appearance of the feet 3 months after the injury (and about 2.5 months after the dorsal escharotomies). (c) On the same day, epithelialization could be seen under the black eschar of sole and heel. (d and e) The patient was permitted to return to work and normal activity 10 months after the injury.



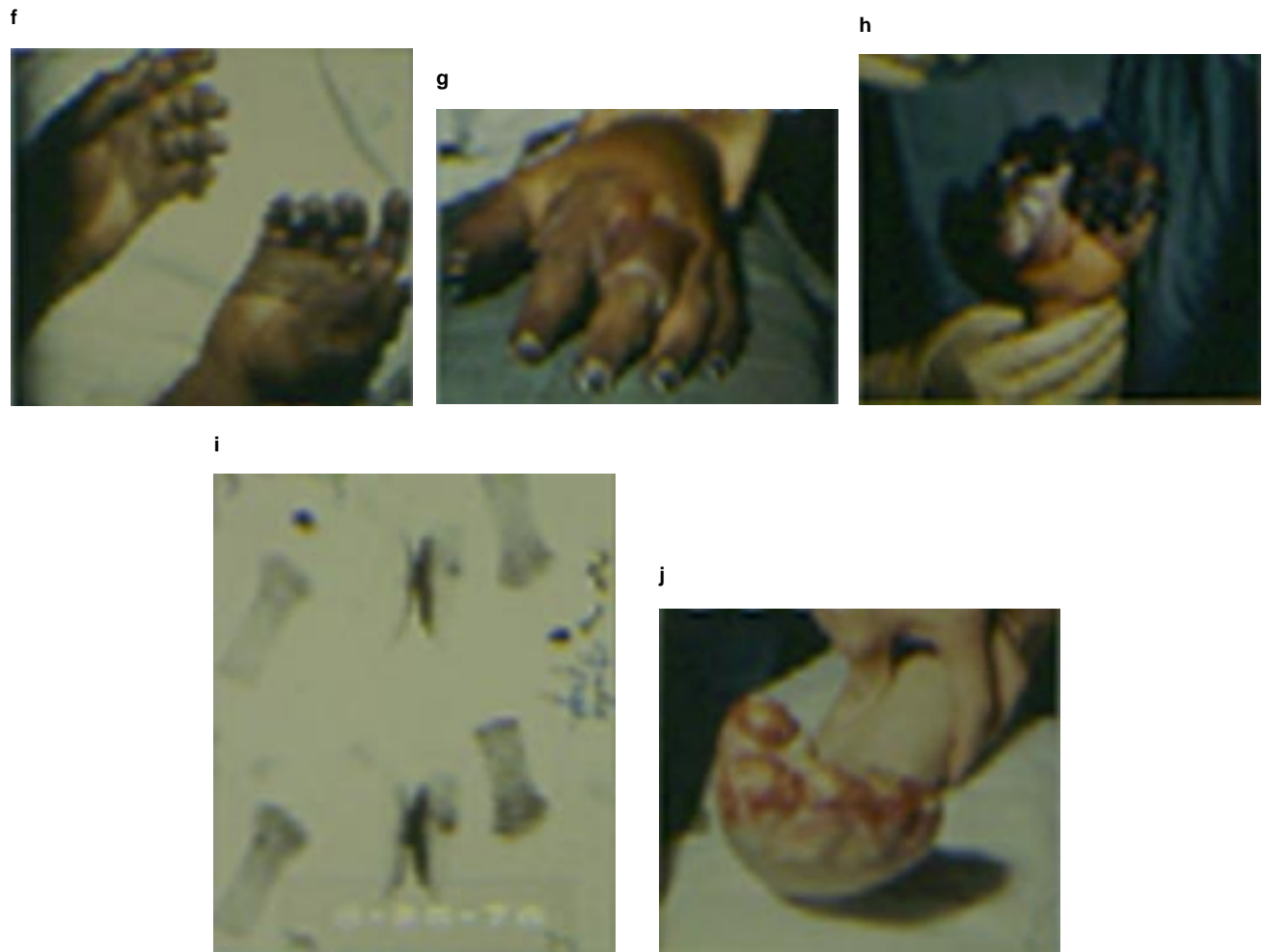
Atlas Fig. 23. One of the first documented cases of freeze–thaw–refreeze injury, in 1961; the injury occurred in Alaska, at the summit of Mount McKinley. Very often the resultant demarcation and even spontaneous amputation are present in less than 10 days, and the part is often lost at the site of the second freeze. In this case, the soft tissue separated after 7 to 10 days, assisted by the surgeon. Frames a through d were made from 25 May through 30 May. Frame e, showing the same foot but viewed from the sole, was made 7 days later, on 6 June. From this injury came the dictum, “Do not rewarm in the rescue area if there is danger of refreeze.”

Atlas Fig. 24. Bilateral freeze–thaw–refreeze injury of the hands and feet with severe dehydration and caloric depletion. Altitude: 19,000 ft (5,800 m); exposure: 4 or 5 days; ambient temperature: -35°C ; winds: severe.

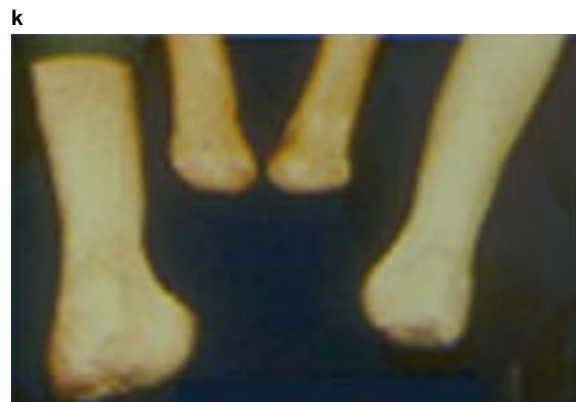

(a) After helicopter evacuation from Mount McKinley at 4,267 m, the patient's left foot is seen still in the climbing boot with its zippered neoprene liner; ice was found throughout the boot. (b) The feet, totally frozen to the malleolar level, demonstrate the zipper indentation of the neoprene sock. This phenomenon is not uncommon on high-mountain freezing injury. Unlike mountains near the equator, the barometric pressure at 4,572 to 4,877 m approaches 0.5 atm. As a consequence, cellular material in the boot or sock at this altitude expands; if the outer boot (made of leather or plastic) is rigid, then the pressure is directed inward to cause compression of the foot and occlusion of the underlying vessels. This contributes to loss of circulation, compartment swelling, pressure increase, and freezing injury. (c) Isotope studies done almost 2 weeks after the injury demonstrate loss of capillary perfusion to the level of heel pads and the mid tarsi. (d) At 2 months after the injury, infection is minimal because of twice-daily whirlpool therapy. The tissue is dry and mummified, with complete demarcation. (e) At 3 months, the guillotine amputation at the tarsal level, followed by split-thickness skin cover, has readied the feet for revision amputation and pedicle flap cover as necessary.

Atlas Fig. 24. *continued*

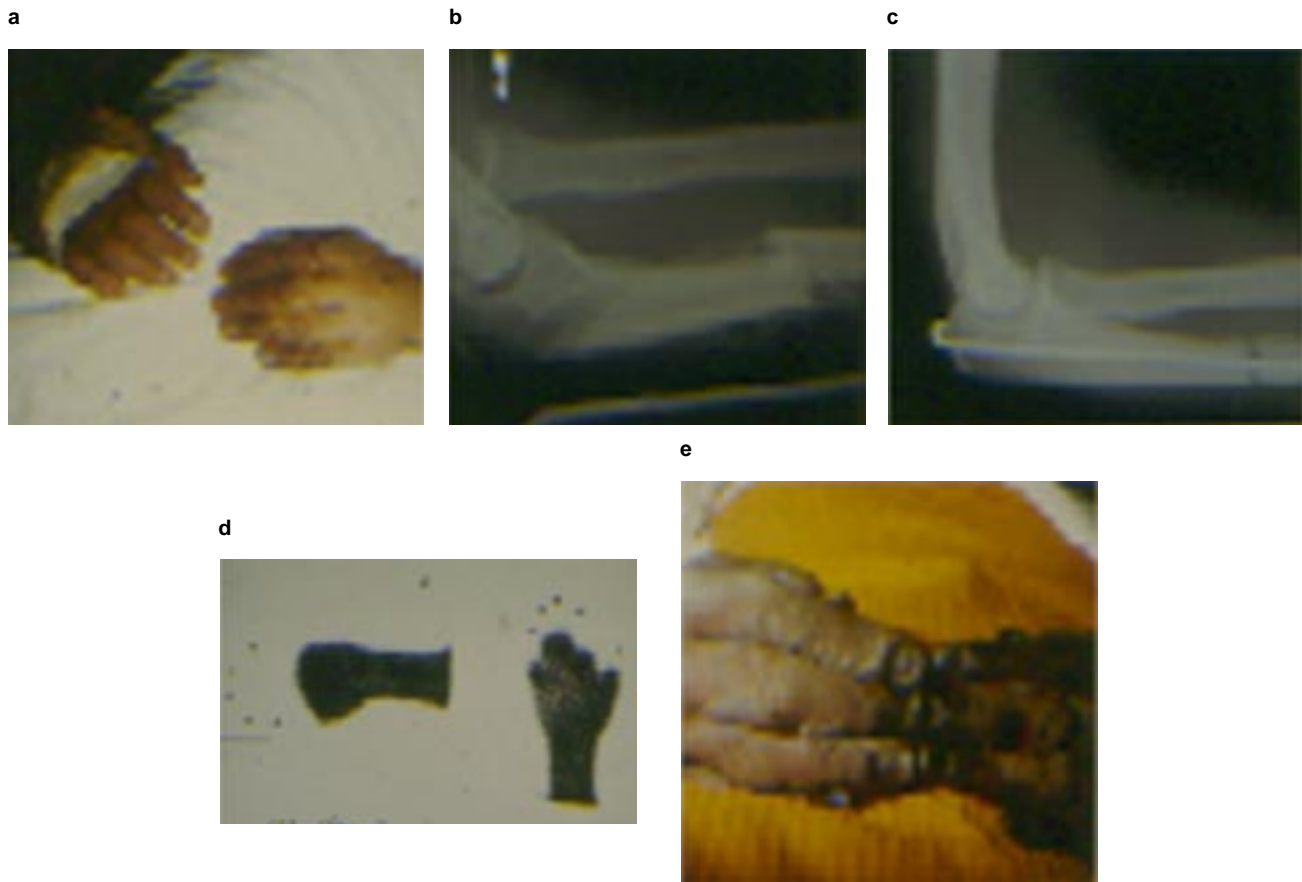


(f) Both hands, still frozen on the fifth day of exposure (a freeze–thaw–refreeze injury). An adequate history was limited because of severe disorientation of this patient and his companion. (g) Several hours after the thaw, the hand demonstrates no distal blebs, early mummification, flattening of the fingertips, and digital cyanosis—poor prognostic signs. (h) By 24 hours after the thaw, gangrene is developing in the hand and mummification of the digits is almost complete. This severe, early change is pathognomonic for a freeze–thaw–refreeze injury or thawing with excessive heat, especially the former. Fasciotomy revealed no viable tissues in digits or distal palm. (i) The isotope scan demonstrates total loss of capillary perfusion, just distal to the metacarpophalangeal junctions. (j) Guillotine amputation assisting the spontaneous demarcation was performed to the level of viability.

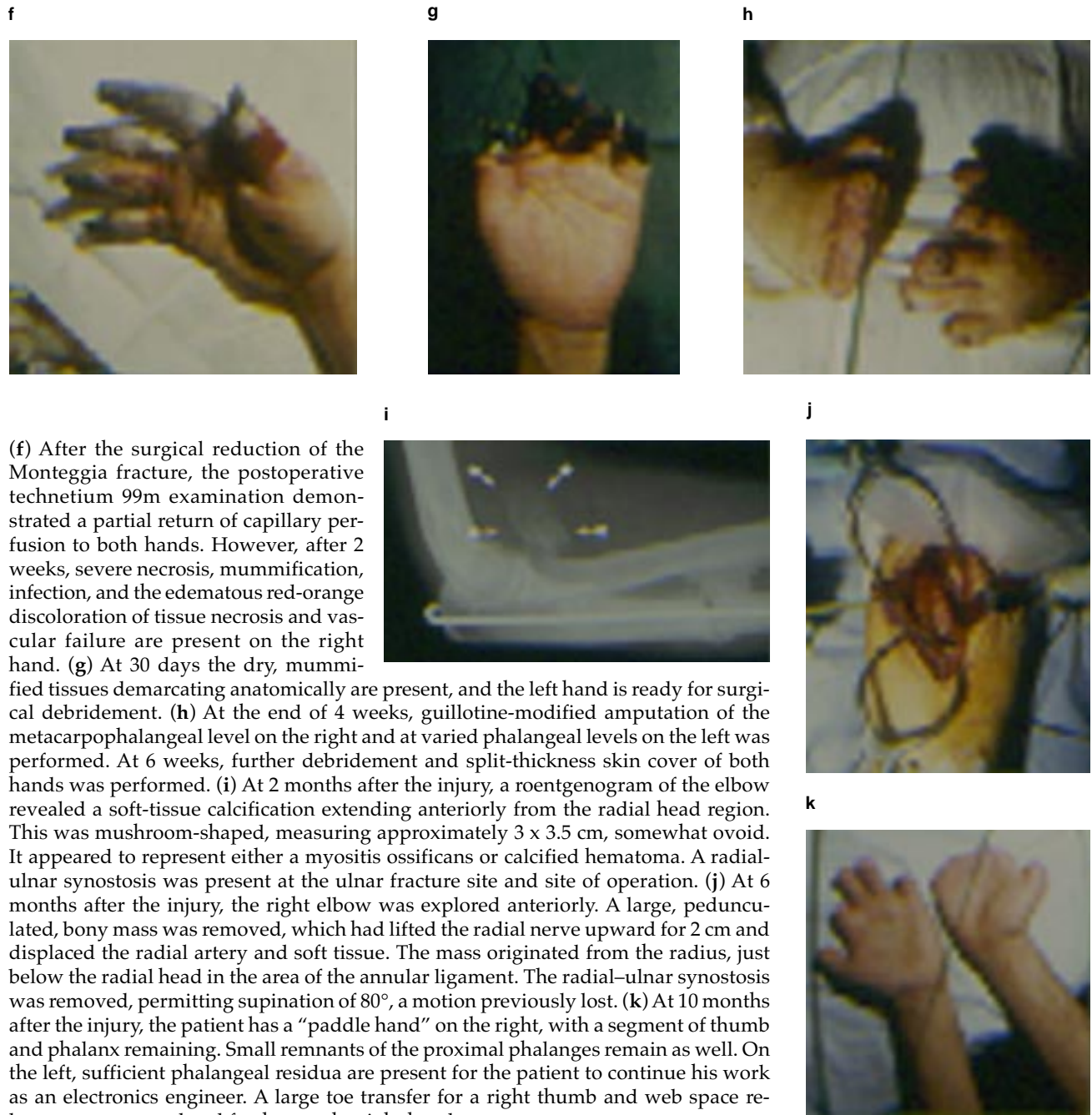


(k) The final result is a true disaster but one permitting function with prosthetic use. On the right foot, amputation left only a portion of the cuboid and cuneiform bones. On the left foot, only the calcaneus, talus, and navicular bones remain. On the left hand, amputation is at the mid-metacarpal level for the lateral four digits and at the metacarpophalangeal joint of the thumb. On the right hand, amputation is at the distal metacarpals for four lateral digits and at the metacarpophalangeal joint of the thumb.

Atlas Fig. 25. Multiple trauma with spontaneous thawing and refreezing. In the high arctic Bering Sea Island, the victim's helicopter crashed into a ridge. The helicopter had been buffeted by 50-mph winds; the ambient temperature was -8°F (-22°C). The patient was the lone survivor, his companions dying of injury and exposure. He was without gloves at crash time but had adequate boots. His right arm was fractured. On regaining consciousness, he found that his hands were frozen. He was able to crawl but discovered that he had multiple injuries that restricted motion. Numerous times over the next 36 hours he crawled to a high ridge to signal for help with a locator transponder. During this time he sustained multiple freeze injuries to his left hand and attempted to protect his right hand from further freezing. He was rescued by snowmachine, then flown to Anchorage, Alaska. Spontaneous thawing occurred in transit. On arrival at the hospital, his examination revealed him to have a closed head injury, compression fractures of two thoracic vertebrae, and soft-tissue injuries of the neck and possible fracture compression of several cervical bodies, in addition to bilateral freezing injury to the hands and Monteggia fracture dislocation of the right elbow.

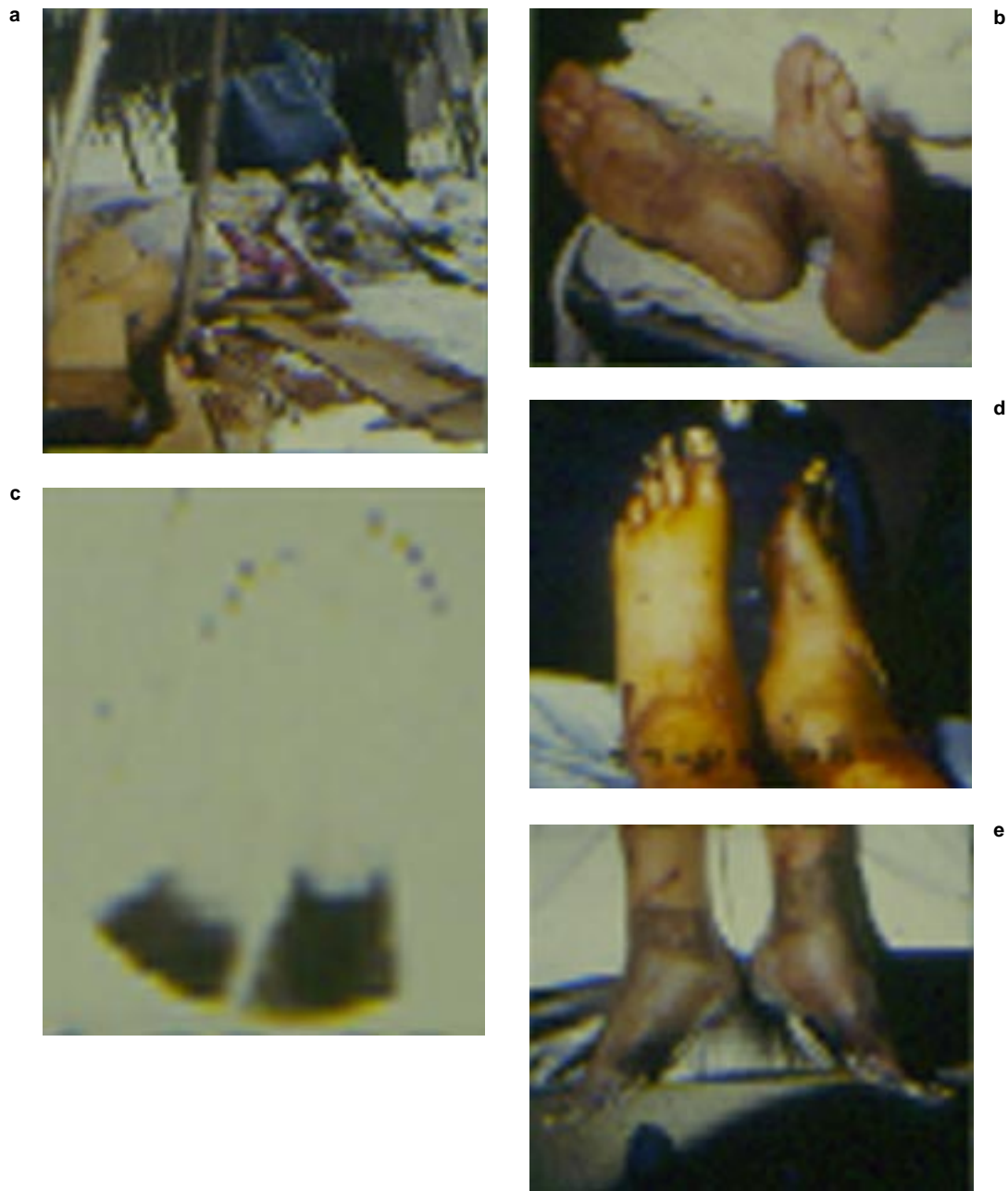

(a) The initial admission photograph demonstrates, despite thawing of the hand, the presence of very small blebs primarily proximal in position. The tips of the fingers were very cyanotic. Both hands, although insensitive, seemed to have adequate warmth. (b) On the day of admission, the roentgenographic examination of the right elbow revealed a dislocation of the radial head and fracture of the proximal ulna (a Monteggia fracture). (c) The day after admission, the fracture of the ulna was openly reduced and gently fixed with a Rush intramedullary nail. The radial head spontaneously reduced itself when the ulna was fixed. The procedure was done to facilitate motion, care, and physiotherapy, and to reduce swelling that might limit vascular supply. (d) Before surgery, a technetium 99m scan of both hands demonstrated no perfusion of the fingers beyond the metacarpophalangeal junction of the right hand; the left hand has capillary perfusion of the proximal and mid phalanx of the 5th finger and proximal phalanx of the 4th and 3rd fingers, and only a small portion of proximal phalanx of the thumb and index finger. (e) A week after the accident the left hand demonstrates advanced mummification of the distal digits, which are dry with edema, and early liquefaction necrosis of the digits of the right hand. The pattern of the left hand is that of a typical freeze-thaw-refreeze injury. The pattern of the right may represent the effect of unreduced fracture dislocation over 36 hours and the uncertain result of spontaneous thawing, particularly with fractures or dislocations.

Atlas Fig. 25. *continued*

(f) After the surgical reduction of the Monteggia fracture, the postoperative technetium 99m examination demonstrated a partial return of capillary perfusion to both hands. However, after 2 weeks, severe necrosis, mummification, infection, and the edematous red-orange discoloration of tissue necrosis and vascular failure are present on the right hand. (g) At 30 days the dry, mummified tissues demarcating anatomically are present, and the left hand is ready for surgical debridement. (h) At the end of 4 weeks, guillotine-modified amputation of the metacarpophalangeal level on the right and at varied phalangeal levels on the left was performed. At 6 weeks, further debridement and split-thickness skin cover of both hands was performed. (i) At 2 months after the injury, a roentgenogram of the elbow revealed a soft-tissue calcification extending anteriorly from the radial head region. This was mushroom-shaped, measuring approximately 3 x 3.5 cm, somewhat ovoid. It appeared to represent either a myositis ossificans or calcified hematoma. A radial-ulnar synostosis was present at the ulnar fracture site and site of operation. (j) At 6 months after the injury, the right elbow was explored anteriorly. A large, pedunculated, bony mass was removed, which had lifted the radial nerve upward for 2 cm and displaced the radial artery and soft tissue. The mass originated from the radius, just below the radial head in the area of the annular ligament. The radial-ulnar synostosis was removed, permitting supination of 80°, a motion previously lost. (k) At 10 months after the injury, the patient has a "paddle hand" on the right, with a segment of thumb and phalanx remaining. Small remnants of the proximal phalanges remain as well. On the left, sufficient phalangeal residua are present for the patient to continue his work as an electronics engineer. A large toe transfer for a right thumb and web space releases are contemplated further on the right hand.

The findings in this case represent the disastrous results of severe associated fracture followed by thawing other than rapid rewarming, in this case spontaneous thawing, and represent the need for immediate care and early reduction of the fractures or dislocations. Thrombolytic therapy was inappropriate in this case because of the combined injuries to the head and neck and the thoracic spine, as the use of thrombolytic enzymes is considered likely to cause intracranial or intraspinal bleeding.

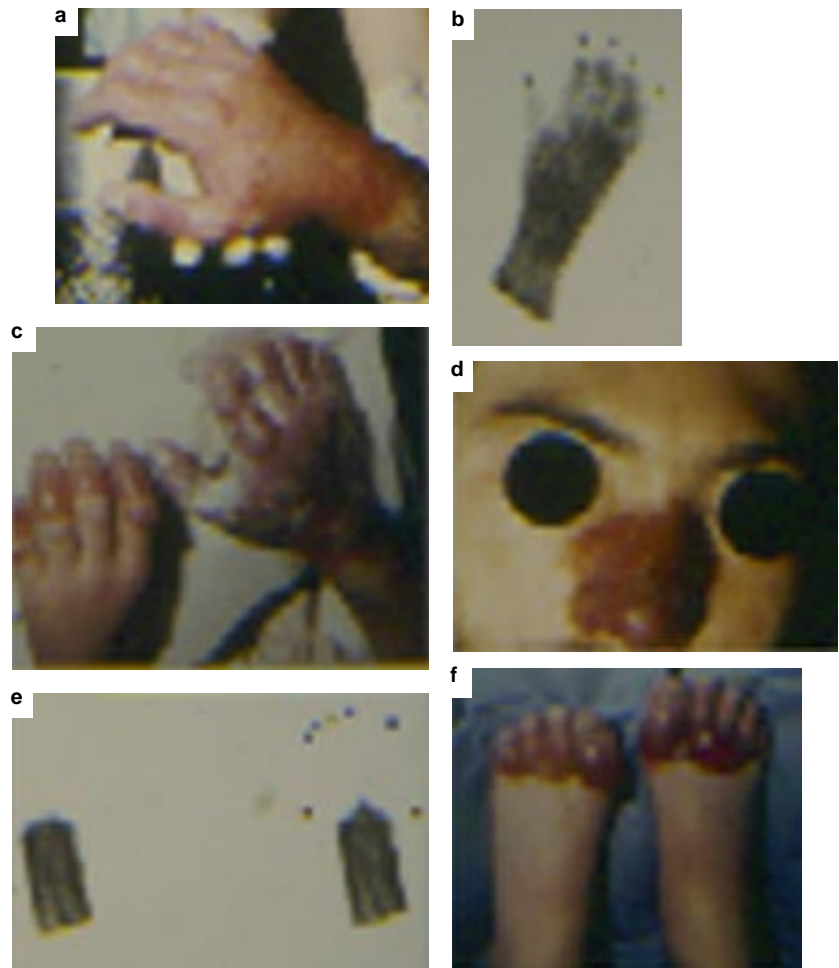


Atlas Fig. 26. Hypothermia and freeze–thaw–refreeze injury. (a) The home of a street person in an alder thicket. He was determined to be mentally incompetent. (b) Severe frozen feet after 10 days of freeze–thaw–refreeze injury on at least three occasions. The patient was found to be hypothermic (27.6°C, 81.7°F), with a blood glucose level of 900 mg/dL. He was warmed by peritoneal dialysis and, simultaneously, his frozen extremities thawed in a Hubbard tub. (c) Isotope technetium 99m studies of the feet demonstrated total block and failure of perfusion at the malleolar level. (d) At 72 hours after hospitalization, the feet were pulseless and lifeless, and gangrenous changes were seen to be developing in the toes. (e) Nine days after admission the patient developed evidence of acute bacterial sepsis and became febrile; a culture demonstrated overwhelming infection with *Proteus vulgaris*. A guillotine low-level amputation was performed.

Atlas Fig. 27. Freezing injury, with substance abuse, hypothermia, and vascular occlusion. A 25-year-old victim with frostbite to the face, hands, and feet was found semiconscious in a snow gully near a broken-down snowmachine. He was taken to a hospital in Anchorage, Alaska, 8 hours after rescue. On arrival at the emergency department, his core temperature was 86°F (33°C). His exposure time was said to be 12 to 18 hours; ambient temperature in the accident area: -4°F (-40°C); wind: 15 mph and gusting; wind chill factor: -85°F to -90°F.

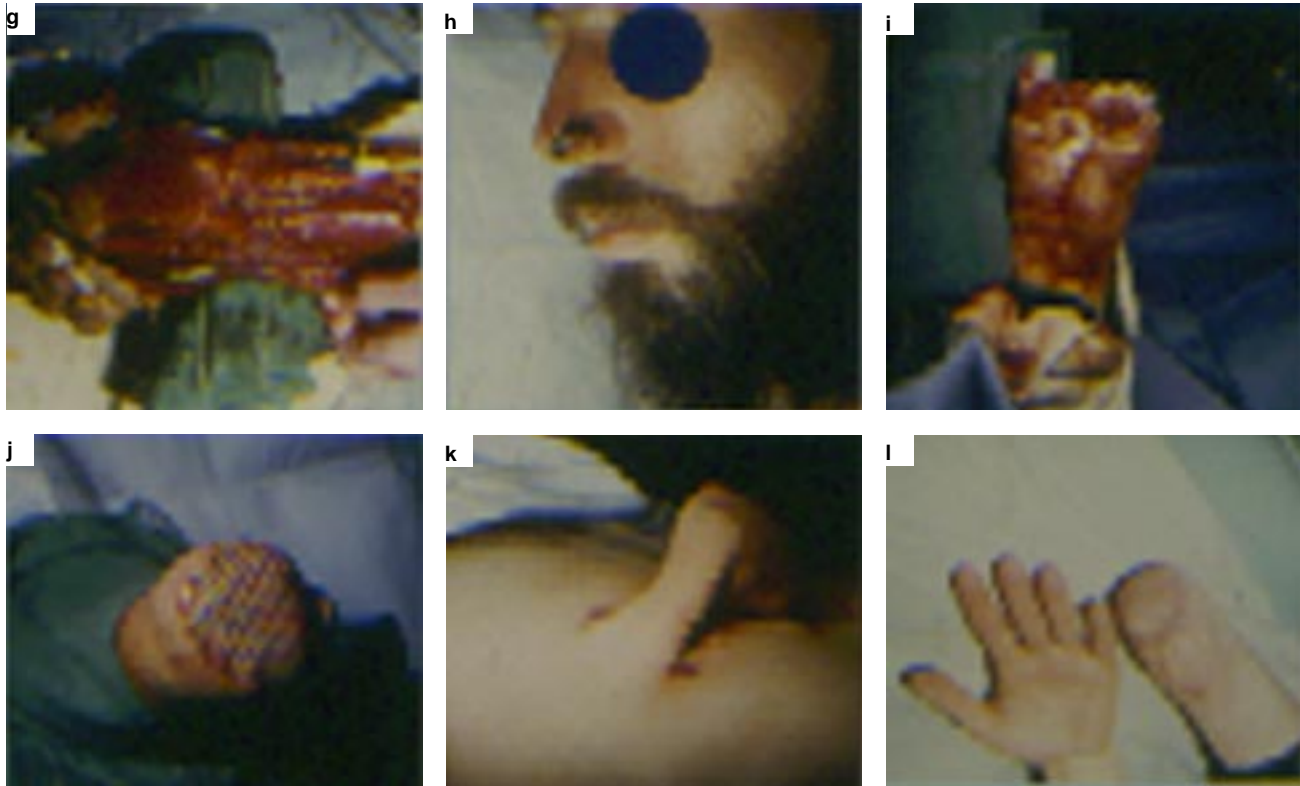
(a) The victim was found with the right sleeve of his coverall rolled tight over the mid forearm and frozen to the arm, giving a total tourniquet effect for the time he was lying in the snow. He was warmed in the field with warm blankets; and in the emergency department with a circulating warm-water blanket; warm, moist, inspired air; and brought to normothermia in a warm whirlpool Hubbard tank at 90°F (ie, he was rapidly rewarmed in warm water). A toxicology screen in the emergency department demonstrated a positive test for cocaine. (b) A technetium isotope (T99m) scan of the right hand and wrist made on admission demonstrated perfusion almost to the fingertips. Compartment pressures taken on the same day varied in the hand between 37 and 52 mm Hg. The hand was warm and, based on the T99m scan, appeared to have adequate perfusion. This evaluation is believed to have been marginal for a fasciotomy (c) The right hand is thickened, edematous, totally insensitive, and rapidly cooling.

(d) The nasal frostbite appears related to the victim's face-down position in the snow after the accident and aggravated by his snorting of cocaine the evening of the accident. The vasoconstriction of the nasal tissues—apparently secondary to (1) the severe contact with cold, snow, and ice, and (2) cocaine use—allowed increased tissue cooling. (e) A repeat T99m scan revealed no cellular perfusion distal to the wrist, a marked change in 3 days; the clinical change occurred in the last 6 hours of that time. (f) Adequate response to treatment was present in the feet, here demonstrated on the fourth day after the injury; T99m scan of the feet that day revealed adequate capillary perfusion.



(Atlas Fig. 27. continues)

Atlas Fig. 27. continued



(g) Having demonstrated an increase in fascial compartment pressure of the hand, a fasciotomy of the mid palm was performed, demonstrating ulnar and radial artery occlusion. Clots were evacuated by small catheters and treatment instituted with a thrombolytic enzyme, slow-drip streptokinase. Massive bleeding resulted 3 hours postoperatively throughout the hand and operative site.

(h) The resolution of the nasal injury was present by the second week with the return of vascular supply. Treatment consisted primarily of the intermittent warm soaks as well as Dibenzylidine* therapy (10 mg, orally, b.i.d.) utilized for treatment of all frostbitten areas.

(i) Because of sanguineous changes in the wrist (see [g]) and necrosis of all tissues, including blood vessels, open-pack amputation above the wrist was performed, with a split-thickness graft further added 2 weeks after the amputation. (j) The open, granulating stump was closed 3 weeks after the amputation. (k) A cross-abdominal, full-pedicle flap was applied to the forearm amputation 2.5 months later. (l) The final result was less than desirable. The severe loss of tissue and right hand amputation was considered the result of 12 to 18 hours of vascular occlusion to the hand, the depth and duration of freezing, and the failure to relieve the distal vascular tree artery and vein of severe clotting.

*phenoxybenzamine hydrochloride; mfg: SmithKline Beecham, Philadelphia, Pa

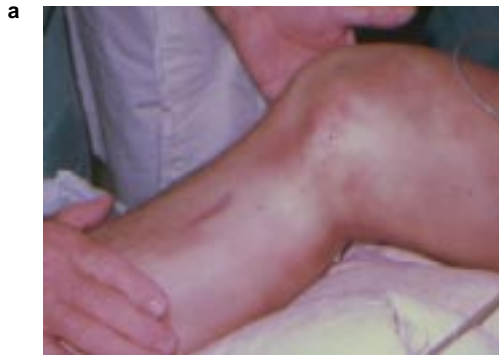SURGICAL PROCEDURES

ATLAS EXHIBIT 10

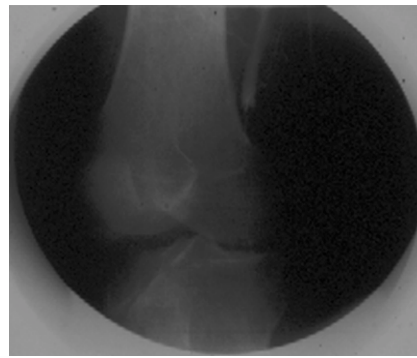
FREEZING INJURY: SURGICAL PROCEDURES

1. Escharotomy, escharectomy
2. Bleb, bullae, wound debridement
3. Fasciotomy
4. Arteriotomy
5. Vascular wound repair
6. Dermal graft procedures:
 - Reverden (Davis) pinch graft
 - Split-thickness skin graft
 - Split-thickness skin graft (mesh)
 - Free, full-thickness skin graft
 - Cutaneous pedicle flap graft
 - Muscle, musculocutaneous vascular flap transfer
 - Very early digital debridement with vascular cutaneous flaps
7. Controlled subcutaneous balloon tissue expansion
8. Guillotine amputation, modified as necessary
9. Closed amputation, with closed suction irrigation
10. Closed or open reduction of fractures and dislocations
11. Joint contracture releases
 - Joint excision and replacement
 - Joint fusion
12. Soft-tissue web-space releases
13. Surgical regional sympathectomy
14. Periarterial, microdigital sympathectomy
15. Excision of sinus tract
 - If necessary, radical excision of squamous cell carcinoma within the sinus tract
16. Tissue compartment releases
 - Carpal, tarsal tunnel syndrome

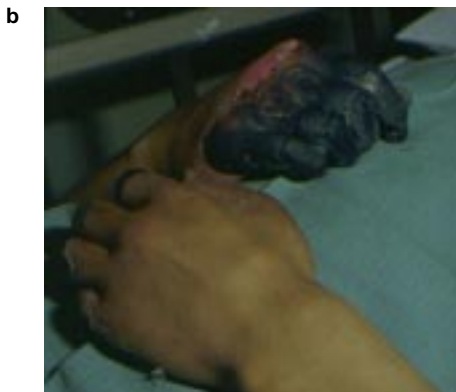Atlas Fig. 28. Multiple surgical procedures are required in patients with freezing associated with multiple severe injuries. Late in May 1979 a climbing party of three fell approximately 2,000 to 3,000 ft (600–900 m), roped together, from a cornice of the west rib of Mount McKinley. Two died in the fall. The survivor was found hanging head down, a rope wrapped about his right knee and thigh. A University of Alaska research camp was sited at 14,000 ft (4,267 m). The fall was observed from the camp at approximately 10 PM. The medical research party reached the victims about 6 hours after the fall. The surviving climber was carried back to the 14,300-ft base camp and examined there by a physician climbing with another party. The patient was placed in a tent, where examination found him to be semicomatose and delirious.



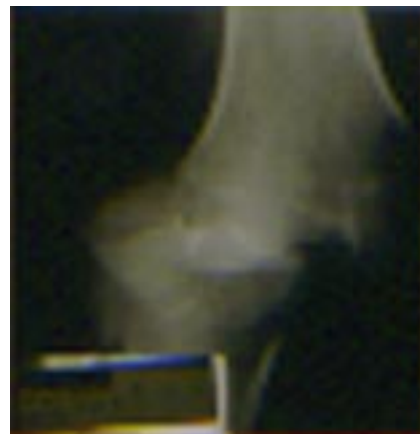a. Frozen right leg to distal femur, thawed by rapid re-warming.



c. The arteriogram demonstrates a vascular occlusion or arterial tear at the level of the distal femoral artery.



b. In the process of helicopter rescue (ambient temperature near 0°F) the patient lost his right hand cover. The wind generated by the chopper blades caused further cold injury to the already chilled climber.

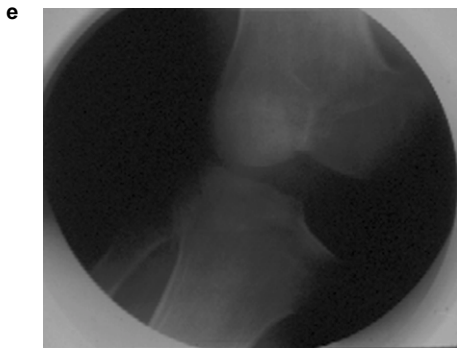


d. The roentgenogram demonstrates the lateral tibial plateau fracture.

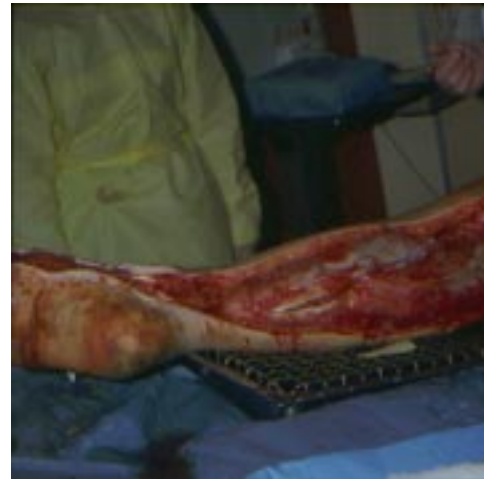(a) The patient had an obvious dislocation of the right knee with freezing of the hands and feet. (b) The hands began to thaw in the tent so that rapid rewarming was carried out. The right leg was packed in ice not only to prevent thawing but also because of the extent of the injury. Helicopter rescue was carried out approximately 20 hours after the fall.

On admission to the hospital in Anchorage, the patient was found to be semicomatose; both hands were thawed and were now edematous, cyanotic and still cool. X-ray examination demonstrated probable fracture of vertebra L2, and (c) an angiogram eventually revealed an obstruction of the popliteal artery 3 cm above the knee joint. (d) A lateral tibial plateau fracture was identified, with clinical evidence as well confirming a medial dislocation of the femur on the tibia. Rapid thawing of the right and left lower legs was performed in the emergency room with warm water and warm packs.

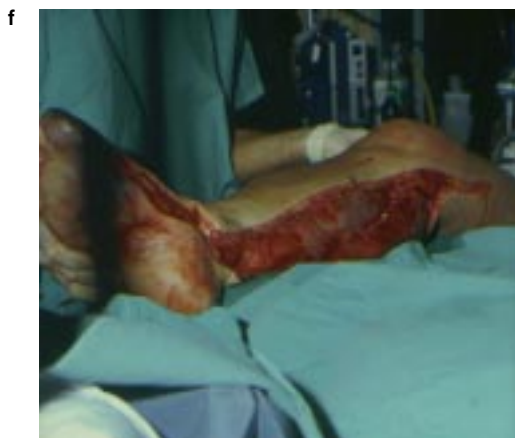Atlas Fig. 28. *continued*



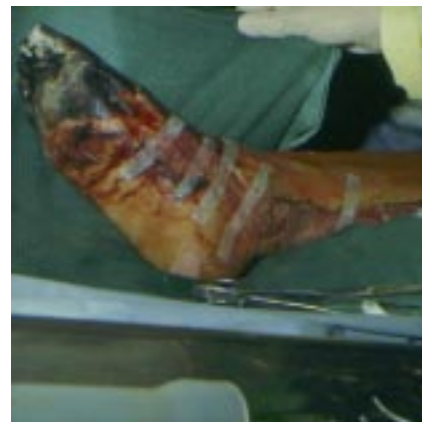e. The radiograph of the frozen knee reveals the dislocation and loss of medial knee structures



g. Demonstration of viable muscle in the distal lower leg.



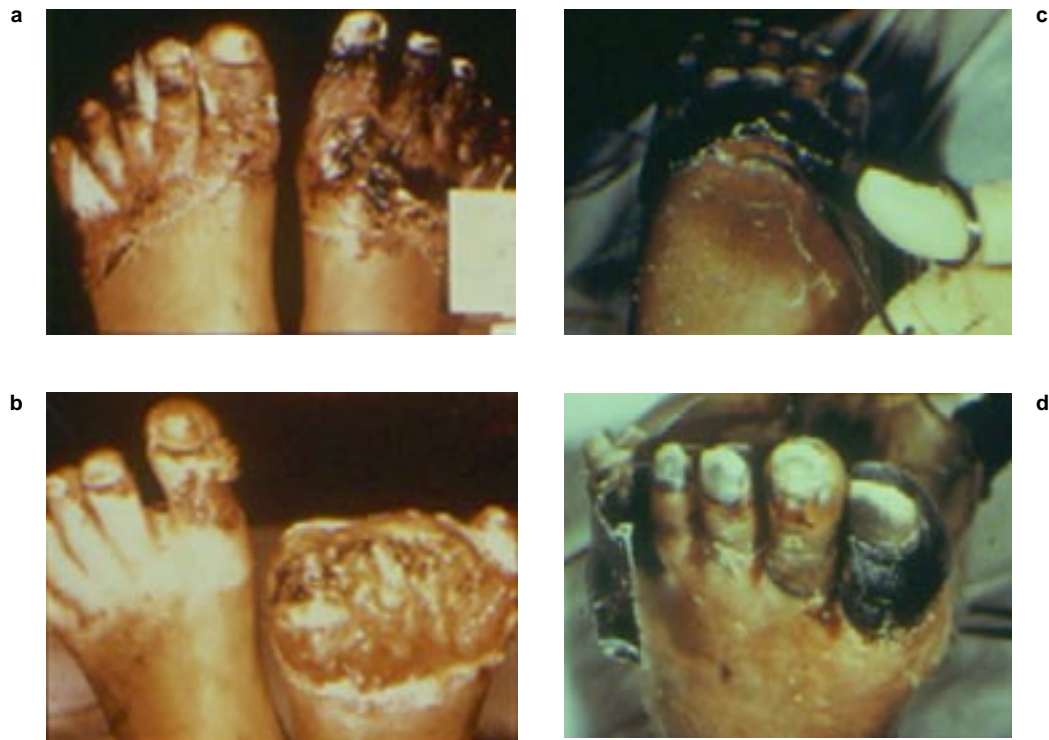f. Extent of postoperative fasciotomy and compartment pressure release with return of distal circulation after arteriovenous graft.



h. Final demarcation 3 weeks after repair of the knee structures and fasciotomy.

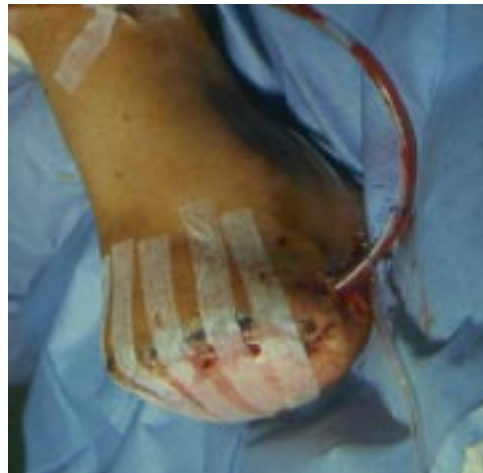After thorough evaluation, the patient was brought to surgery and the completely thawed right leg then examined. The right lower leg was cold, edematous, and pulseless well about the knee. At the same time, a puncture wound of the right groin was found with multiple lacerations of the common femoral vein, caused by an accidental ice axe penetration during the fall. (e) At the time of surgery, the capsule of the right knee was found to be totally destroyed. The popliteal artery was contused and occluded, with subadventitial hemorrhage present. The injured, occluded artery was resected, and a 6-cm saphenous vein graft was taken from the left groin and sutured in place. (f) The fasciotomy, after arterial repair, was extensive and deep, revealing that tissues in the posterior compartment of the calf and distal femur were quite swollen and edematous. A necrotic segment of the gastrocnemius was resected. (g) Despite the 22 hours that elapsed from the time of injury (including the popliteal occlusion and laceration) to the time of rescue, the result was considered good, with tissue loss limited to toes at the metatarsophalangeal joint level. It is considered that by having the right leg frozen to the level of the tibial tuberosity and cool well above that, the metabolic needs of the extremity were minimized despite the laceration of the popliteal artery. The “metabolic ice-box” state may have allowed preservation of tissue and, along with the extensive fasciotomy, avoided compartment pressure injury and destruction of muscle, vessels, and nerves.

(h) At 3 weeks after the injury, the area of fascial release was covered with split-thickness skin graft, and the patient transferred to his native country for further care.



Atlas Fig. 29. Regardless of the thawing method, premature debridement through (a) wet, edematous, often infected tissues, including regional amputations, often results in (b) retraction tissues and a shorter stump.

Amputation is not always necessary, however. An elderly woodcutter, who sustained severe frostbite injury to his feet, was referred for transmetatarsal amputation. (c) Careful dissection of the gangrenous epidermal cover revealed healthy epithelializing tissue under the eschar, and (d) his foot remained intact. Photographs c and d were both taken in the operating room on the same day.



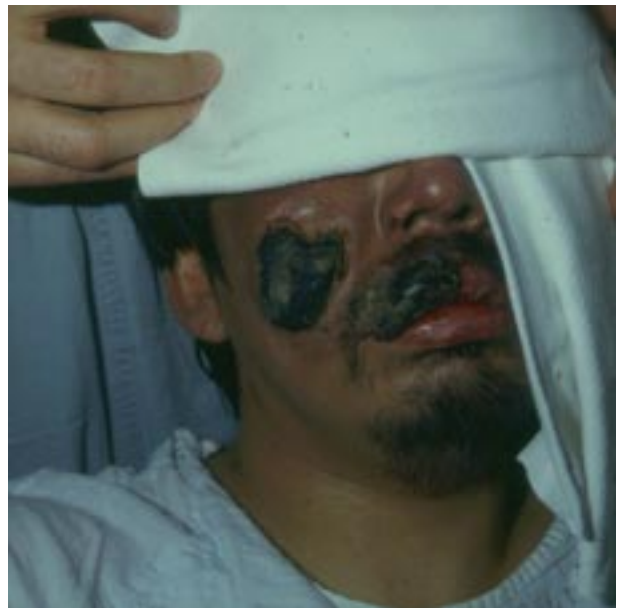Atlas Fig. 30. Because of gangrenous and necrotic tissues, amputation (other than guillotine) at any level is followed by closed suction irrigation for 5 to 7 days.

UNUSUAL PRESENTATIONS

a



b



Atlas Fig. 31. Unusual presentations of freezing injuries. **(a)** A freezing injury, after contact with a bedspring and consequent loss of skin and superficial structures upon rising from the bed. Treatment: debridement and mesh graft care (not shown). **(b)** This Alaskan hunter was lost in a blizzard for 3 days with his face unprotected. Deep freezing of the right cheek and lips occurred. The freezing of the cheek has caused necrosis of a segment of the maxillary sinus, through the upper jaw and into the oral cavity.

SEQUELAE OF FREEZING COLD INJURY

ATLAS EXHIBIT 11

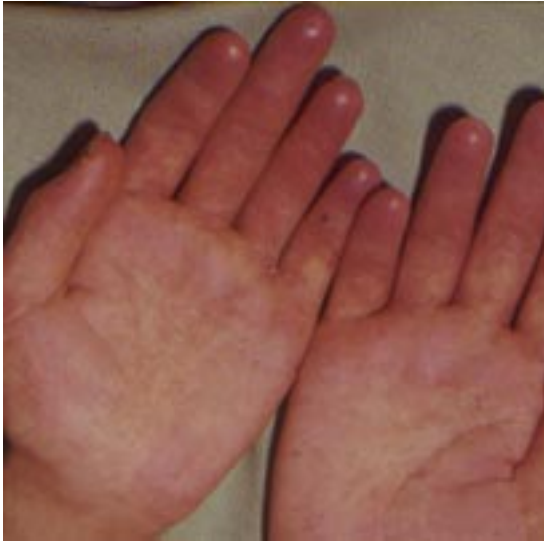SEQUELAE OF FREEZING COLD INJURY

Transient, early signs:

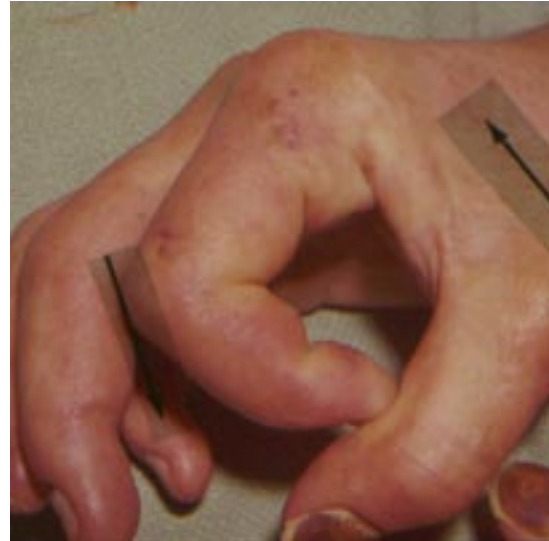- Hyperhidrosis
- Hypesthesia or anesthesia of digits
- Limitation of motion in interphalangeal and metatarsophalangeal joints
- Swelling in interphalangeal and metatarsophalangeal joints
- Edema
- Thin, fragile epidermis in involved areas
- Nail loss
- Intrinsic muscle atrophy
- Fat pad atrophy of the distal tips

Long-standing, usually permanent signs:

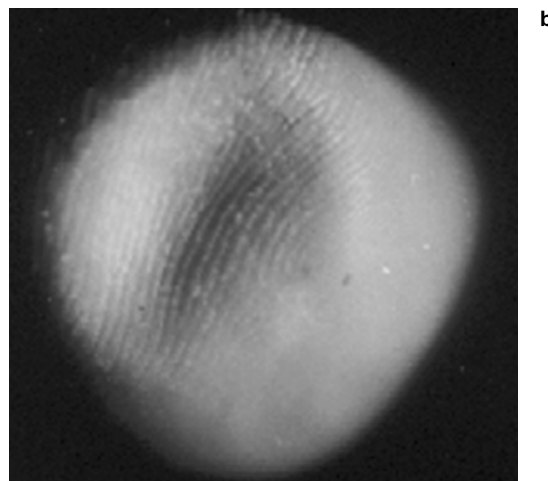
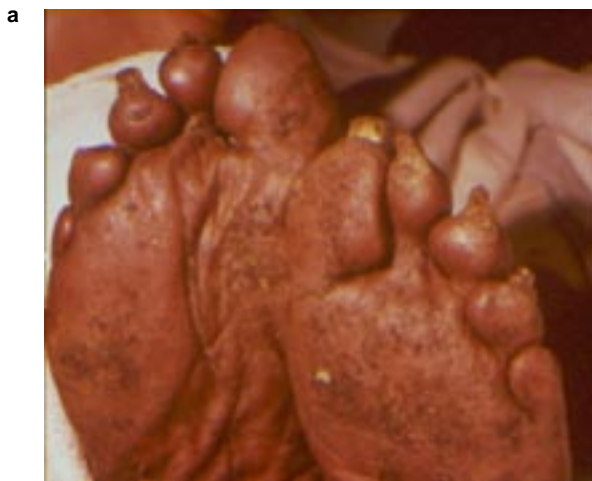- Deep, fixed scars over the affected areas
- Atrophy or fibrosis of intrinsic musculature
- Contracture of digital joints (eg, hammer toe, claw toe)
- Loss of volar fat pad
- Hyperesthesia; digital tips with increased sensitivity to heat or cold
- Decreased proprioceptive sense of the digital tips
- Permanent nail deformity
- Roentgenographic evidence of periarticular and subarticular lytic destruction of bone and cartilage, especially of the phalanges
- Avascular necrosis of bone, especially of phalanges, metatarsi, and tarsi
- In children, epiphyseal necrosis or total destruction, with joint and phalangeal deformity, angulation, or shortening
- Chronic ulceration, infection, and osteomyelitis
- Decreased capillary perfusion
- Rarely, squamous cell carcinoma in a persistent sinus tract
- Interphalangeal joint immobility or fusion
- The ultimate of long-standing sequelae: amputation



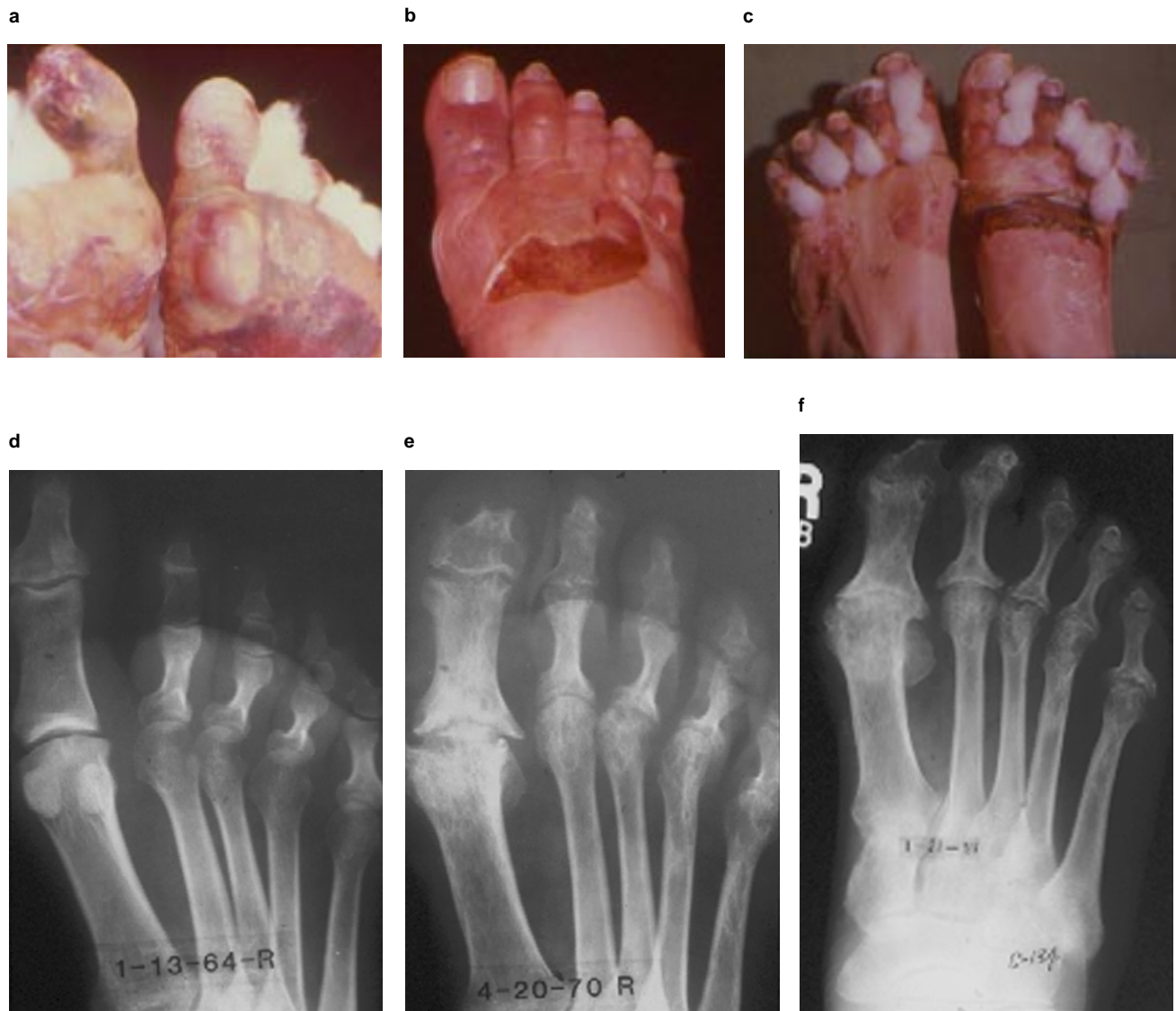Atlas Fig. 32. Hyperhidrosis, a sympathetic nerve response, is sometimes a transitory sequela of freezing and thawing in superficial frostbite, but in deeper frostbite is often a permanent sequela.



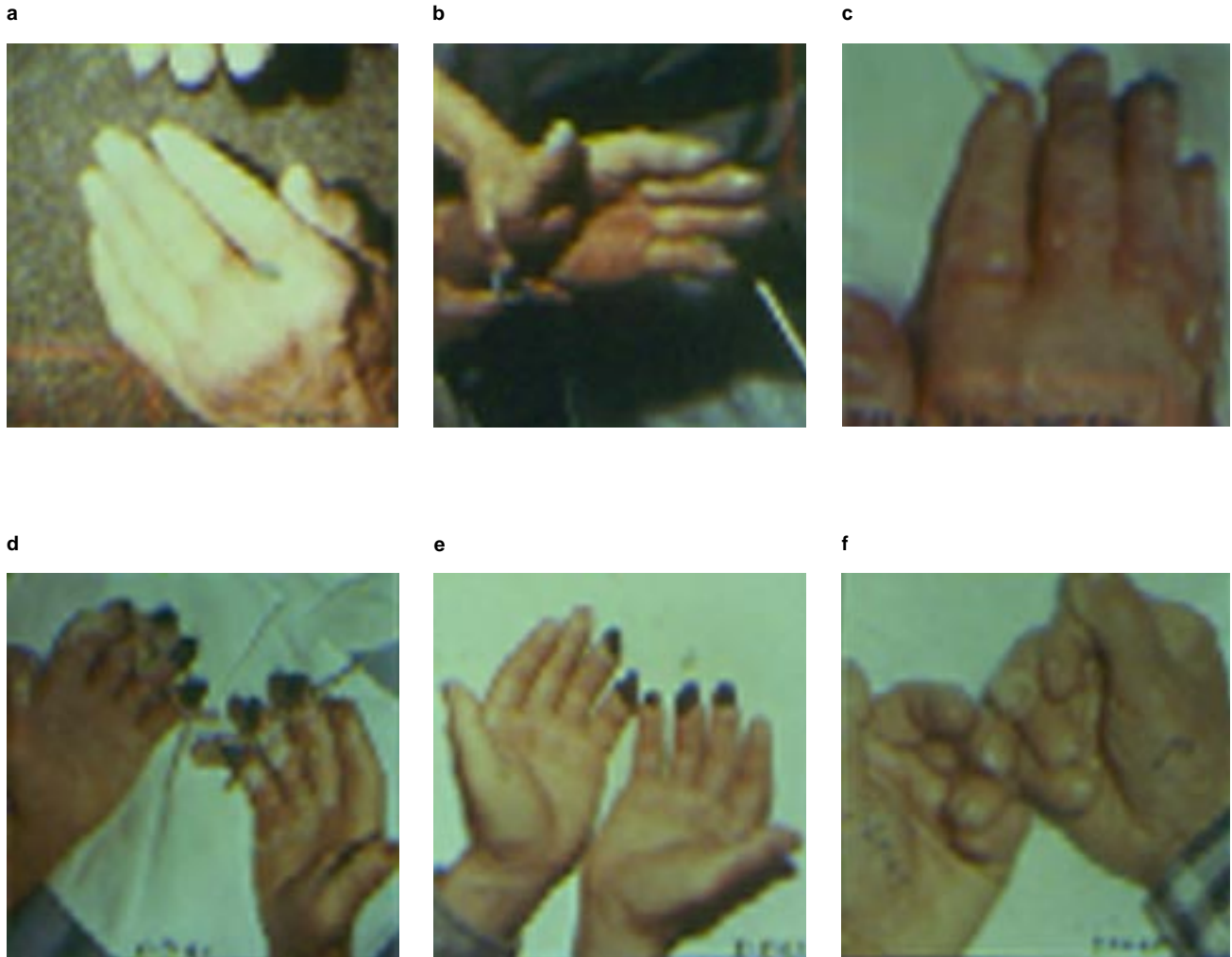Atlas Fig. 33. Early and permanent loss of intrinsic muscle (first dorsal interosseus) and fat pad loss (volar fingertips), both demonstrated by arrows.



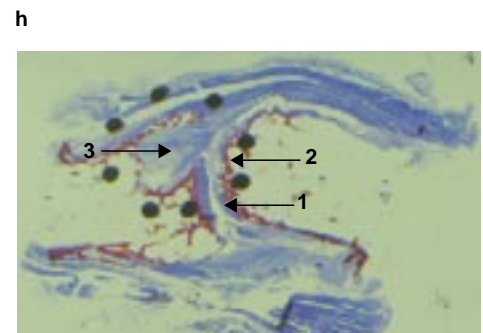
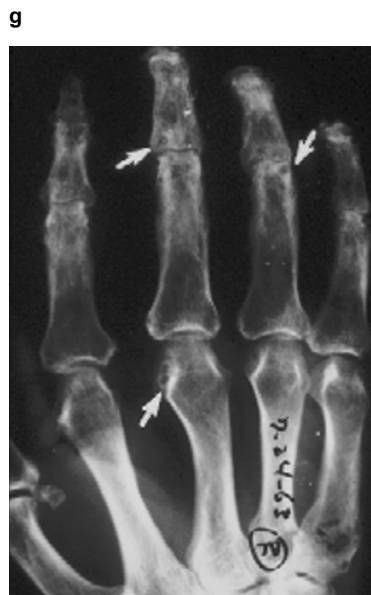Atlas Fig. 34. (a) An Alaskan “sourdough,” who came to the Yukon in 1901 and worked as a cook in gold camps, had frostbite on “lots of occasions.” He treated each episode with cold or warm coal oil, a common Alaskan home remedy. He had evidence of multiple injuries: bulbous digital tips, fat-pad loss, and osseous atrophy. (b) Usually after any frostbite of the digital skin (even mild), loss of the fat pad of volar digits (here, a thumb) occurs. This loss also may occur after exposure over years to winter workers or sports people, especially those handling tent poles, lines, or other cold materials at low temperatures.



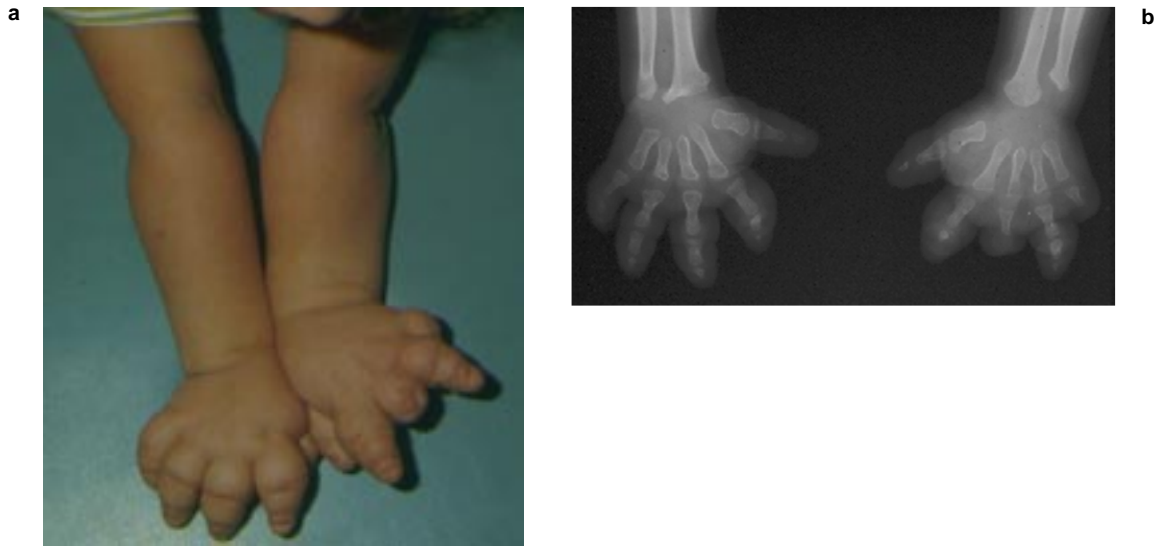Atlas Fig. 35. Immersion and bilateral freezing, followed by rapid rewarming. After hip-high immersion in a creek, the victim walked back to his car (ambient temperature: -5°F [-20°C]; exposure: 3–4 h) and partially warmed his feet in his vehicle. Both feet were frozen, particularly the dorsum of the right foot. Rapid rewarming in warm water was carried out in the hospital. (a) After rapid rewarming following cold exposure of 3 to 4 hours, large, pink, distal blebs formed—a good prognostic sign. (b) The right foot, 10 days after the thaw. (c) At 3 weeks after the injury, viable tissues are present below the epidermal eschar; full-thickness loss is seen on the right dorsum. The eschar eventually sloughed and a mesh graft was applied to the remaining defect, which healed 10 days later. (d) A roentgenogram taken 7 weeks after the injury reveals no definite degenerative changes in the phalanges. (e) A roentgenogram taken 6 years after the injury reveals that lytic destructive changes are present in the distal joints and that osteocartilaginous destruction with marked joint limitation is present in the first metatarsophalangeal joint. (f) A roentgenogram taken more than 30 years later (36 y postinjury) reveals loss of joint surface in all metatarsal joints and narrowing of the interphalangeal joints. (g) A photograph taken the same day as the preceding roentgenogram shows the patient’s typical loss of intrinsic muscle, swelling of the interphalangeal joints, mild hammer toe deformity, nail-bed deformity, early onychogryphosis, and onychomycosis.



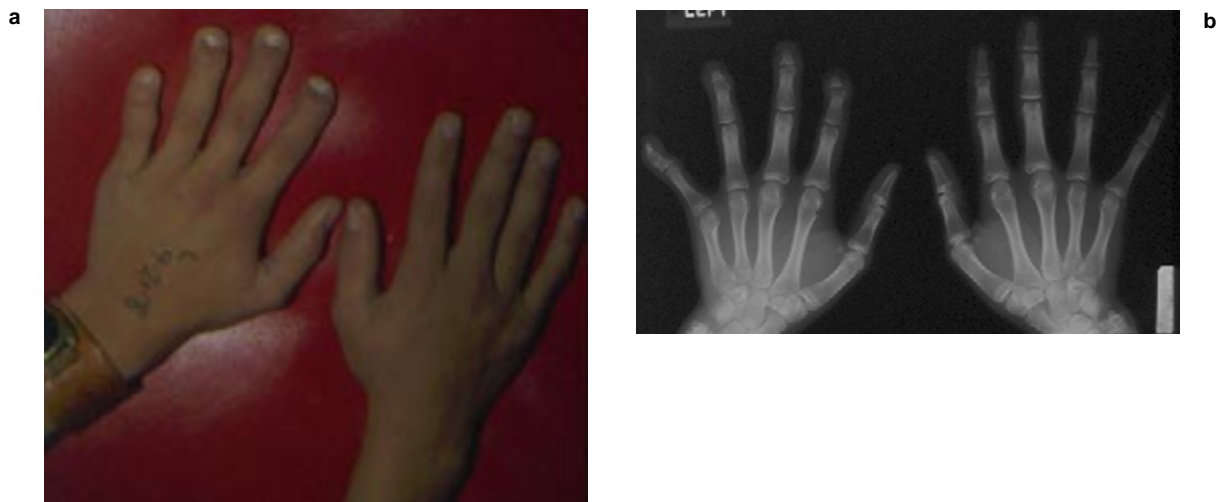
Atlas Fig. 36. Interrupted rapid re-warming in warm water. (a) Hard, cold, immobile, frozen hands (bilateral) were thawed in warm water (106°F) for less than 20 minutes. (b) Because of the second onset of a cardiac episode, warming was stopped before fingertips were flushed. (c) One hour postthaw, proximal blebs and cyanotic fingertips can be seen. (d) Two months postthaw, the fingertips are gangrenous. (e) Five months postthaw, mummification and separation of necrotic tissues can be seen. (f) Two and one-half years postthaw, the hands demonstrate flexion contractures of the interphalangeal joints, nail deformity, and intrinsic muscle atrophy. (g) The arrows on this roentgenogram made the same day (2.5 y postthaw) point to narrowing of joint spaces (cartilage necrosis) and lytic destructive changes of bone.



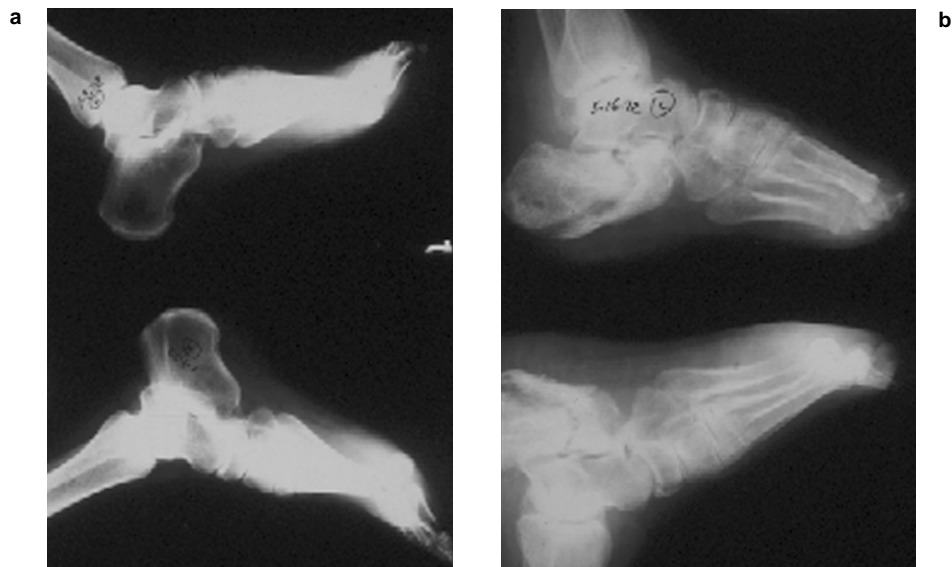
(h) The following findings were made at a postmortem biopsy of the proximal phalanx mid finger, right hand (trichrome stain) of the same patient, 15 years after the frostbite injury: (1) degenerative articular cartilage, (2) segmental destruction of subarticular bone proximal interphalangeal joint, and (3) periosticular destructive lytic lesion of bone with invasion of joint surface by dense collagenous tissue.



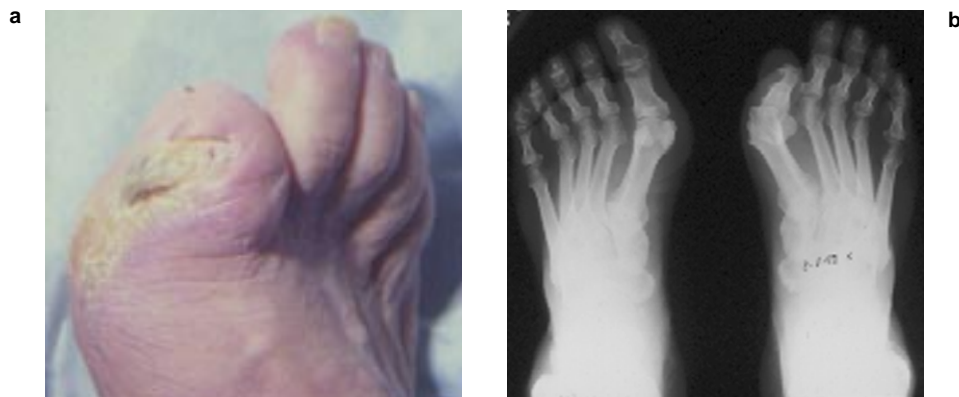Atlas Fig. 37. A 4.5-month-old infant was found outdoors wrapped in a blanket; ambient temperature -30°F . The infant had severe hypothermia (core temperature $< 70^{\circ}\text{F}$) and the hands and feet were frozen; thawing was accomplished in a warm water bath. The epiphyses of both hands and wrists sustained injury, and the infant suffered severe hypermobility of joints. (a) This photograph was made when the child was 5 years of age; only the long flexors and extensors of the hands are functional. All intrinsic musculature of the hands has been destroyed. (b) A roentgenogram, made when the child was 8 years of age, revealing the absence of the carpals and digital epiphyseal necrosis with phalangeal shortening. An arthrogram of the wrists demonstrated total absence of cartilage as well as bone. This roentgenogram demonstrates the total epiphyseal lytic destruction of all carpi bilaterally and all epiphyseal plates of the interphalangeal joints. More than 20 years after the injury, the patient's hands had not grown since they were frozen at age 4.5 months.



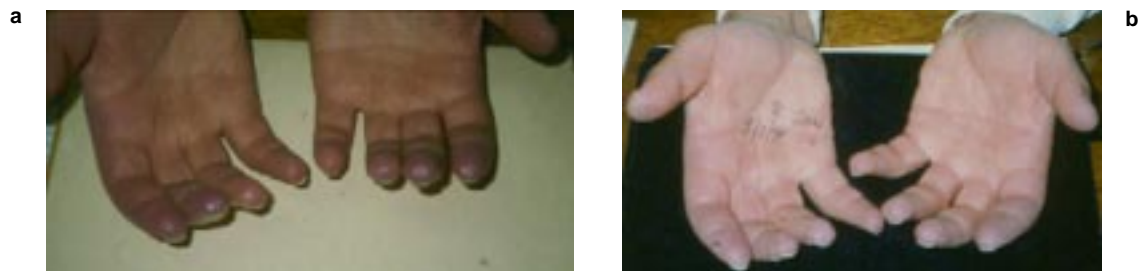Atlas Fig 38. Resultant epiphyseal necrosis from freezing. While carried in an infant "backpack" carrier, an infant younger than 6 months of age lost the protective glove from his left hand. The incident occurred in the vicinity of Point Barrow, Alaska, where freezing injuries can occur in less than 1 minute at -50°F . (a) Epiphyseal necrosis 12 years later. Note on the left hand the mild length discrepancy, ulnar deviation, and distal digits at the interphalangeal joints. (b) A roentgenogram of the same patient on the same day demonstrates distal digital atrophy and distal interphalangeal epiphyseal necrosis.



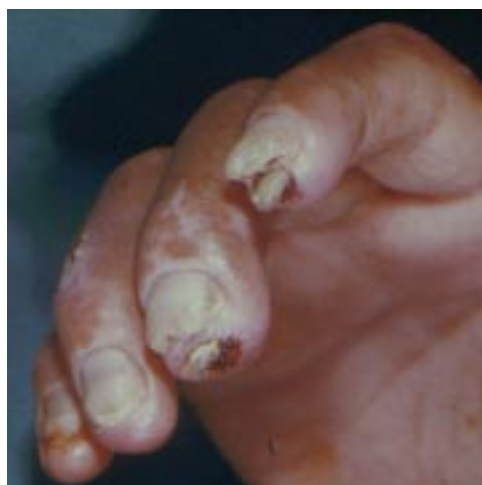Atlas Fig. 39. An individual with alcoholic peripheral neuropathy was unaware of his freezing injury on a snowmobile trip until his toes mummified 3.5 weeks later (the thawing was probably spontaneous). (a) The roentgenogram taken 3.5 weeks after the injury demonstrates the appearance of osteoporotic calcanei and amputation of the distal digits. (b) Unexpectedly, avascular changes with collapse of calcaneal structures occurred. Owing to the peripheral neuropathy, the bony changes were asymptomatic. A roentgenogram taken 4.5 months later (5.5 mo postinjury) demonstrates gradual development of severe, avascular necrosis of the calcanei and tarsal joints (generally, degenerative changes are not seen so soon after the freezing injury). The patient eventually required triple arthrodesis of both feet.



Atlas Fig. 40. Changes in the large toe are evident 23 years after the feet were frozen in dogsled travel in interior Alaska, with multiple-day exposure. (a) General destruction of interphalangeal joint toe I, and subluxation of metatarsophalangeal joint after osteonecrosis. Severe onychogryphosis is present. (b) Roentgenographic evidence of subluxation, metatarsophalangeal joint, large toe, destruction of segment of intact phalanx and interphalangeal joint.

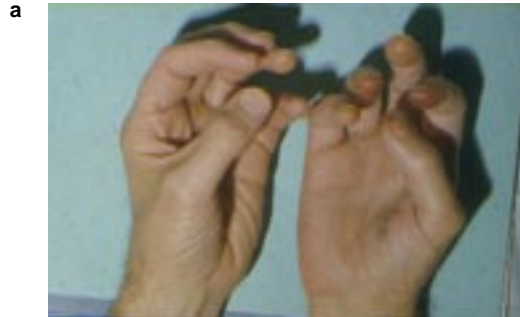

Atlas Fig. 41. (a) Six months after superficial frostbite at subzero temperatures, the patient still has chronic cyanosis of the fingertips. (b) The patient developed a labile vasomotor hand problem, occasionally “spitting” out calcific pieces from fingertips (see the ring fingertips of both hands). Now the patient is extremely sensitive to cold.



Atlas Fig. 42. Necrosis of fingertips and extrusion of the distal phalanx almost 2 years after an Aleutian fisherman’s immersion injury followed by freezing injury. This patient carried on his usual activity as a fisherman after he recovered from his injury, even ignoring the drainage from the localized osteitis of bony tips. Eventually he was brought to the Alaska Native Hospital with appendicitis, during which time the extended bony segments were excised and the wounds closed over small, transverse drains.

SPACE-AGE THERMAL INJURIES



Atlas Fig. 43. Nonterrestrial high-altitude cold injuries are sometimes seen now that astronauts venture into space, where temperature extremes of hot and cold are far greater than those seen on Earth. This astronaut's hands, despite protective gloves, sustained superficial freezing injury at an extravehicular temperature near -143°F while training at the National Aeronautics and Space Administration facility at Houston, Texas. He was treated there with rapid rewarming. **(a)** Three weeks after the injury the astronaut was transported to Alaska for further treatment. His isotope studies demonstrated excellent capillary perfusion of all digits. In this view, he is demonstrating the recovered range of motion in his hands; the discoloration seen in the fingertips of the right hand is temporary. **(b)** Almost a year after the injury and wearing newly designed gloves, the astronaut (Storey Musgrave) was able to go into space and perform extravehicular work on the Hubble space program telescope without recurrent injury.

