

INFECTION
Hematopoietic

FLUID LOSS
Gastrointestinal

IRREVERSIBLE
Neurovascular

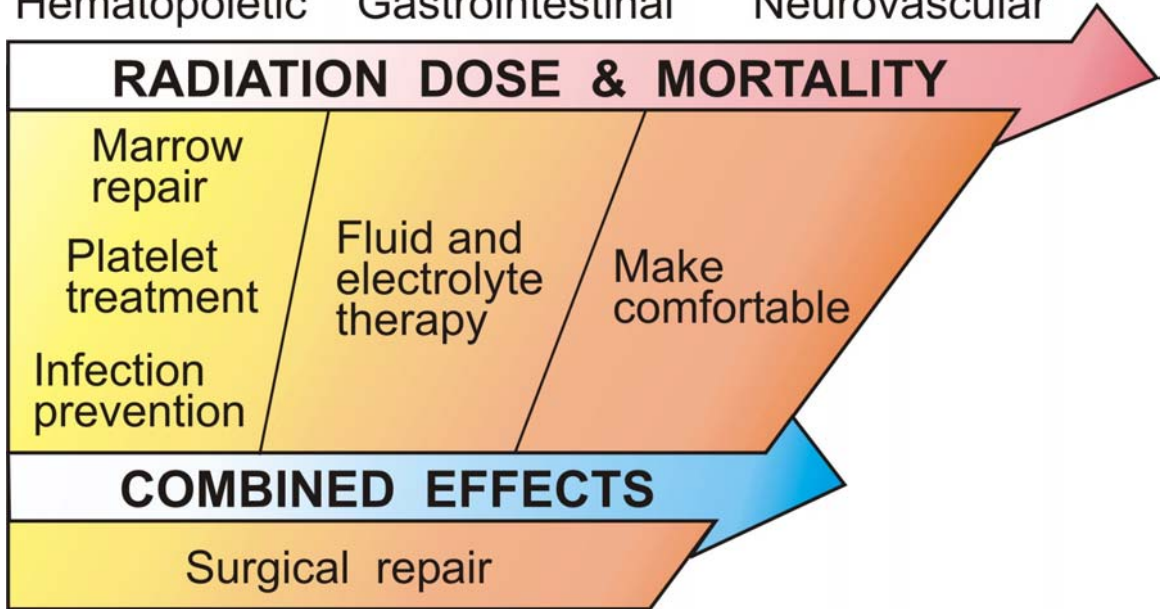


Figure 1-4. Major acute radiation subsyndromes after injury to bone marrow, intestine, or neurovascular system

[Back](#)