

# APPENDIX 1

## BONE SCAN IMAGING OF STRESS INJURIES IN THE RECRUIT

PETER BLUE, MD\*

---

### INTRODUCTION

### COMPARING RADIOGRAPHS TO BONE SCANS IN 100 PATIENTS

Materials and Methods

Results

Discussion

### INTERPRETIVE SCHEMES

### ATLAS OF BONE SCAN IMAGES

Techniques

Figures

### RECOMMENDED READING

\*Colonel, Medical Corps, US Army, (Retired); Chief, Nuclear Medicine Service, Moncrief Army Hospital, Fort Jackson, South Carolina 29207; Clinical Professor, University of South Carolina School of Medicine

## INTRODUCTION

Stress injuries occur frequently in the recruit population. Most of them can be diagnosed clinically without a need for imaging procedures. Nevertheless, at Fort Jackson, South Carolina, a large basic training base, more than 3,000 scintigraphic bone scans are performed yearly to diagnose stress injuries. Often a bone scan may be useful to define the extent of the lesion, as well as to elucidate other silent lesions or secondary lesions that have developed secondary to splinting from the primary lesion. Tertiary findings, such as disuse, may be useful in otherwise negative studies to help separate malingerers from trainees with true stress injuries.

The majority of treatises on stress fracture imaging suggest plain radiography as the starting point, followed by bone scintigraphy if the radiograph is negative but the index of suspicion is high. These same articles, however, acknowledge that the radiograph is rarely positive less than 3 weeks after the onset of pain. Some studies report that 10% to 25% of bone-scan-positive stress fractures are also positive on the radiographs; others report a sensitivity of as high as 68% when the radiographs are compared to bone scans

as the gold standard. The population being studied is critical to the result. The more acute the stress fracture, the less likely the radiographs will be positive. In spite of these studies, plain film radiography is frequently obtained for acute stress injuries, and the diagnosis is delayed.

In the nonrecruit population, people often exercise until pain causes them to reduce or discontinue their exercise program, restarting again at a later date. By the time the patient reaches a healthcare provider, several months may have passed, and callus formation or periosteal new bone may be visible on the radiographs.

More recently, MRI imaging has been touted as the new gold standard, supplanting scintigraphic bone scan imaging; MRI has the same 100% sensitivity but with a much better ability to localize the actual lesion. Possibly, MRI may be beneficial in the evaluation of femoral neck stress fractures as to presence and extent.

This appendix will address the usefulness of obtaining bone radiography during the early phases of basic training and present a selection of the myriad stress injuries that occur in this unique population.

## COMPARING RADIOGRAPHS TO BONE SCANS IN 100 PATIENTS

To evaluate the correlation of radiographic findings to bone scan findings at Fort Jackson, the results of 100 consecutive patients referred for bone scintigraphy evaluation of possible stress fracture were recorded. Each patient was a recruit in the first 4 weeks of basic training. Each patient had a "hot" lesion on a bone scan consistent with a significant stress fracture, and each had had a plain radiograph performed prior to the bone scan. The radiographic reports were evaluated to determine the usefulness of plain radiography in this group of patients.

### Materials and Methods

All patients were imaged using 20 to 30 mCi intravenous Technetium-99m methylene diphosphonate (Tc-99m-MDP) as the bone scanning radiopharmaceutical. Anterior and posterior images of the pelvis and lower extremities were acquired in all patients. Foot/ankle images were acquired anteriorly, posteriorly, and laterally in all patients. Single photon emission computed tomography (SPECT) images were frequently obtained to rule out femoral neck stress fractures and other hip and pelvic pathology.

### Results

Of the 100 studies evaluated, 98 had normal plain radiography reported (Figure Appendix 1-1). Only two patient radiographs were reported as consistent with stress fracture.

### Discussion

A large population of recruits such as those at Fort Jackson may have more than 3,000 stress fractures evaluated yearly by bone scan. A similarly large population of permanent soldiers may have less than 100 studies performed over the same period.

The goal of the medical treatment facility is to evaluate the trainee as quickly as possible, sending those with stress injuries on to appropriate therapy and those without stress injuries back to duty with minimal lost training time. The use of plain radiography early after the onset of potential stress injury is nonproductive. The negative radiograph may delay diagnosis and may result in a recruit being returned to training with an undiagnosed stress fracture. This delay can result in progression to an actual fracture, dangerously in the case of a femoral neck stress fracture.

The use of MRI as a first-line imaging modality is neither cost effective nor time effective for basic trainees. MRI may be useful for secondary evaluation of possible femoral neck stress fractures and for primary evaluation among high intensity athletes; in both cases, immediate, specific localization may be important.

The nuclear medicine service must provide rapid turnaround when bone scans are requested, optimally rendering a report within 48 hours. Since plain radiography is so insensitive within the first 4 weeks of training (2% in this study), it is most prudent to image the recruit with a bone scan and to forgo the plain films during this

time. At Fort Jackson, all recruits are imaged at the pelvis and below, irrespective of the location of pain. It is very common to have multiple stress fractures, some of them silent. Spot images of the feet are also acquired as a part of every study to better localize the foot lesions that are so common in trainees. SPECT imaging is routinely performed in patients with hip and pelvic complaints, especially if the routine images are not obviously positive. In general, images above the pelvis are not acquired without specific complaints related to those sites. Restricting the imaging to the pelvis and below facilitates throughput and management of camera imaging time.

## INTERPRETIVE SCHEMES

A wide variety of grading systems for stress fractures based on the interpretation of bone scan findings are used. The following scheme is one of the simplest:

- Grade 0 Normal.
- Grade 1 Small, ill-defined cortical area of minimally increased activity.
- Grade 2 Better-defined cortical area of mild to moderately increased activity.
- Grade 3 Wide cortical-medullary area of increased activity.
- Grade 4 Transcortical area of increased activity.

Another grading scheme is the following:

- Grade 0+ Normal.
- Grade 1+ Faint activity.
- Grade 2+ Hotter than femoral shaft activity.
- Grade 3+ Hotter than sacroiliac joint activity on posterior images.
- Grade 4+ Fully black on scan.

The above scale has been modified using clinical terms to help the healthcare provider make clinical choices:

- Grade 0 No evidence for stress fracture seen.

- Grade 1 Minimal lesion seen. Clinical correlation is recommended to determine if further studies and/or treatment is needed. For minimal lesions in the knees, ankles, and feet, the finding "no other significant lesions seen" may include this type of lesions.
- Grade 2 Mild stress fracture seen. Clinical correlation is recommended to determine if further studies and/or treatment is needed.
- Grade 3 Significant stress fracture seen.
- Grade 4 Major stress fracture seen.

The use of some form of grading system is necessary, especially in recruits, so that those patients with significant lesions will be referred to therapy and withheld from training, and those with minor lesions may continue training with modifications. It is important to remember that most stress fractures will resolve upon completion of basic training. The goal is to have the greatest number of recruits complete training with the least amount of morbidity and lost training time.

Because of the possible consequence of an undiagnosed stress fracture proceeding to actual fracture, all pelvic, femoral neck, femoral shaft, tibial shaft, and fibular shaft stress fractures should be mentioned, even if they fall in the Grade 1 category.

## ATLAS OF BONE SCAN IMAGES

The most common sites for stress fractures in trainees, in descending order, are the metatarsals, tibia, knee joints, tarsals, calcanei, pubic rami (females), femoral necks, and sacroiliac joints. No part of the lower body

is immune from lesions. The majority of the following images were obtained over a 60-day period, selected from approximately 600 studies of 2,000 lesions. Of the 600, less than 60 studies were completely normal.

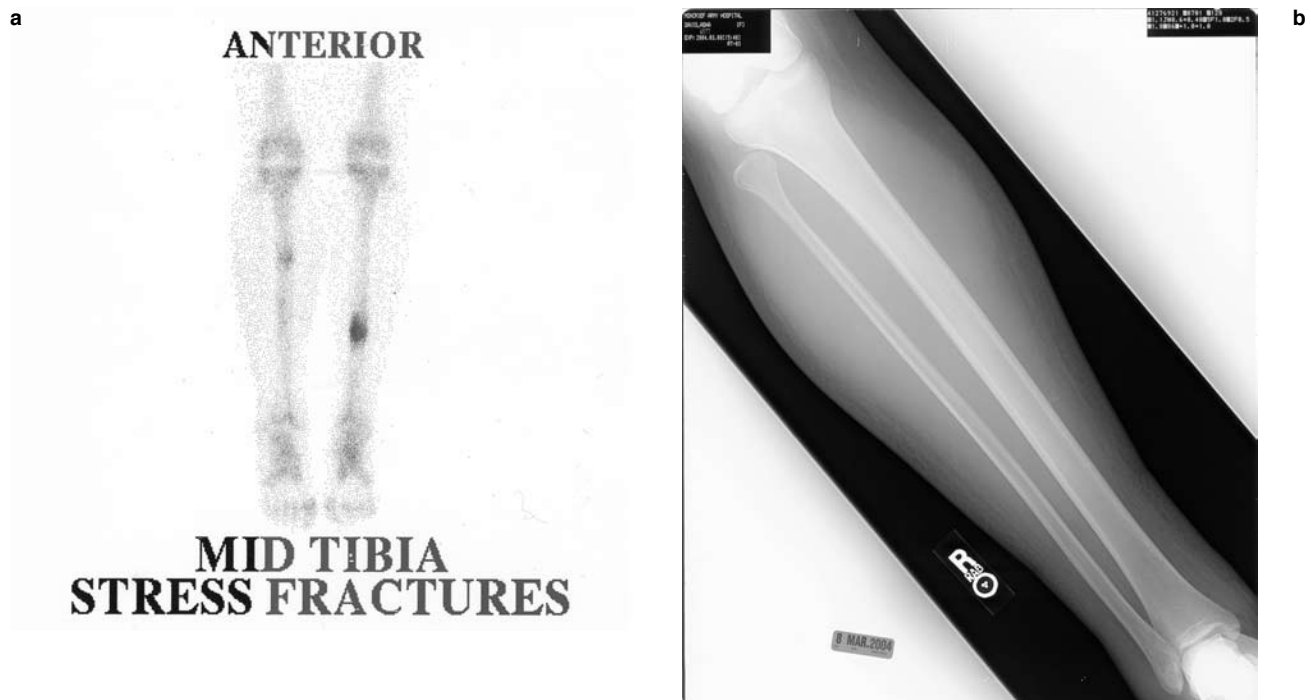## Techniques

The following procedures and agents were used for this atlas and are recommended for bone scan imaging in basic trainees:

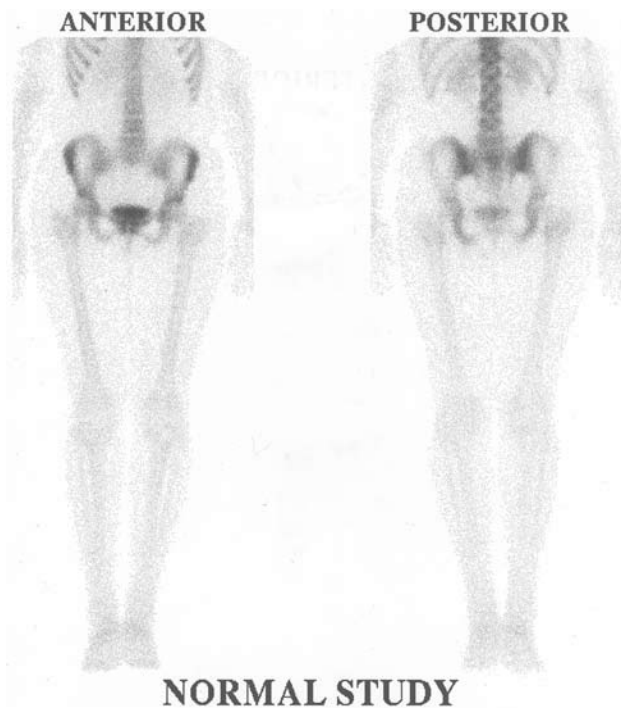- Patient preparation: no special preparation is necessary
- Radiopharmaceutical administration
  - Agent: Tc-99m-MDP
  - Dosage: 20 to 30 mCi, depending on body weight
  - Route: intravenous
- Image acquisition
  - Camera: large field of view with SPECT

- capability
- Collimator: low energy, high resolution
- Energy: 20% centered on 140 keV
- Positioning: images acquired with patient supine
- Type of acquisition
  - Whole body mode acquisition, anterior and posterior views, pelvis and below
  - Extended upward for symptoms above pelvis
  - Spot images of feet in all patients
  - Spot images of lateral knees if positive lesions seen
  - Other spot images as needed
  - SPECT images of pelvis for possible femoral neck stress fractures

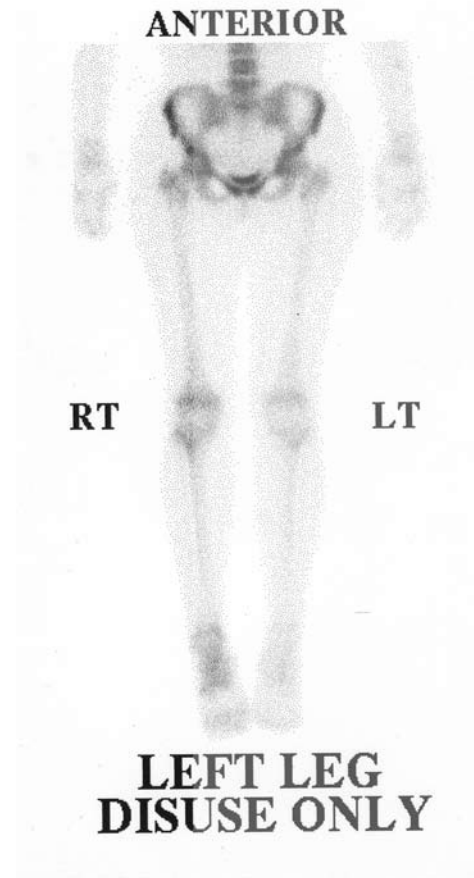
## Figures



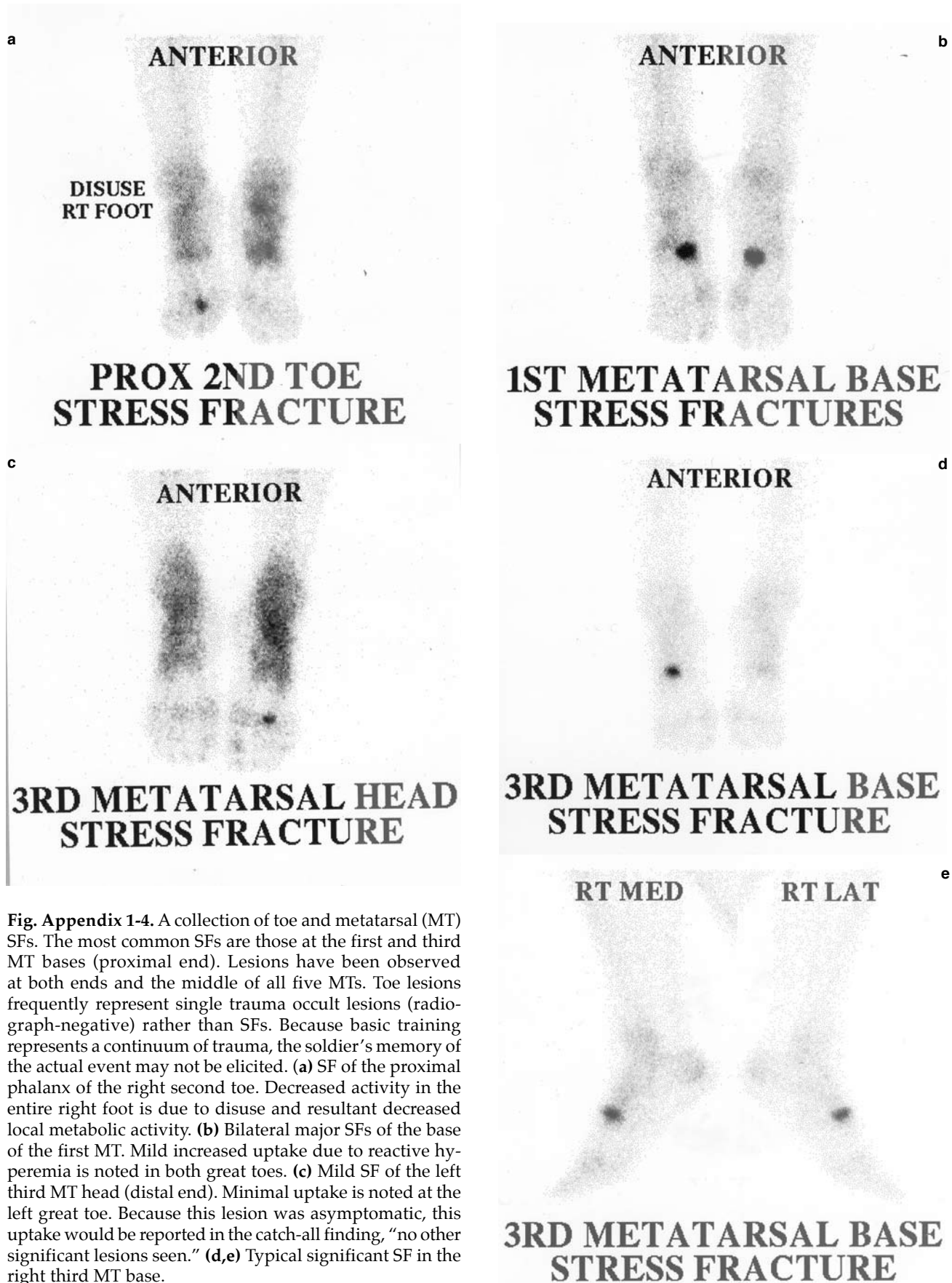
**Fig. Appendix 1-1.** A 19-year-old female trainee presented with bilateral tibial pain and significant pitting edema of both lower legs. The bone scan (a) reveals a major stress fracture (SF) of the left mid tibia and a significant SF of the right proximal tibia. The accompanying right tibial radiograph (b) is normal.

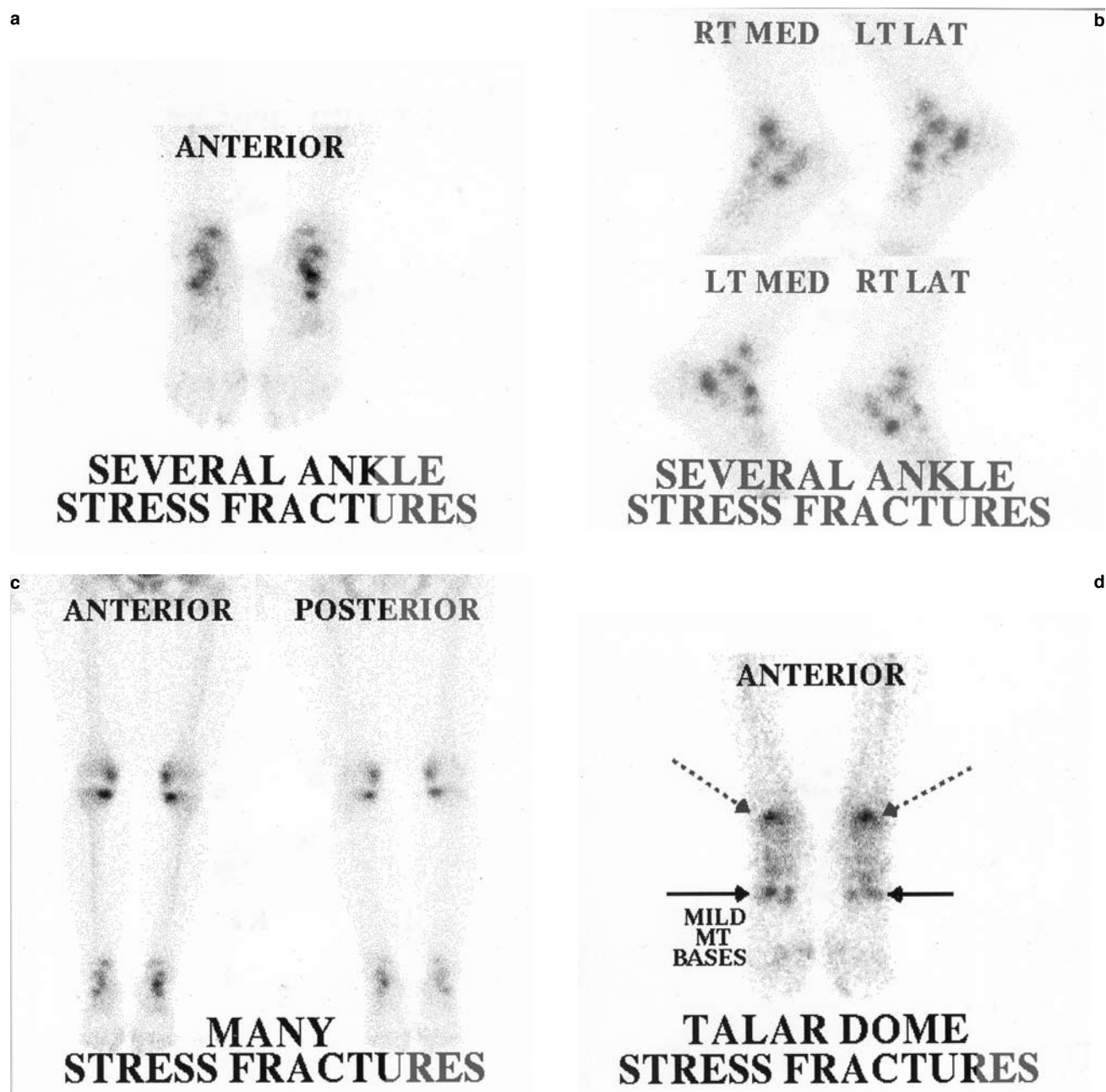


**Fig. Appendix 1-2.** A normal study from the twelfth thoracic vertebra and below in a 19-year-old female trainee complaining of insidious onset of bilateral knee pain of 3 weeks duration. The trainee was returned to duty and did not return to the medical treatment facility.



**Fig. Appendix 1-3.** This 20-year-old female recruit in her second week of basic training presented with pain in her left femoral triangle, the left medial tibial plateau, and the left distal femur. The image is normal except for the significantly decreased uptake (of the radiopharmaceutical agent) in the entire left leg. This finding is compatible with disuse and suggests that the pain is real, probably located in the soft tissue. Within a week after a patient begins to splint from pain, the pattern of disuse may appear. Malingerers are not able to splint sufficiently to cause the pattern of disuse.

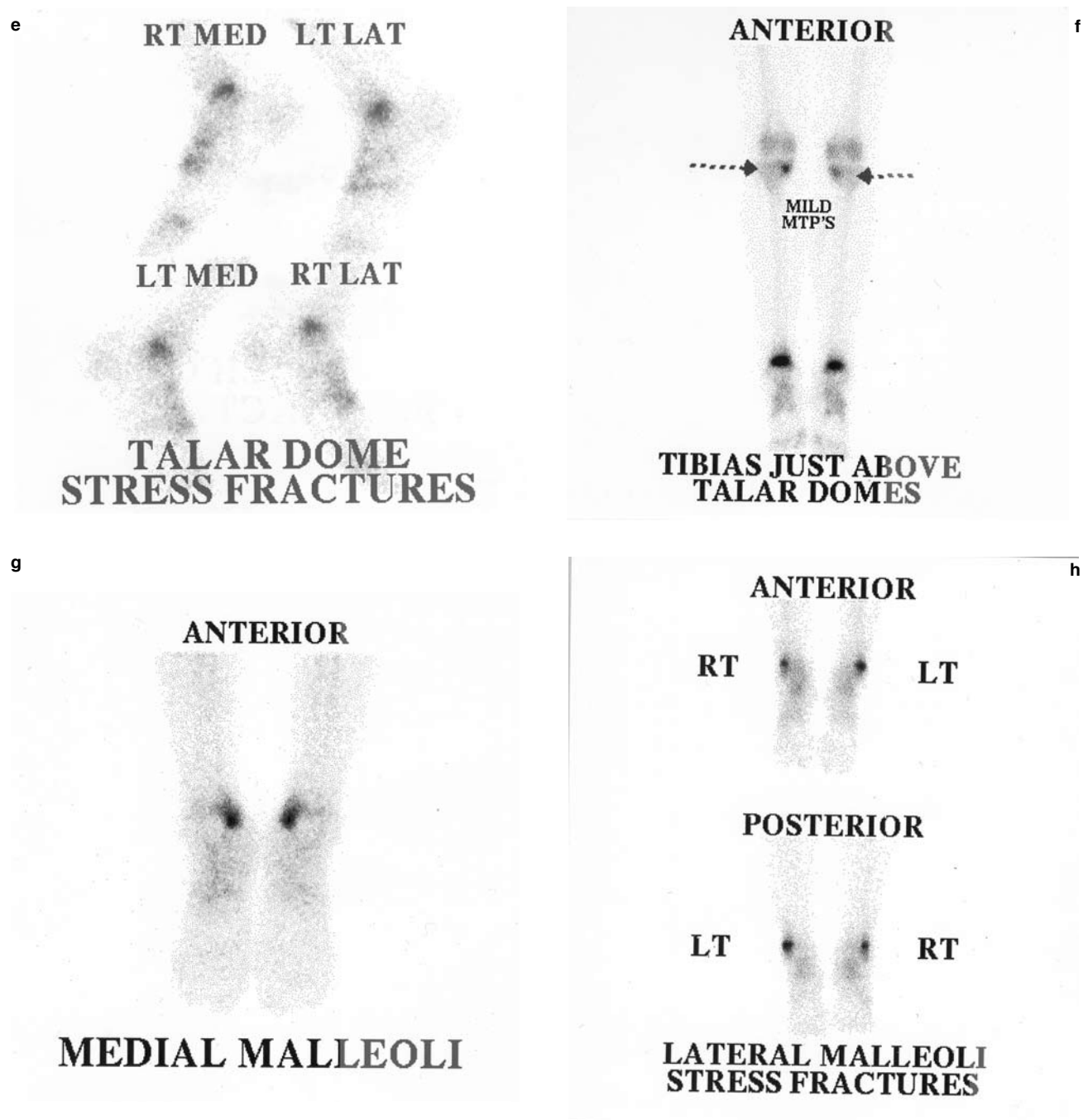




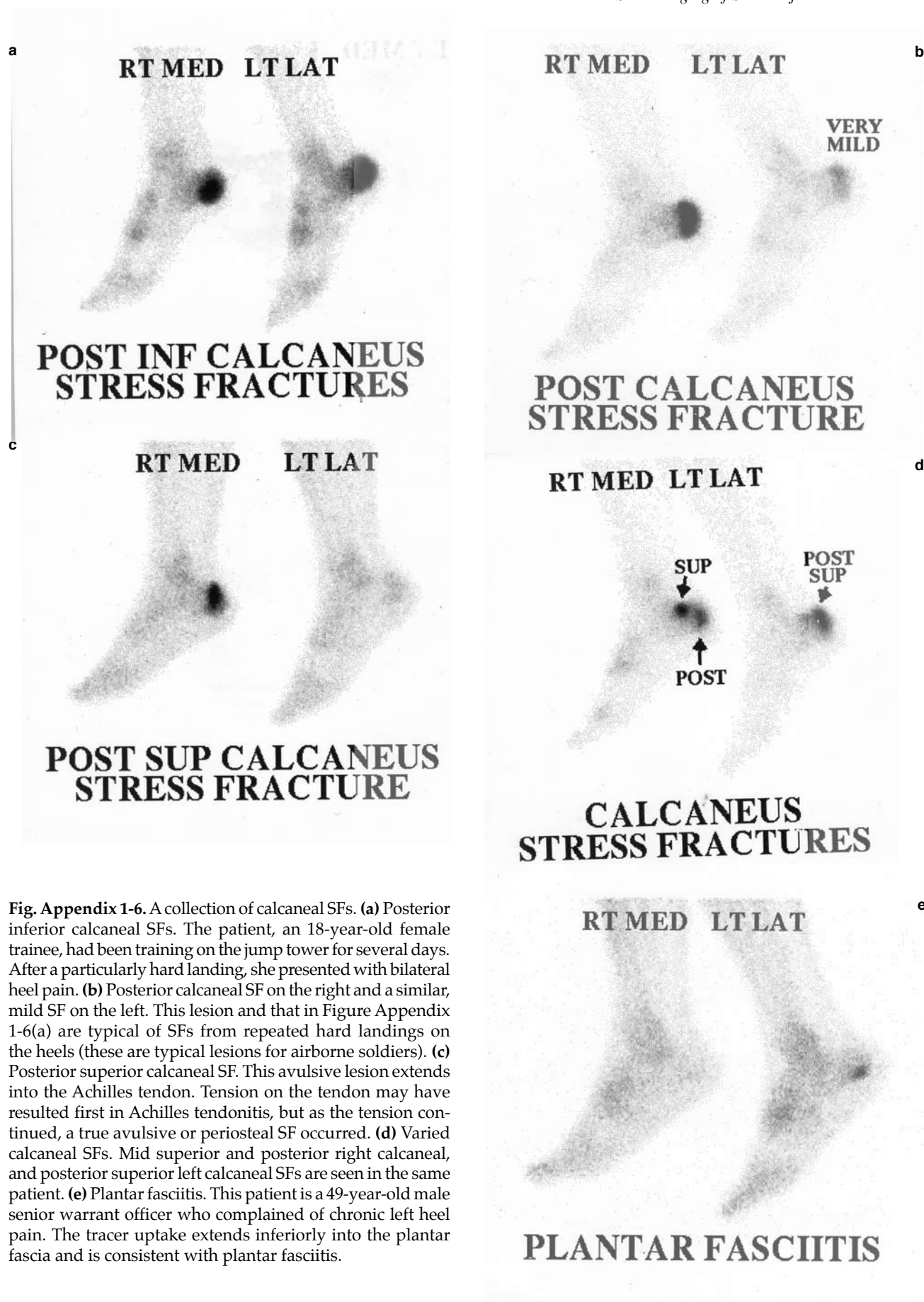
**Fig. Appendix 1-5.** A collection of ankle (tarsal and malleolar) SFs. **(a,b,c)** A 19-year-old female trainee with bilateral knee pain presented. In addition to the bilateral medial tibial plateau and adjacent medial femoral condylar SFs, the patient had at least four SFs in each ankle. It is not unusual for patients to present with initial SFs as well as lesions that have developed subsequently. The patient may have been training awkwardly for 2 weeks or more before arriving at the medical facility, allowing time for the newer lesions to appear (for this reason, all patients are imaged from the pelvis down). **(d,e)** Significant talar dome SFs. In addition to the significant SFs, several minor lesions are noted in both forefeet (at the MT bases in particular). **(f)** Tibial plafond SFs. The lesions are just above the talar domes and caused by impact of the domes into the overlying tibia. **(g)** Major bilateral medial malleolar SFs. **(h)** Lateral malleolar SFs.

(Figure Appendix 1-5 continues)

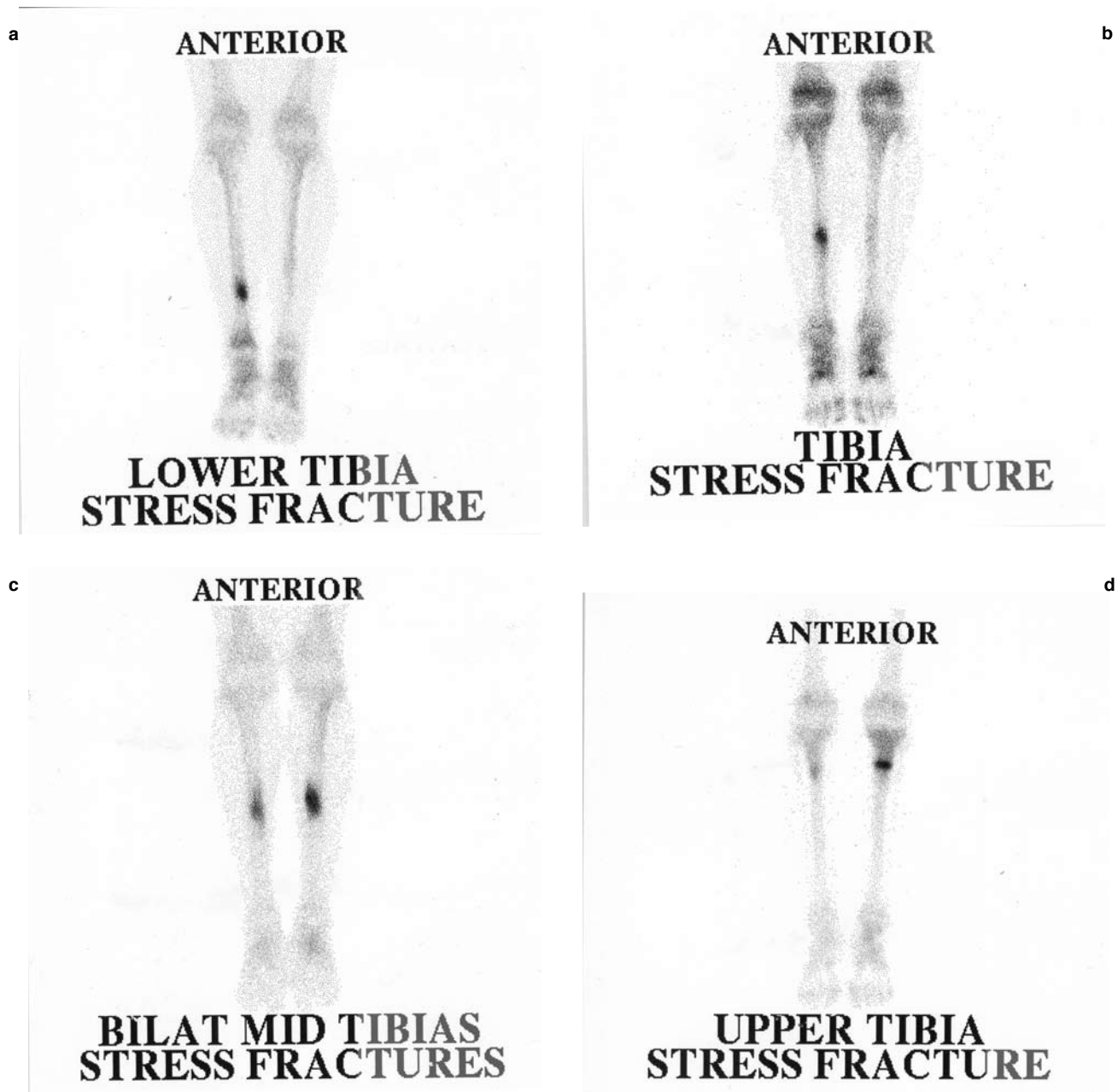
Figure Appendix 1-5 *continued*







**Fig. Appendix 1-6.** A collection of calcaneal SFs. **(a)** Posterior inferior calcaneal SFs. The patient, an 18-year-old female trainee, had been training on the jump tower for several days. After a particularly hard landing, she presented with bilateral heel pain. **(b)** Posterior calcaneal SF on the right and a similar, mild SF on the left. This lesion and that in Figure Appendix 1-6(a) are typical of SFs from repeated hard landings on the heels (these are typical lesions for airborne soldiers). **(c)** Posterior superior calcaneal SF. This avulsive lesion extends into the Achilles tendon. Tension on the tendon may have resulted first in Achilles tendonitis, but as the tension continued, a true avulsive or periosteal SF occurred. **(d)** Varied calcaneal SFs. Mid superior and posterior right calcaneal, and posterior superior left calcaneal SFs are seen in the same patient. **(e)** Plantar fasciitis. This patient is a 49-year-old male senior warrant officer who complained of chronic left heel pain. The tracer uptake extends inferiorly into the plantar fascia and is consistent with plantar fasciitis.

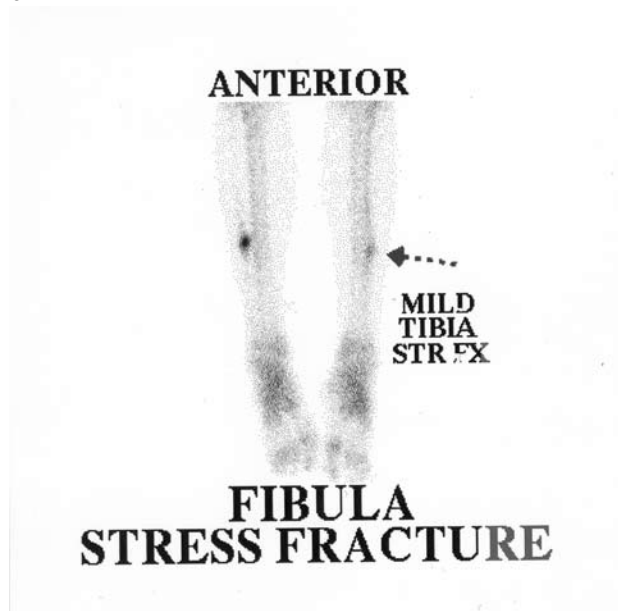


**Fig. Appendix 1-7.** A collection of common lower leg lesions. The tibia, a major weight-bearing bone, is the site of a significant number of stress injuries. (a) A significant SF at the distal third medial tibia. (b) A major SF at the mid tibia. (c) Bilateral major SFs at the mid tibia. (d) Major SF at the upper left tibia. A minor lesion is also noted at the right tibia, same site. (e) Significant SF of the right mid fibula. This is an unusual finding. In the trainee population, most of the fibular SFs occur at the lateral malleolus or just above. A minor SF at the lateral mid tibia is also seen. (f) Myonecrosis. This patient was an 18-year-old female in the seventh week of basic training. She presented with a history of bilateral mid tibial pain, and, after a negative radiograph, proceeded to bone scanning. No bony lesions are seen, but there is significant uptake in the anterior compartment muscles adjacent to both tibias. The patient had an elevated creatine phosphokinase (muscle enzyme). This is a classic study demonstrating myonecrosis, and in this patient there is no evidence of SF. This type of lesion occurs most commonly during training in the hotter months and can usually be avoided by maintaining adequate hydration.

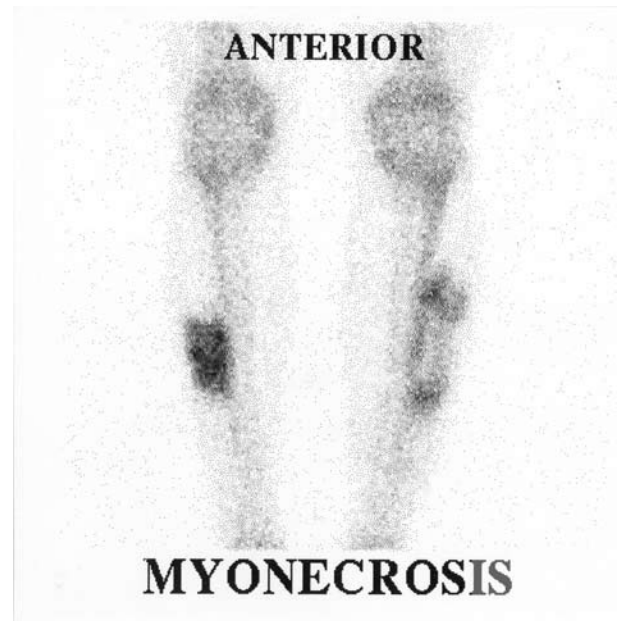
(Figure Appendix 1-7 continues)

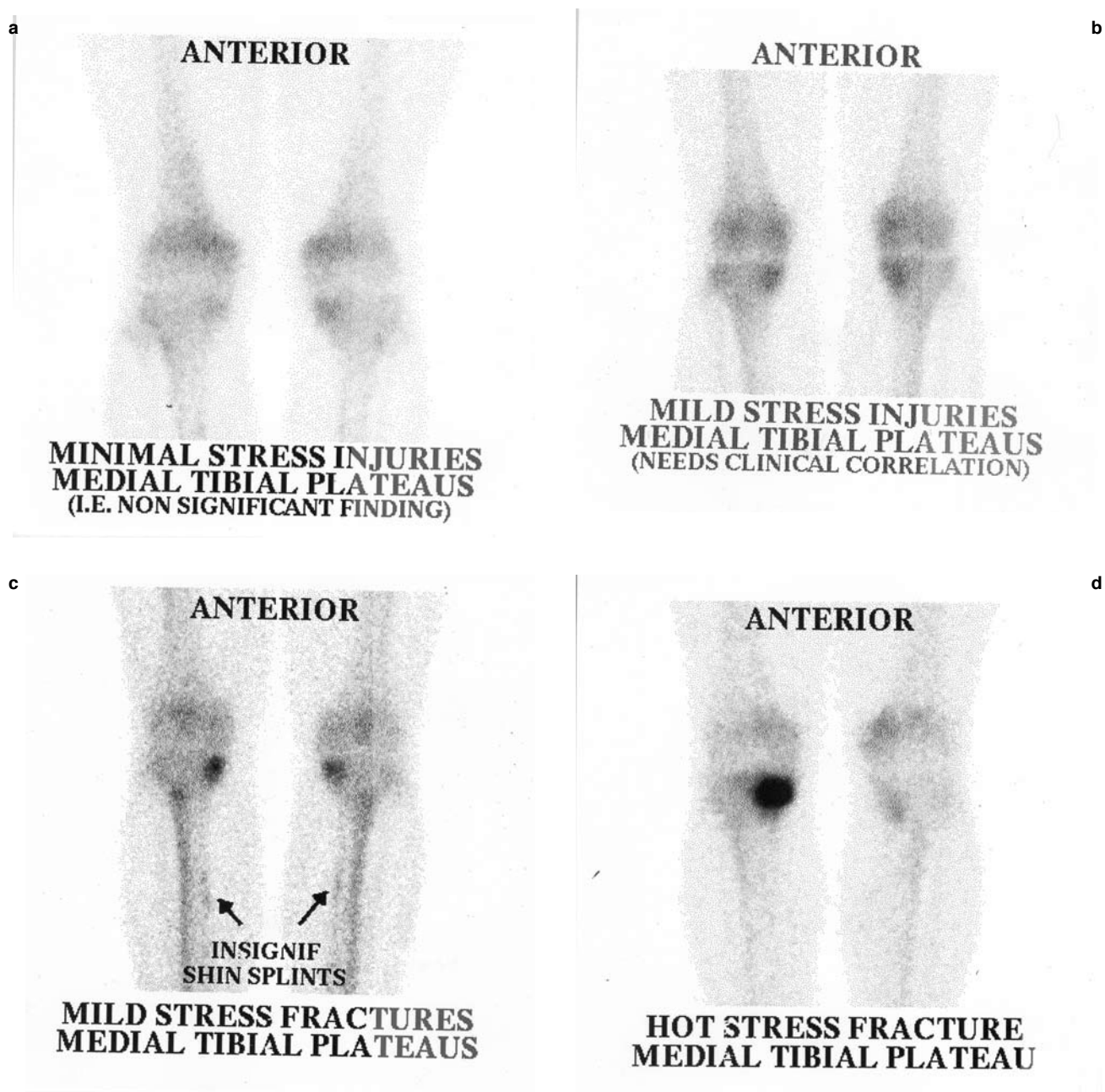
Figure Appendix 1-7 *continued*

e



f

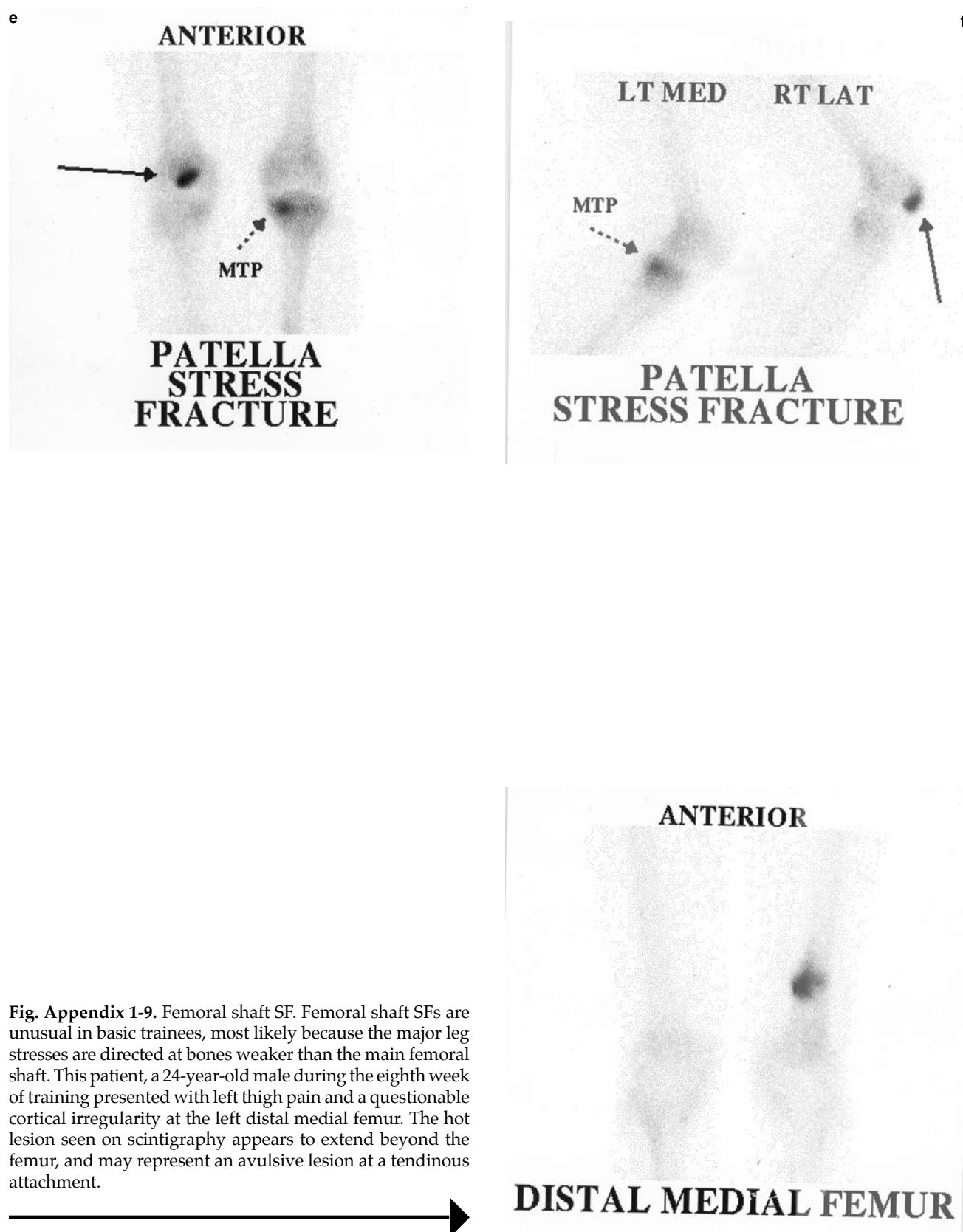




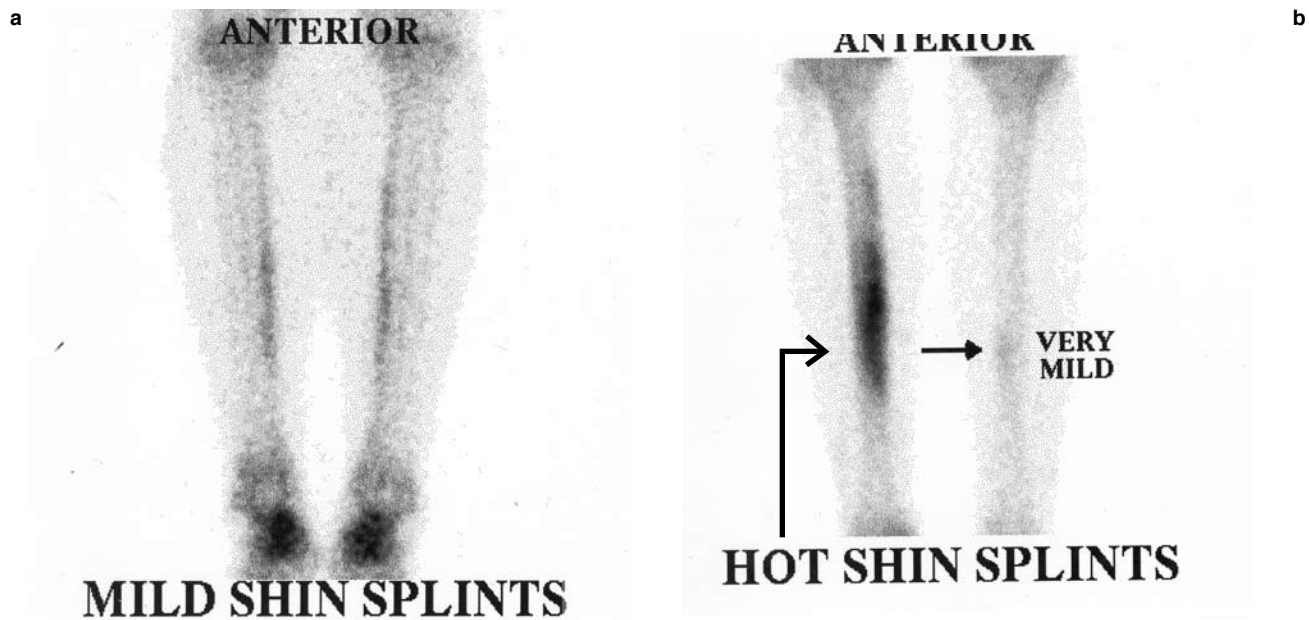
**Fig. Appendix 1-8.** A collection of knee lesions. **(a)** Mild overuse uptake at the medial knees. This finding is seen more often in trainees than are completely normal knees. It is usually not associated with symptoms, and is usually reported as “no other significant lesions seen.” **(b)** Overuse uptake. In the trainee population, this finding is even more common than that in Fig. 8(a) and normal combined. If there is no reference to knee pain, this finding is usually reported as “clinical correlation is recommended to determine if further action is required.” If knee pain is being evaluated, then this finding will be reported as compatible with mild stress injury and/or soft tissue injury. **(c)** Mild bilateral medial tibial SFs. Most trainees have some focal uptake at the medial tibial plateaus. If knee pain is being evaluated, these findings will be reported as mild SFs. If there is no knee pain, the findings will be reported as “clinical correlation needed.” **(d)** Major SF at the right medial tibial plateau. Insignificant uptake (for trainees) is seen at the left medial knee. **(e,f)** A 25-year-old female trainee presented with bilateral lower extremity pain of 2 weeks’ duration. The hot lesion at the inferior right patella may have begun as patellar tendonitis, which has developed into a full-blown avulsive or periosteal SF. Although there is a mild left medial tibial plateau SF, disuse on the right suggests that the patellar lesion is the primary one. The medial tibial plateau is the second most common site for trainee SFs, after all MT sites combined.

(Figure Appendix 1-8 continues)

Figure Appendix 1-8 *continued*

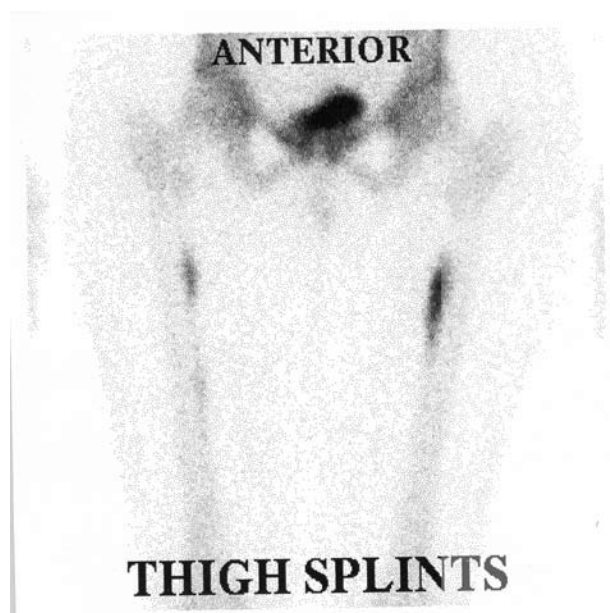


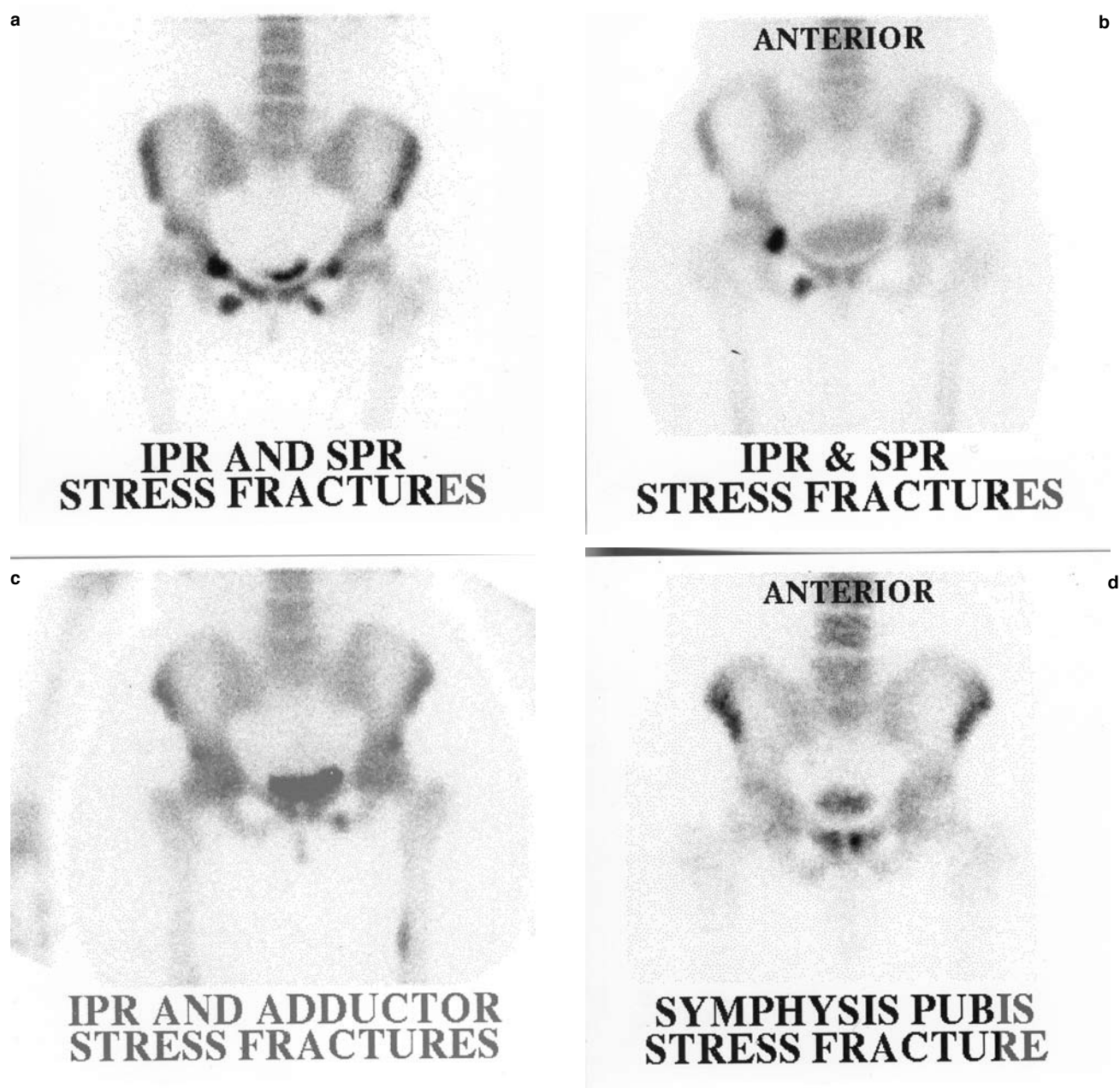
**Fig. Appendix 1-9.** Femoral shaft SF. Femoral shaft SFs are unusual in basic trainees, most likely because the major leg stresses are directed at bones weaker than the main femoral shaft. This patient, a 24-year-old male during the eighth week of training presented with left thigh pain and a questionable cortical irregularity at the left distal medial femur. The hot lesion seen on scintigraphy appears to extend beyond the femur, and may represent an avulsive lesion at a tendinous attachment.



**Fig. Appendix 1-10.** Several patients with shin splints. Shin pain is a common complaint among athletes and recruit trainees. In the past, “shin splints” was used to describe any pain along the medial tibial border experienced by runners. This pain syndrome can be divided into SF, compartment syndrome, and shin splints. Scintigraphically, SF images reveal focal lesions in the tibia. Anterior and posterior muscle compartment syndrome, which is due to muscle swelling in a fixed-sized muscle compartment, are generally scintigraphically negative. Shin splints, which represents periosteal inflammation at the aponeurotic insertion of muscle, particularly the tibial posterior and soleus muscles, to the fascia at the medial border of the tibia, is seen as linear uptake along the posteromedial tibia. Shin splints represents an enthesopathy where the the ligamentous attachment to the compartment muscles of the tibia may be partly or mildly avulsed. There can be significant overlap in the conditions, such as shin splints with SFs (linear and focal lesions together) or severe chronic compartment syndrome with periosteal involvement. **(a)** Moderate shin splints along both medial tibias. **(b)** Severe shin splints at the right mid medial tibia. Very mild shin splints is noted at the left mid medial tibia.

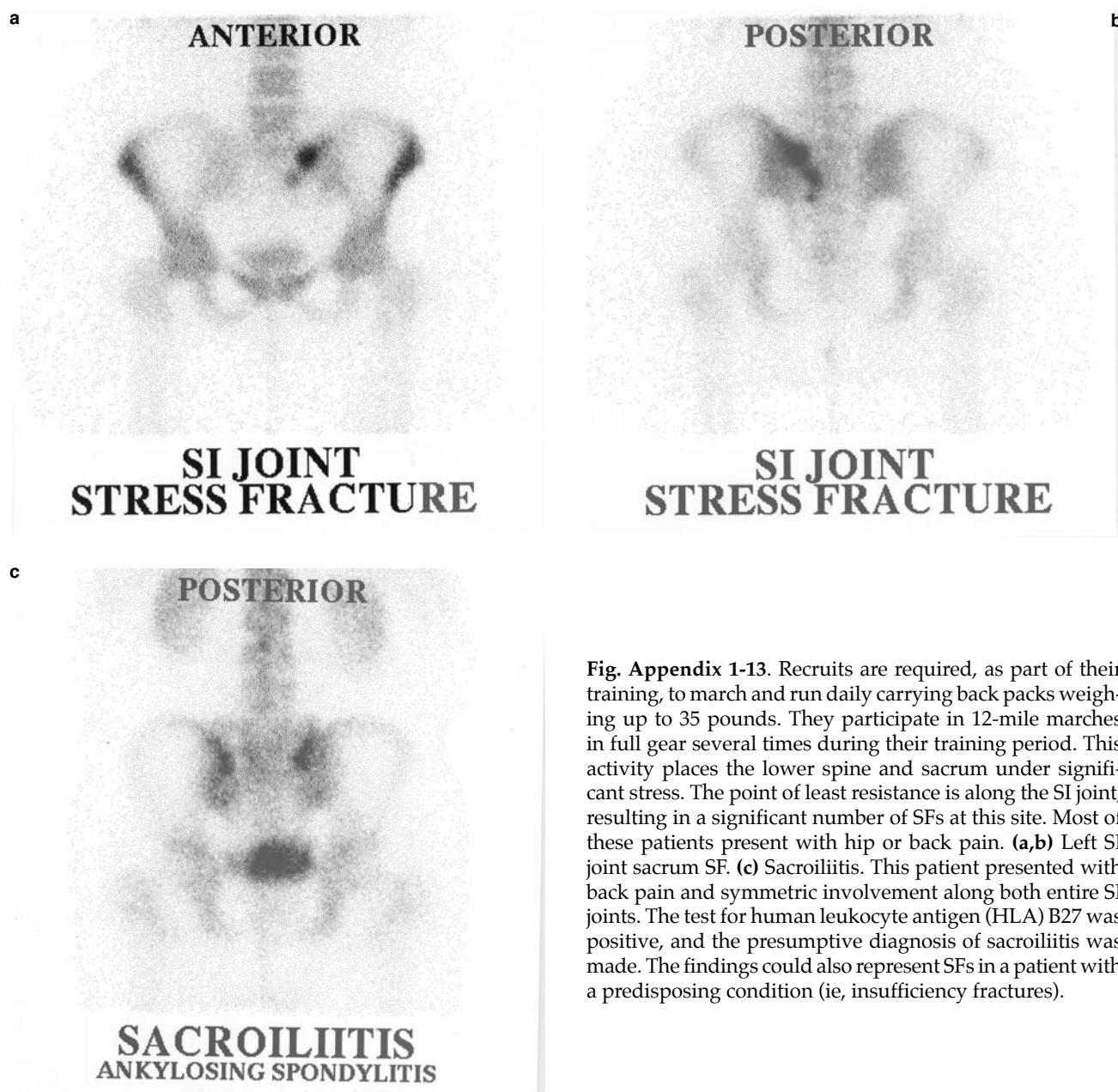
**Fig. Appendix 1-11.** Thigh splints. The development of thigh splints is similar to that of shin splints, representing periosteal inflammation seen as linear uptake along the medial tibia. Thigh splints may develop as an avulsive lesion. The most common site for thigh splints is at or near the adductor insertion into the proximal tibia; thigh splints and SFs are common occurrences at this location. In this case, the uptake is linear, suggesting splints rather than SF, but the differentiation between the two diagnoses may be subtle. Thigh splints (enthesopathy) are seen at both adductor insertions, with uptake greater on the left than on the right.





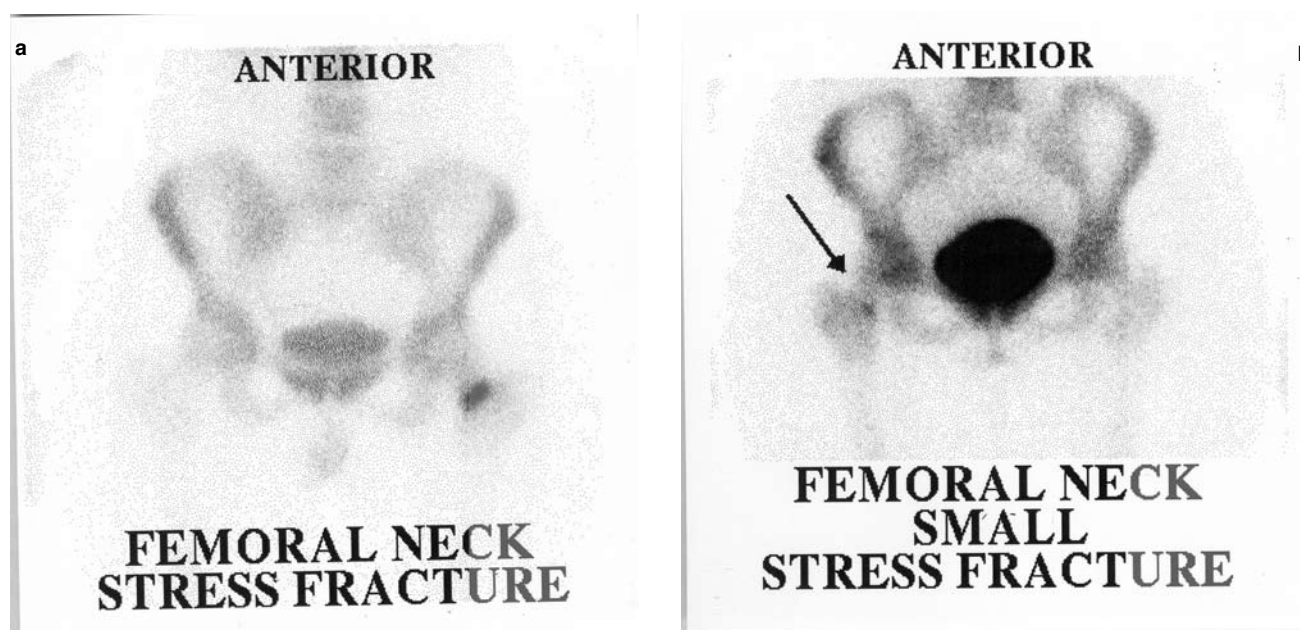
**Fig. Appendix 1-12.** A collection of lesions involving the pubic rami. During a 12-year period at Fort Jackson, at least 2,000 patients with pubic ramus SFs were imaged. About 90 percent of these patients were female. The most frequent lesion seen in the females was the inferior pubic ramus (IPR) SF with or without associated femoral adductor insertion SF or splints. Superior pubic ramus (SPR) SFs are often seen associated with IPR lesions, but are rarely seen alone. A possible reason for this unique finding in women is that all troops must march and run in formation with the same sized stride (women and men together). Although the stride is comfortable for most males and taller females, it is a “stretch” for most females. This can result in tensioning of the adductor muscles at both ends (ie, the IPR, SPR, and adductor insertion into the femur), resulting in stress injuries at these sites. If all personnel stretched their adductors adequately before each exercise session, troop marches, and runs in formation, many of these lesions might be avoided. **(a)** Bilateral significant IPR and SPR SFs. **(b)** Severe right IPR and SPR SFs. **(c)** Significant left IPR SF and adductor SF. The adductor lesion could represent SF or enthesopathy (splints). The paired lesions are not unusual in trainees. **(d)** Moderate bilateral symphysis pubis SFs.



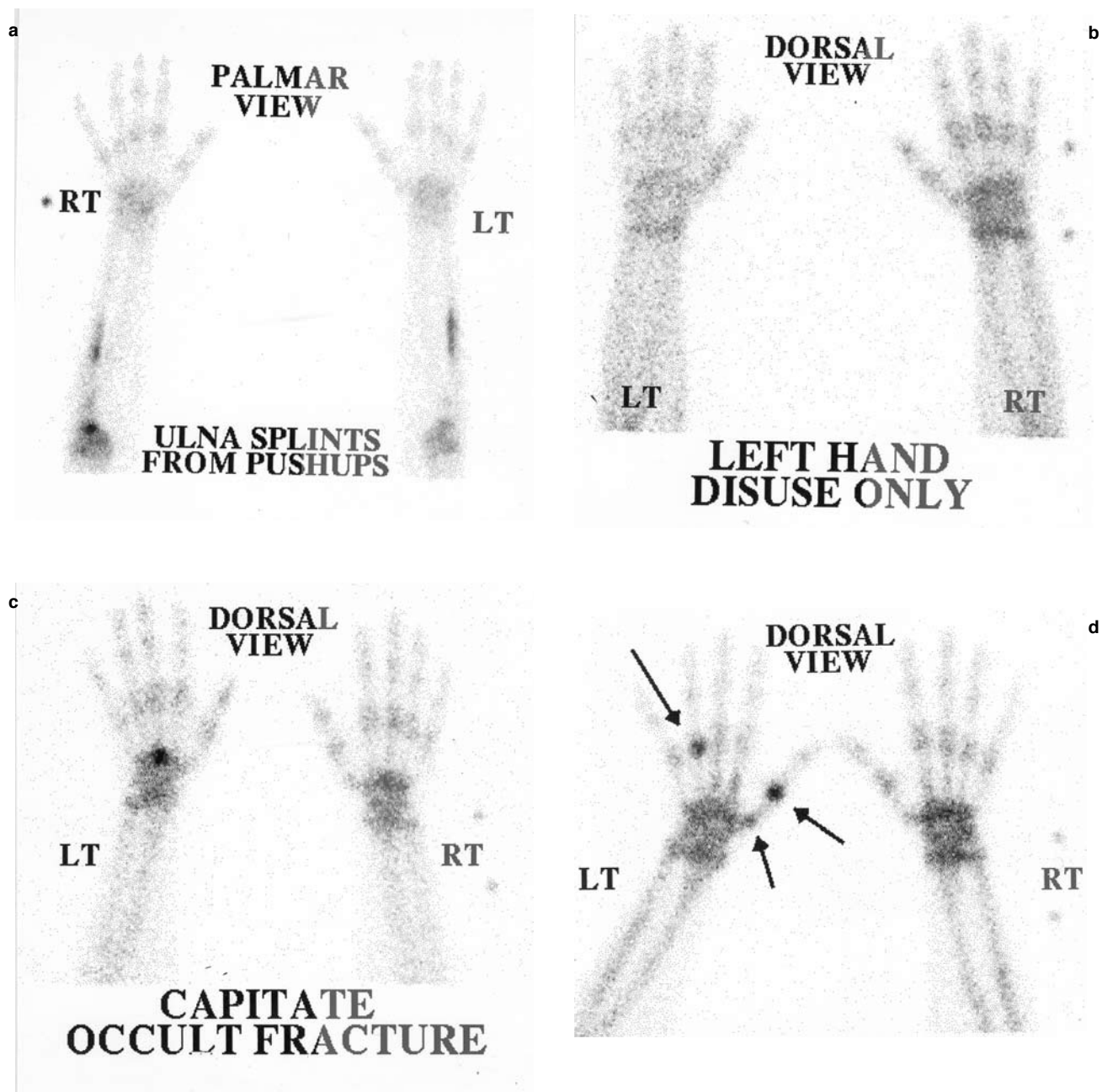


**Fig. Appendix 1-13.** Recruits are required, as part of their training, to march and run daily carrying back packs weighing up to 35 pounds. They participate in 12-mile marches in full gear several times during their training period. This activity places the lower spine and sacrum under significant stress. The point of least resistance is along the SI joint, resulting in a significant number of SFs at this site. Most of these patients present with hip or back pain. **(a,b)** Left SI joint sacrum SF. **(c)** Sacroiliitis. This patient presented with back pain and symmetric involvement along both entire SI joints. The test for human leukocyte antigen (HLA) B27 was positive, and the presumptive diagnosis of sacroiliitis was made. The findings could also represent SFs in a patient with a predisposing condition (ie, insufficiency fractures).





**Fig. Appendix 1-14.** Femoral neck SFs. **(a)** Severe left femoral neck SF extending from the compression side (inferomedially) to the tension side (superolaterally) and appearing hotter on the tension side. Because of the increased stress, the tension-side SF is more likely to proceed to actual fracture, frequently requiring surgery. **(b)** Small right femoral neck SF, compression side. The lesion is very small. The percentage of the width of the femoral neck involved may be used to determine if surgery is needed to treat a femoral neck SF. MRI may be useful in this instance to more accurately size the lesion. It is important, however, to read even such a small SF as positive. A femoral neck SF of any size or intensity must be protected immediately to prevent progression to actual fracture. Unless the radiographs are positive, any patient with hip pain must be imaged scintigraphically. However, all patients in the first 4 weeks of training should have immediate bone scans, rather than delaying diagnosis to wait for radiograph results.



**Fig. Appendix 1-15.** Several upper extremity lesions. **(a)** Ulnar splints. A 23-year-old female who presented with lower extremity SFs admitted to pain while performing pushups. **(b)** Disuse of left hand. A 19-year-old male fell on his left outstretched hand during unarmed combat training. No occult fracture is seen; however, disuse of the left hand is noted. **(c)** Capitate fracture of left hand. An 18-year-old female presented with right hip pain; bone imaging showed a right adductor insertion SF. She also noted that she had fallen on outstretched hands 3 months earlier. The images reveal an occult fracture of the left capitate. **(d)** Left wrist fractures. A 19-year-old male presented with left hip pain; bone imaging showed a left IPR SF. He reported jamming his left hand during pugel stick combat training. Images reveal occult fractures at the left first and fourth metacarpal heads and the left first metacarpal base.

## RECOMMENDED READING

1. Maitra RS, Johnson DL. Stress fractures: Clinical history and physical examination. *Clin Sports Med.* 1997;16: 259–274.
2. Deutsch AL, Coel MN, Mink JH. Imaging of stress injuries to bone: Radiography, scintigraphy, and MR imaging. *Clin Sports Med.* 1997;16: 275–290.
3. Ekenman I. Physical diagnosis of stress fracture. In: Burr DB, Milgrom C, eds. *Musculoskeletal Fatigue and Stress Fractures (CRC Series in Exercise Physiology)*. Boca Raton, Fla: CRC Press; 2001:71–278.
4. Chisin R. The role of various imaging modalities in diagnosing stress fractures. In: Burr DB, Milgrom C, eds. *Musculoskeletal Fatigue and Stress Fractures (CRC Series in Exercise Physiology)*. Boca Raton, Fla: CRC Press; 2001:279–293.
5. Bohndorf K, Imhof H, Pope TL, eds. *Musculoskeletal Imaging: A Concise Multimodality Approach*. Stuttgart, Germany: Thieme; 2001.
6. Spitz DJ, Newberg AH. Imaging of stress fractures in the athlete. *Radiol Clin North Am.* 2002;40: 313–331.
7. Brukner P, Bennell K, Matheson G. Diagnosis of stress fractures. In: *Stress Fractures*. Victoria, Australia: Blackwell Science Asia; 1999:83–96.
8. Ishibashi Y, Okamura Y, Otsuka H, Nishizawa K, Sasaki T, Toh S. Comparison of scintigraphy and magnetic resonance imaging for stress injuries of bone. *Clin J Sports Med.* 2002;12:79–84.
9. Shin AY, Morin WD, Gorman JD, Jones SB, Lapinsky AS. The superiority of magnetic imaging in differentiating the cause of hip pain in endurance athletes. *Am J Sports Med.* 1996;24:168–176.
10. Dutton J, Bromhead SE, Speed CA, Menzies AR, Peters AM. Clinical value of grading the scintigraphic appearances of tibial stress fractures in military recruits. *Clin Nucl Med.* 2002;27:18–21.
11. Kiuru MJ, Pihlajamaki HK, Hietanen HJ, Ahovuo JA. MR imaging, bone scintigraphy, and radiography in bone stress injuries of the pelvis and lower extremity. *Acta Radiol.* 2002;43:207–212.

